



## Full Length Research Article

### THE KERATOACANTHOMA (KA) SKIN LESIONS IN TWO ZAMBIAN MEN:

<sup>1</sup>Duncan D Mugala and <sup>2,\*</sup>Mayaba Maimbo

<sup>1</sup>Senior Lecturer Copper Belt University-School of Medicine, Senior Consultant Surgeon Ndola Central Hospital, Honorary Lecturer University of Zambia School of Medicine-Lusaka

<sup>2</sup>Ndola Teaching Hospital 6th Eastwing Po Box 21629 Ndola

#### ARTICLE INFO

##### Article History:

Received 02<sup>nd</sup> March, 2017  
Received in revised form  
14<sup>th</sup> April, 2017  
Accepted 07<sup>th</sup> May, 2017  
Published online 16<sup>th</sup> June, 2017

##### Key Words:

Keratoacanthoma (KA),  
SCC (Squamous Cell Carcinoma),  
Giant (KA),  
HPV (Human papilloma virus),  
Aggressive.

#### ABSTRACT

Keratoacanthoma (KA) is a low-grade skin tumor that originates in the pilosebaceous glands. Clinically, KA lesions cannot be easily differentiated from a more serious skin cancer similar to Squamous Cell Carcinoma (SCC). (Keratoacanthoma, 2004) The tumor usually begins in the skin's pilosebaceous glands, or hair follicles and grows quickly over the first few weeks but do not spread to other parts of the body. If left alone, the lesions will usually disappear by themselves in 4 to 6 months. This condition usually occurs in older individuals. The precise cause is not known but like squamous cell carcinoma, it seems that ultraviolet light from the sun causes the development of KA (Schwartz, 2004). Sporadic cases have been found co-infected with the Human Papilloma Virus (HPV) (Niebuhr, 2009). It is also believed that other factors may play a part, including heavy exposure to the sun, contact with some chemicals, smoking, suppressed immune system, and minor injuries to the skin. The generalized eruptive keratoacanthoma (also known as "Generalized eruptive keratoacanthoma of Grzybowski") is a cutaneous condition; a variant of keratoacanthomas characterized by hundreds to thousand us of tiny follicular keratotic papules over the entire body. Treatments and cure are not usually successful for many patients with Generalized eruptive keratoacanthoma. Use of emollients and anti-itch medications can ease some symptoms. Improvement or complete resolution of this condition are not usually reached. Many new treatments of Melanoma are also known to increase the rate of Keratoacanthoma, such as the B-Raf inhibitor drugs Vemurafenib and Dabrafenib (Niezgoda et al., 2015). Keywords : Keratoacanthoma (KA), SCC (Squamous Cell Carcinoma), Giant (KA), HPV (Human papilloma virus), Aggressive.

Copyright© 2017, Duncan D Mugala and Mayaba Maimbo. This is an open access article distributed under the Creative Commons Attribution License, which permits unrestricted use, distribution, and reproduction in any medium, provided the original work is properly cited.

#### INTRODUCTION

Keratoacanthoma usually occurs in older individuals. As with squamous cell cancer, it seems likely that ultraviolet light from the sun causes the development of KA (Schwartz, 2004). As with squamous cell cancer, sporadic cases have been found co-infected with the human papilloma virus (HPV) (Niebuhr, 2009). Many new treatments for Melanoma are also known to increase the rate of Keratoacanthoma, such as the B-Raf inhibitor drugs Vemurafenib and Dabrafenib (Niezgoda, 2015). Keratoacanthomas (molluscum sebaceum) may be divided into the following types (Freedberg, 2003; James et al., 2005):

- Giant keratoacanthomas. A variant of keratoacanthoma, which may reach dimensions of several centimeters (Freedberg, 2003).

- Keratoacanthoma centrifugum marginatum. A variant of keratoacanthomas, which is characterized by multiple tumors growing in a localized area (Freedberg, 2003);
- Multiple keratoacanthomas (also known as "Ferguson-Smith syndrome", "Ferguson-Smith type of multiple self-healing keratoacanthomas"). It is a coetaneous condition; a variant of keratoacanthomas which is characterized by the appearance of multiple, sometimes hundreds of keratoacanthomas (Freedberg, 2003; James et al., 2005).
- A solitary keratoacanthoma (also known as "Subungual keratoacanthoma"). Is a benign but rapidly growing, locally aggressive tumor which sometimes occur in the nail apparatus (Freedberg, 2003; James et al., 2005)

#### Pathophysiology

Trauma, ultraviolet light, chemical carcinogens, human papilloma virus, genetic factors, and immunocompromised status have been known to lead to this illness. It is Known that the use of BRAF inhibitor therapy for melanoma and the

**Corresponding author: Dr. Duncan D Mugala,**  
Ndola Teaching Hospital 6th Eastwing Po Box 21629 Ndola.

inhibitor therapy for advanced basal cell carcinoma have elicited a surgical involvement in keratoacanthoma (KA) incidence (Schwartz, 2004). Keratoacanthoma and conventional SCC have very similar epidemiological features. This suggests a possible common pathogenesis (Niezgoda et al., 2015). In some studies in USA, it was seen that most keratoacanthomas and SCCs were seen to developed on head/neck and limbs (keratoacanthoma, 78%; SCC, 85%) (Niebuhr, 2009; Niezgoda et al., 2015). The American studies also showed that the incidence of keratoacanthoma and SCC are seen mainly in patients after age 64 years. (The average age of patients was 67 years in keratoacanthoma and 66 years in SCC.) Male-to-female ratios for both conditions were similar, at 2:1 (Niebuhr, 2009).

## The Cases Presentation

### Case 1

Our first patient was a 56 years old male who at the time of presentation was about to retire from the mines. He presented with a rash on his entire face. He also had ulceration on his left gluteum. The anal cleft was clear. The illness was of long duration. He had a rash on his body which was itchy and sometimes weepy. His skin was particularly dark.

### Examination

On his left gluteum, he had an ulcerated lesion that was undermining and raising the margin of the ulcer. The cleft area was clear. The wound had a foul smelling discharge. It was however, not painful. The facial skin and gluteal skin looked dimpled. Although clinically HIV infection was suspected, the patient declined to undergo the Test.

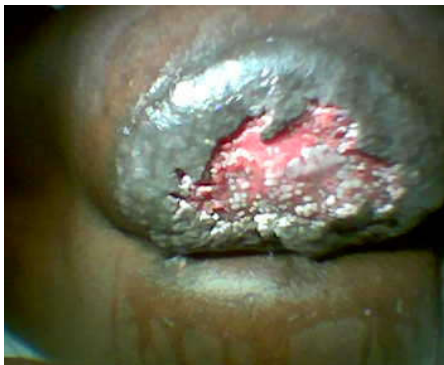

Figure 2. KA underlying the gluteal skin

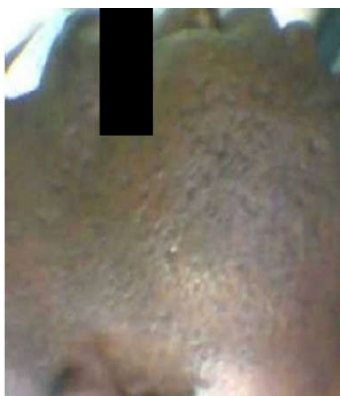

Figure 3. Dimpling KA of face

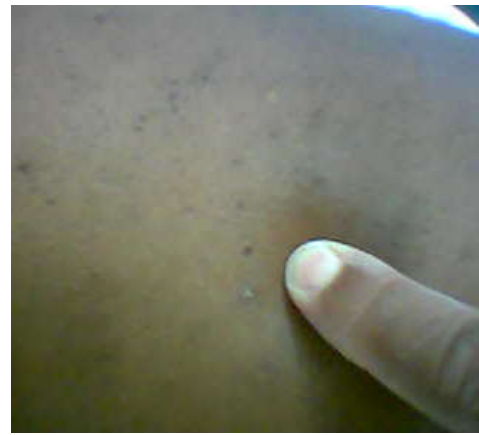

Figure 4. Dimpling KA on the body

### Case 2

This was a 48 years old male. He was a known HIV positive patient on HART for years. Along the way, the patient stopped taking his HART medication. He then presented himself at the local clinic with what was diagnosed to be an axillary abscesses. However, after Incision and drainage and antibiotics, the abscesses persisted. They began to increase in size and spread all over the body. The lesions were said to be painless, unlike the common cases of abscesses. They were described to be itchy and weepy most of the time. Of note was that the patient did not remember the onset of the lesions on the face. On examination: the patient was otherwise in a good general condition. He had typical facies described above and skin lesions as shown in the picture.

### Our second Patient physical appearance

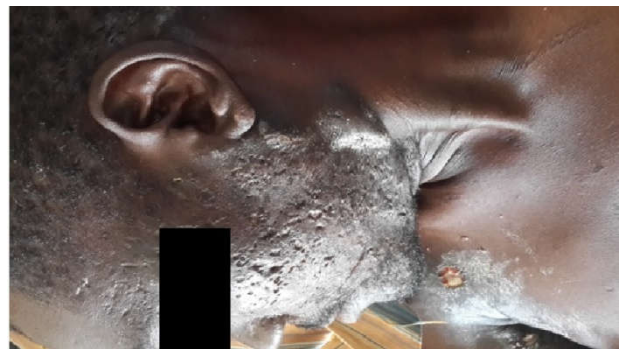


Figure 5. Case 2 KA Lesions on Face

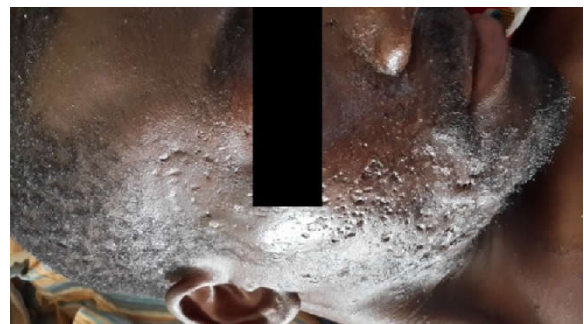

Figure 6. Case 2 KA Lesions on Face

### European man with KA

The features on the Zambian patient men and the European skin appearances are very similar.



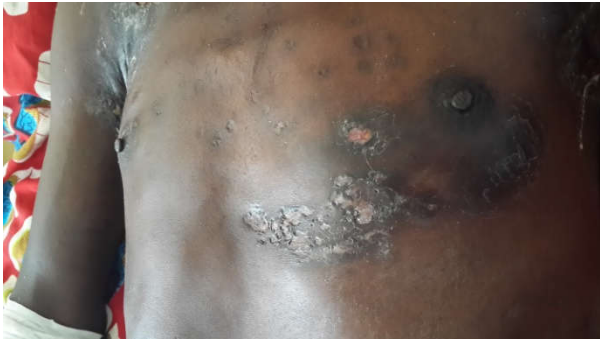

Figure 7. Case 2 KA Lesions on chest

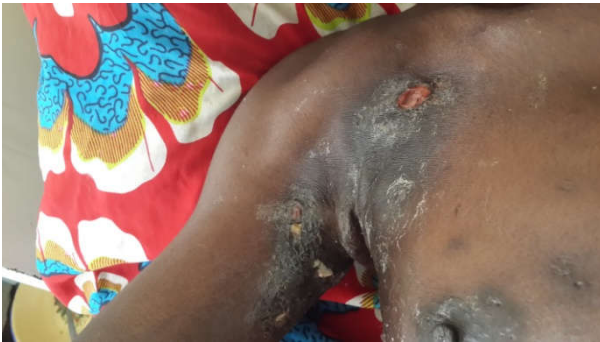

Figure 8. Case 2 KA Lesions in Rt axilla

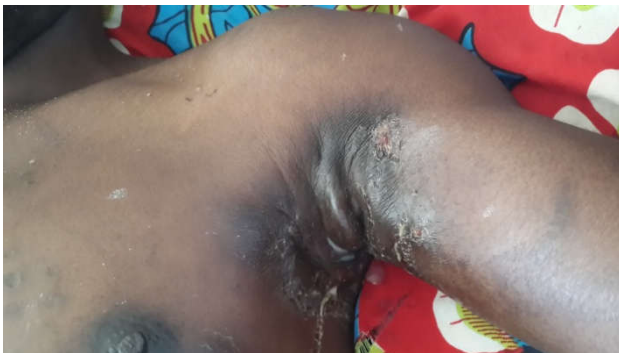

Figure 9. Case 2 KA Lesions in the Lt axilla

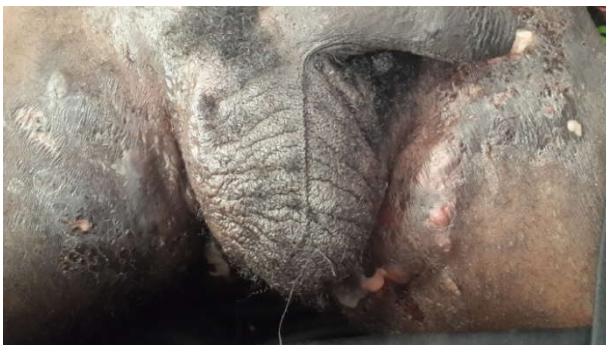

Figure 10. Case 2 KA Lesions on both thighs

### The out come in our patients

The Case 1 patient never really improved on all forms of treatment administered. The lesions were biopsied and the histological diagnosis was Keratoacanthoma. The patient was followed up for years until he died in the sixth year of care. Our Case 2 is a Keratoacanthoma patient and is being followed up. The treatment still remained a challenge.

## DISCUSSION AND CONCLUSION

Keratoacanthomas are fast-growing, solitary, cutaneous neoplasm that usually show spontaneous regression (Jorge Garcia-Zuazaga, 2009). In some patients like our two case reports, the fast-growing, solitary, cutaneous neoplasms never regress. They have been described Clinically as follows: A keratoacanthoma larger than 20 to 30mm (Jorge Garcia-Zuazaga, 2009). Both our patients had KA lesions that fitted this description. The lesions in the two patients were giant variants of Keratoacanthoma and had aggressive behavior. Case 1 had an aggressive lesion on his left gluteus and the Case 2 had aggressive lesions in the axillae, and thighs. Jorge Garcia-Zuazaga et al presented a case of a 61-year-old woman with a rapidly growing tumor on her left arm. Here presented were two men who had aggressive lesions.

It is therefore, evident that KA can affect both sexes. KA is not very common in Zambia thus our report in two males over a period of six years. In America, keratoacanthoma (KA) in a white US population studied in Hawaii showed an estimated incidence of 106 cases per 100,000. Niebuhr M et al also reported that keratoacanthoma incidence was equal to SCC and the common report of incidence ratio of keratoacanthoma to SCC was 1to3 (Niebuhr, 2009). No Zambian studies had been done and not many cases were being seen. Internationally; the studies done in the Japanese, Filipino, and Hawaiian populations estimated the KA incidence to be 22, 7, and 6 cases per 100,000 population, respectively. Approximately one fifth to one sixteenth of the incidence rate found in American whites. In other studies, the ratio of keratoacanthoma to SCC ranged from 1:0.6 to 1:5 in different geographic locations (4). In terms of race, Keratoacanthoma seems to be less common in darker-skinned individuals. There seems to be no studies to prove it in Zambia.

In the distribution of sex: Men are at a higher risk than women. The male-to-female ratio for keratoacanthoma being 2:1. We had not seen a woman with this condition so far. Besides, we have had no prevalence studies on this issue in Zambia. As regarding age, Keratoacanthoma has been reported in all age groups, but incidence increases with age. Keratoacanthoma is rare in persons younger than 20 years of age (Keratoacanthoma, 2004): It is known that people who have a higher risk of developing KA are people who, have prolonged exposure to sun, those with naturally fair skin, those with compromised immune systems, those that frequently use a tanning bed and those that are over the age of 60 years. Our patients were all not fitting the commonly occurring KA disease. They were both dark skinned people and were below the age of 60. However they were suspected to be HIV positive which could have led them to Immunocompetent status. Men are also at a higher risk than women; we had not seen a woman with this condition so far. The picture of the face of a European patient showing Generalized eruptive keratoacanthomas (also known as "Generalized eruptive keratoacanthoma of Grzybowski") showed a cutaneous condition, a variant of keratoacanthomas, characterized by hundreds to thousands of tiny follicular keratotic papules over the entire body. One of our patients also had this Generalized eruptive keratoacanthomas. Keratoacanthoma is a condition that occurs in Zambia, however it is not common and does not fit the European disease. It seem to be associated with immunocompromise in some of our patients.

**REFERENCES**

- Freedberg, et al. (2003). Fitzpatrick's Dermatology in General Medicine. (6th ed.). McGraw-Hill. ISBN 0-07-138076-0
- James, William, Berger, Timothy, Elston, Dirk 2005. Andrews' Diseases of the Skin: Clinical Dermatology. (10th ed.). Saunders. ISBN 0-7216-2921-0
- Jorge Garcia-Zuazaga, Malcolm Ke, and Patrick Lee, 2009. Giant Keratoacanthoma of the Upper Extremity Treated with Mohs Micrographic Surgery. A Case Report and Review of Current Treatment Modalities. *J Clin Aesthet Dermatol.* Aug; 2(8): 22–25.
- Keratoacanthoma | Definition & Patient Education – Healthline [www.healthline.com/health/keratoacanthoma](http://www.healthline.com/health/keratoacanthoma)
- Niebuhr M et al. 2009. Giant Keratoacanthoma in an Immunocompetent patient with detection of HPV11; *Hourtarzt.* 60(3);229-32 ISSN1432-1173.)
- Niezgoda, Anna, Niezgoda, Piotr, Czajkowski, Rafal 2015. Novel Approaches to Treatment of Advanced Melanoma: A Review of Targeted Therapy and Immunotherapy *BioMed Research International*
- Schwartz RA (February 2004). "Keratoacanthoma: a clinicopathologic enigma". *Dermatol Surg.* 30 (2 Pt 2): 326–33; discussion 333. doi:10.1111/j.1524-4725.2004.30080.x.

\*\*\*\*\*