



Full Length Research Article

TREATMENT OF PATELLAR DISLOCATION IN CHILDREN - A CASE EXAMPLE AND SURGICAL TECHNIQUE

***Surbhit Rastogi, Hitesh Dawar, Sayim Wani and Deepak Raina**

Department of Orthopaedics, Indian Spinal Injuries Centre, Sector-C, Vasant Kunj,
New Delhi - 110070, India

ARTICLE INFO

Article History:

Received 17th September, 2016
Received in revised form
20th October, 2016
Accepted 29th November, 2016
Published online 30th December, 2016

Key Words:

Patellar dislocation in children;
MPFL reconstruction;
Paediatric Knee injuries;
Paediatric surgery.

Copyright©2016, Surbhit Rastogi et al. This is an open access article distributed under the Creative Commons Attribution License, which permits unrestricted use, distribution, and reproduction in any medium, provided the original work is properly cited.

ABSTRACT

Lateral patellar dislocation is a common knee injury in paediatric population; medial patellofemoral ligament (MPFL) is frequently damaged structure in such injuries. Treatment of patellar dislocation in the skeletally immature patients is presented with specific discussion of surgical technique.

INTRODUCTION

Lateral patellar dislocation is a common knee injury in paediatric population (Nietosvaara, 1994), and is the most common acute knee injury in the skeletally immature. Over half of the cases cause recurrent patellar dislocations and pain. The mechanism of injury is most often with the foot planted and leg externally rotated. It can also occur while jump landing and/or decelerating. The medial patellofemoral ligament (MPFL) is frequently injured in an acute patellar dislocation (Sillanpaa, 2008; Avikainen, 1993; Bicos, 2007; Desio, 1998; Sallay, 1996 and Guerrero, 2009). Initial management of the paediatric patellar dislocation is mainly nonoperative. Surgery is indicated if a large osteochondral fragment is present or patella is highly unstable or extensively lateralised due to massive medial restraint injury. Surgical stabilisation is recommended if re-dislocations are frequent and cause pain, apprehension, or inability to attend sports activities. Reconstruction of the MPFL is a preferred surgical option in the skeletally immature knee, as operations that involve bone are contraindicated. MPFL reconstruction techniques that do not involve drilling or disruption of the periosteum near the

femoral physes are safe for the skeletally immature knee. Treatment of patellar dislocation in the skeletally immature patient is presented with specific discussion of surgical technique.

Epidemiology and predisposing factors

Population-based studies have estimated annual incidence rate of first-time (primary) patellar dislocations in children (Nietosvaara, 1994 and Fithian, 2004) of about 43 / 100 000. Buchner *et al* (2005) reported a 52% re-dislocation rate in patients aged <15 years compared with 26% for the entire group. Similarly, Cash and Hughston (1988) showed a 60% incidence of re-dislocation in children aged 11-14 years compared with 33% in those aged 15-18 years. The potential risk factors for primary patella dislocations include trochlear dysplasia, patella alta, increased tibial tubercle-trochlear groove (TT-TG) distance as measured by axial computed tomography (CT) or magnetic resonance images, and patellar tilt.(9) Risk factors reported for recurrent patella dislocation after primary dislocation include a young age at the time of the primary dislocation, the female sex, and dysplasia of the patellofemoral joint (Nietosvaara, 1994; Dejour, 1994 and Nikku, 2005).

***Corresponding author: Surbhit Rastogi,**

Department of Orthopaedics, Indian Spinal Injuries Centre, Sector-C,
Vasant Kunj, New Delhi - 110070, India

Materials and Methods - Case Example

Clinical findings and physical examination

A 16 year old girl presented with repeated falls while running, accompanied by pain and swelling in the knee since 4 years. She gave a history that whenever she fell while running she noticed that her patella always moved outwards towards lateral side but also spontaneously reduced by itself. Clinical examination revealed swelling and tenderness over medial aspect of knee and a positive Apprehension Test.

Imaging

Plain radiographs were obtained, including an anteroposterior, true lateral, and an axial knee view to look for associated risk factors, including patella alta and trochlear dysplasia, as well as identifying the patella position with possible associated lateral patella translation and/or tilt. The radiographs were normal. MRI was done which revealed complete MPFL disruption. Sometimes on Xrays, large osteochondral fractures can be seen, though chondral damage without an associated bony fragment is not visible on plain radiographs. MRI scan has been recommended in patients who have recurrent patella dislocation. It has been shown that by using a MRI, the MPFL disruption or primary injury location can be visualised. (13,14) On MRI, the disruption can be visualised as complete, if fibres in the expected region of the MPFL are completely discontinuous or appear absent with extensive surrounding oedema. Sometimes more than one injury site can be seen, (7,14,15) especially in mid-substance tears. This may represent partial discontinuity, suggesting MPFL elongation rather than a total disruption. However, the competency of the remaining ligament can be questioned.

Surgical Management

Medial Patellofemoral Ligament - anatomical considerations

The MPFL has been described as the most important medial restraint against lateral patellar displacement (Desio, 1998; Hautamaa, 1998 and Conlan, 1993). It acts as a check rein between the medial femoral condyle and the patella. The MPFL is a vertically oriented extra-capsular structure, found in layer 2 of the three layered description by Warren and Marshall (Warren, 1979). It attaches to the femur 5-10 mm proximal and 2-5 mm posterior to the medial epicondyle, (Laprade, 2007) in the saddle between the medial epicondyle and the adductor tubercle. The adductor tubercle is a readily palpable bony prominence and a more discrete anatomical point, and may be a preferred landmark for locating the femoral insertion of the MPFL during surgery. The MPFL attaches approximately 2 mm anterior and 4 mm distal to the adductor tubercle (Laprade, 2007). The width of the MPFL at the femoral insertion is approximately 10 mm. (Baldwin, 2009). The patella attachment of the MPFL is approximated at the junction of the proximal and middle thirds of the patella, (Nomura, 2005), typically at the location where the perimeter of the patella becomes more vertical. With a mean width of 28 mm, (Guerrero, 2009; Laprade, 2007) it is wider than its femoral attachment.

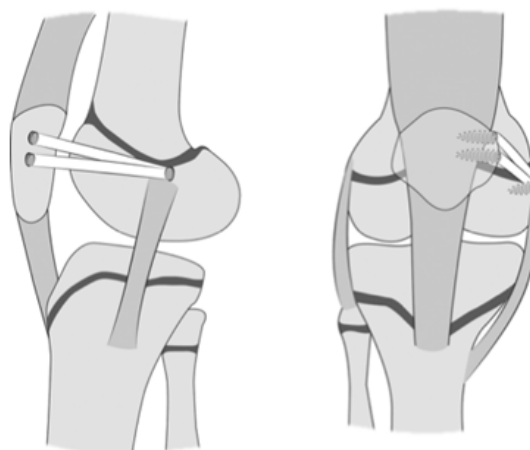
Indication for surgery

The goal is surgical stabilisation of the patella to prevent further lateral dislocations, while allowing return to a full and

active lifestyle. The goal of an MPFL repair or reconstruction is to restore the loss of the medial soft-tissue patella stabiliser, which is injured and/or is chronically lax due to recurrent patellar dislocations. One can surgically restore the function of the MPFL with an acute repair, a late repair, or a reconstruction.

MPFL reconstruction in Children

An examination under anaesthesia can be used to document excessive medial laxity (excessive lateral patellar translation) without guarding or apprehension. Arthroscopy is useful to stage articular cartilage lesions, though MRI detection is preferable if cartilage repair is not required. When the patella is near full extension, proximal to the deepening of the trochlear groove, the major restraints to patellar displacement are the soft tissues, particularly the MPFL. (Desio, 1998; Hautamaa, 1998; Conlan, 1993). As the knee flexion progresses, the major restraint to patellar displacement is femoral trochlear geometry, particularly the lateral wall of the trochlea (Arendt, 2002; Feller, 2007 and Farahmand, 1998). The goal of the reconstructed graft is to allow the patella to enter the trochlea smoothly in early flexion, without medial patella facet overload in deeper flexion. The ideal length change behaviour (iso-anatomic length) for an MPFL graft has not been established, though how the graft should behave during knee flexion is reported in both in vitro studies and modelling studies, (Farahmand, 1998). Avoiding over-constraint of the graft is very important. After the graft is fixed, one should observe the arc of passive knee motion, particularly in early flexion. When the patella is manually displaced laterally at 0° of knee flexion, there should be laxity in the system with a firm end point (check rein). At 30° of knee flexion, one should have approximately 8 mm of lateral patellar translation with gentle manual force (Hautamaa, 1998).



Sequence of Steps for MPFL Reconstruction (Figure 1)

Figure 1. Modified MPFL reconstruction technique. We docked the 2 ends of the graft in the superior-medial patella using partial socket tunnels, resulting in placement of the femoral attachment in a socket tunnel distal to the physis

MPFLreconstructions in children with wide open physes offer additional complexities regarding graft fixation. Surgical procedures that avoid tunnel or screw fixation at or near the distal femoral physis are favoured. Avoiding transverse patella tunnels and screw fixation within patella tunnels is ideal. Suitable techniques for patients with open growth plates

include the adductor magnus (AM) tendon (Avikainen, 1993) the adductor sling technique, (Arendt, 2010) and the medial collateral ligament sling technique. In this case, we reconstructed MPFL using Hamstrings' Autograft, trying to achieve an anatomical reconstruction. We docked the two ends of the graft in the superior-medial patella using sockets and secured the femoral site attachment in a socket tunnel distal to the physis. Advantages of this technique included minimisation of the risk of injury to the growth plate and still enabling accurate anatomic positioning of the hamstring autograft; bony fixation, which might be stronger than fixation with soft tissue alone; use of hamstrings' tendon allows robust reconstruction of the MPFL, which might be stronger than the original MPFL; small incisions are required; early range of motion and weight bearing are allowed; and the effect of longitudinal growth on the isometrics of the reconstructed graft is minimised.

- Perform diagnostic arthroscopy and treatment of chondral injury.
- Harvest the ipsilateral hamstring tendon: semitendinosus or gracilis.
- Expose the area of the medial epicondyle of the distal femur in flexion.
- Use a guide wire under fluoroscopy to identify the exact position of the femoral socket and create a socket distal to the distal femoral growth plate with a typical diameter of 6 mm and depth of 15 to 20 mm.
- Expose the superior-medial margin of the patella.
- Use a guide wire and reamer to create 2 socket tunnels approximately 15 mm long and 4.5 mm diameter; in smaller children, only 1 socket is used.
- Create a soft-tissue space between the fascia and synovium linking the patella and femoral sockets.
- Carefully measure the distance between the femoral and patellar sockets; this distance should be measured in 30 degree of flexion, with patella held in a reduced position on the trochlea.
- Prepare a double limb graft typically measuring the distance between the femoral and patellar sockets, adding 15 mm for each socket, usually adding up to a final length of 85 to 100 mm.
- Fix the graft on the femur with a tenodesis screw measuring 6.25 to 7 mm in diameter; secure the free ends with a No. 2-0 suture loop.
- Using passing sutures, pass the graft through the previously prepared soft-tissue space to the superior half of the patella.
- Dock the free ends of the graft into the 2 sockets at the patella with two 4.75-mm tenodesis screws while the knee is in 30 degree of flexion.

DISCUSSION

We believe that this technique has advantages in relation to previously published approaches to reconstruct the MPFL, minimising the risk of iatrogenic injury to the distal femoral growth plate in skeletally immature patients and resulting in a surgically sound and anatomic reconstruction. Relative contraindications for this procedure are severe osteopenia or inability to participate in postoperative physical therapy. Anatomic reconstruction of the MPFL is regarded as a safe treatment for patellofemoral instability in children and adolescents. MPFL reconstruction with hamstring autograft

may reliably be performed in children and adolescents with patellar instability with open growth plates. However, careful intra-operative fluoroscopic guidance is required to avoid injury to the open distal femoral growth plate in skeletally immature patients. In general, MPFL reconstructions achieve good postoperative patellar stability with re-dislocation rates <4%. In this case CPM 0-90 degrees was started from first post-operative day, and the patient was mobilised full weight bearing with ROM knee brace for 6 weeks, and gradually shifted to strenuous activities.

Contraindications for MPFL Reconstruction

An MPFL reconstruction is not indicated for isolated patellofemoral pain. Physical examination must be consistent with laxity of medial patellar restraint, and a history consistent with lateral patella dislocation must be elicited. Pain and "giving out" episodes are not sufficient criteria for establishing this diagnosis. An MPFL reconstruction is not indicated for excessive lateral patellofemoral tilt and/or translation on imaging, without history and physical examination evidence of recurrent lateral patellar dislocations. The MPFL is not meant to "pull" the patella into position. Its role is to stabilise a located patella against excessive lateral force. The permanently dislocated or habitually dislocating patella, which dislocates in flexion, is due to a host of factors, including both bony and soft tissue components. Rotational and coronal plane deformities of the femur and tibia may need to be addressed in these cases in skeletal maturity. MPFL laxity is a result and not a cause of such an extreme alteration of the extensor mechanism.

Conclusions

First-time patellar dislocation is a common knee injury among the skeletally immature; progression to recurrent instability is variable but is reported in about 50% in select populations. (Elias, 2002 and Nomura, 1999). If non operative management has failed and instability compromises an active lifestyle and sports participation, surgery may be necessary. This chapter presents a technique for MPFL reconstruction that is safe in the age group with wide open physes.

REFERENCES

- Arendt, E.A., Fithian, D.C., Cohen, E. 2002. Current concepts of lateral patellar dislocation. *Clin Sports Med*, 21:499-519.
- Arendt, E.A., Zaffagnini, S., Dejour, D. 2010. MPFL reconstruction: Adductor sling technique. *Patellofemoral Pain, Instability and Arthritis*, Vol I. New York, NY, Springer, 2010, p I.
- Avikainen, V.J., Nikku, R.K., Seppanen-Lehmonen, T.K. 1993. Adductor magnus tenodesis for patellar dislocation. Technique and preliminary results. *Clin Orthop Relat Res* 297:12-16.
- Baldwin, J.L. 2009. The anatomy of the medial patellofemoral ligament. *Am J Sports Med* 37:2355-2362.
- Bicos, J., Fulkerson, J.P., Amis, A. 2007. Current concepts review: The medial patellofemoral ligament. *Am J Sports Med*, 35:484-492.
- Buchner, M., Baudendistel, B., Sabo, D., et al. 2005. Acute traumatic primary patellar dislocation: Long-term results comparing conservative and surgical treatment. *Clin J Sport Med*, 15:62-66.

- Cash, J.D., Hughston, J.C. 1988. Treatment of acute patellar dislocation. *Am J Sports Med*, 16:244-249.
- Conlan, T., Garth, W.P., Lemons, J.E. 1993. Evaluation of the medial soft-tissue restraints of the extensor mechanism of the knee. *J Bone Joint Surg Am*, 75A:682-693.
- Dejour, H., Walch, G., Nove-Josserand, L. et al, 1994. Factors of patellar instability: An anatomic radiographic study. *Knee Surg Sports Traumatol Arthrosc* 2:19-26.
- Desio, S.M., Burks, R.T., Bachus, K.N. 1998. Soft tissue restraints to lateral patellar translation in the human knee. *Am J Sports Med*, 26:59-65
- Elias, D.A., White, L.M., Fithian, D.C. 2002. Acute lateral patellar dislocation at MR imaging: Injury patterns of medial patellar soft-tissue restraints and osteochondral injuries of the inferomedial patella. *Radiology* 225:736-743.
- Farahmand, F., Senavongse, W., Amis, A.A. 1998. Quantitative study of the quadriceps muscles and trochlear groove geometry related to instability of the patella femoral joint. *J Orthop Res* 16:136-143.
- Feller, J.A., Amis, A.A., Andrish, J.T., et al. 2007. Surgical biomechanics of the patella femoral joint. *Arthroscopy* 23:542-553.
- Fithian, D.C., Paxton, E.W., Stone, M.L., et al. 2004. Epidemiology and natural history of acute patellar dislocation. *Am J Sports Med*, 32:1114-1121.
- Guerrero, P., Li, X., Patel, K. et al. 2009. Medial patellofemoral ligament injury patterns and associated pathology in lateral patella dislocation: An MRI study. *Sports Med Arthrosc Rehabil Ther Technol* 1:17.
- Hautamaa, P.V., Fithian, D.C., Pohlmeier, A.M., et al. 1998. The medial soft tissue restraints in lateral patellar instability and repair. *Clin Orthop Relat Res*, 349:174-182.
- Laprade, R.F., Engebretsen, A.H., Ly, T.V., et al, 2007. The anatomy of the medial part of the knee. *J Bone Joint Surg Am* 89:2000-2010.
- Nietosvaara, Y., Aalto, K., Kallio, P.E. 1994. Acute patellar dislocation in children: Incidence and associated osteochondral fractures. *J Pediatr Orthop*, 14:513-515.
- Nikku, R., Nietosvaara, Y., Aalto, K. et al. 2005. Operative treatment of primary patellar dislocation does not improve medium-term outcome. *Acta Orthop* 76:699-704.
- Nomura, E. 1999. Classification of lesions of the medial patello-femoral ligament in patellar dislocation. *Int Orthop*, 23:260-263.
- Nomura, E., Inoue, M., Osada, N. 2005. Anatomical analysis of the medial patella femoral ligament of the knee, especially the femoral attachment. *Knee Surg Sports Traumatol Arthrosc* 13:510-515.
- Sallay, P.I. 1996. Acute dislocation of the patella. A correlative path anatomic study. *Am J Sports Med*, 24:52-60.
- Sillanpaa, P., Mattila, V.M., Iivonen, T. et al. 2008. Incidence and risk factors of acute traumatic primary patellar dislocation. *Med Sci Sports Exerc*, 40:606-611.
- Sillanpaa, P.J., Peltola, E., Mattila, V.M., et al. 2009. Femoral avulsion of the medial patella femoral ligament after primary traumatic patellar dislocation predicts subsequent instability in men: A mean 7-year nonoperative follow-up study. *Am J Sports Med*, 37:1513-1521.
- Warren, R.F., Marshall, J.L. 1979. The supporting structures and layers on the medial side of the knee. *J Bone Joint Surg Am*, 61A:56-62.
