



Full Length Research Article

COMPARITIVE STUDY OF MANAGEMENT OF PEPTIC ULCER PERFORATION

***¹Dr. Upendra Bhardwaj, ²Dr. Aruna Goyal, ³Dr. Dilaverm and ³Dr. Nikhil**

¹Deptt. of Surgery, G.R.M.C., Gwalior

²Department of Obstetrics and Gynaecology, S.N. Medical College Agra

³E.S.I.C. Medical College, Faridabad

ARTICLE INFO

Article History:

Received 17th September, 2016
Received in revised form
13th October, 2016
Accepted 20th November, 2016
Published online 30th December, 2016

Key Words:

Peptic Ulcer,
Perforation,
Erosion.

Copyright©2016, Dr. Upendra Bhardwaj et al. This is an open access article distributed under the Creative Commons Attribution License, which permits unrestricted use, distribution, and reproduction in any medium, provided the original work is properly cited.

ABSTRACT

Peptic ulcers include following gastric ulcers and Duodenal ulcers. The aim of our study is to study the various method and management of peptic ulcer perforation and significance of these in post operative period. The treatment of perforated ulcer disease continues to evolve because of recent advances in pharmacology, bacteriology, and operative technique. The main surgical treatment option was simple closure with Graham patch and laparoscopic.

INTRODUCTION

Peptic ulcer is a breaching of epithelium in the upper gastrointestinal tract (Esophagus, Stomach and Duodenum) and more rarely in jejunum and in a Meckel's diverticulum. It consists of ulcers that go deeper than the "muscularis mucosa" layer. The term "peptic" is derived from the fact that for centuries it was believed that the sole cause of peptic ulcers was due to excessive production of gastric juice, the surplus hydrochloric acid and pepsin being considered only culprits of the ulcers. There was even the motto "no acid, no ulcer" coined by Schwartz¹ one of the most respected medical authorities at that time. After this initial motto of "no acid, no ulcer", several interplaying factors were found to be responsible for peptic ulcer. The multifactorial complexity of the disease was considered to be the result of imbalance between aggressive and defensive factors. Aggressive factors are Hydrochloric acid, pepsin, digestive enzymes, ethanol, caffeine from coffee, methyl xanthines from chocolate, smoking, paper, spices, bile acids, stress, medications that are damaging to the upper gastrointestinal tract defensive factors include mucobincarbonate layer, prostaglandins products, cellular renovation and blood flow. Then the Helicobacter pylori was discovered by chance. The Australian researchers Warren and Marshall² made this historical finding in 1982.

Surprisingly when they returned after a long holiday, to their laboratory, the already sown gastric fragments from peptic ulcer were Positive for bacterium colonies. This explained the imbalance between aggressive and defensive factors, that caused most of the peptic ulcer cases. Now the peptic ulcer turned out to be misnomer once we consider the importance of H. pylori, and nowadays there is a proposition to change it to Infecto-peptic ulcer.

MATERIALS AND METHODS

This prospective study of 2 years in which a total 100 patients were recruited. We had managed 33 had laparoscopic surgical method and all rest 67 patients with open surgery method. The main surgical treatment option was simple closure with Graham patch. Follow up after discharge from the hospital 14 days, 28 days, 1 & 1/2 month, 3 months and 6 months. The data was analyzed in statistical program SPSS version 20.0. Fisher's exact test of chi-squared was applied for categorical variables to calculate frequencies and percentages among the groups.

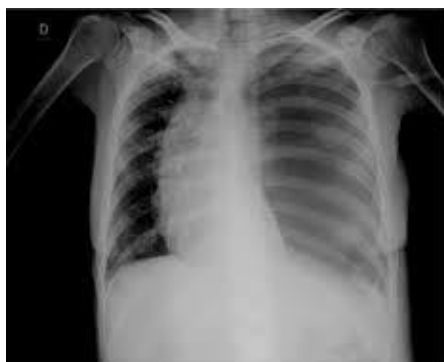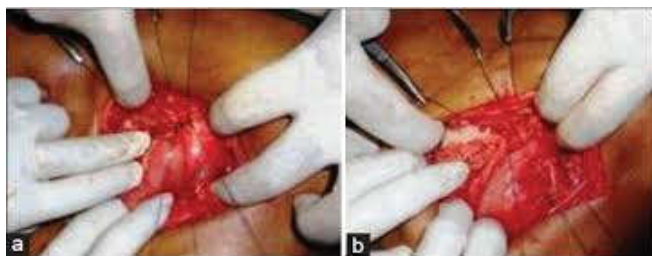
RESULTS

100 patients underwent surgical repair of perforated peptic ulcer disease (33 laparoscopic repairs and 67 Graham patch repairs; the common number of patients being in the 20 to 50

**Corresponding author: Dr. Upendra Bhardwaj,
Deptt. of Surgery, G.R.M.C., Gwalior.*

year age group. There was no difference in age and the time to surgery in both groups. The mean operating time of the laparoscopic patch repair was significantly longer than the open procedure (55 to 65 minutes; $p = 0.001$). In addition there was a significant decrease in the time that the nasogastric tube (mean: 6 days laparoscopic versus 8 days open), and abdominal drain (mean: 6 days laparoscopic versus 8 days open) were required during the postoperative period. Patients who had undergone laparoscopic repair returned to normal diet (mean: 7 days laparoscopic versus 9 days open). In addition, patients who had undergone laparoscopic repair required a shorter in-patient hospital stay (mean: 7 days laparoscopic versus 9 days open).

Operating time	Laparoscopic N 33	Open 67	P value
Operating time	55-65m	50-60m	0.001
Nasogastric tube	5-7d	7-9d	0.001
Abdominal drain	5-7	7-9	0.001
Oral	6-7	8-10	0.001
Hospital stay	7-8	8-11	0.001



Gas under Diaphragm

DISCUSSION

Laparoscopic repair is a viable and safe surgical option for patients with perforated peptic ulcer disease and should be considered for all patients, providing that the necessary expertise is available. We found that younger age groups (20-50 years) are frequently affected due to the prevailing young age structure of U.P. population. Laparoscopic repair of perforated peptic ulcer is a safe and reliable procedure and is proven to be efficient. Even though it was associated with longer operating time, it had no impact on outcome. It had less postoperative pain, reduced chest complications and reduced analgesic usage, shorter postoperative hospital stay, and earlier return to normal daily activities than the conventional open repair.

It has lesser morbidity and mortality as compared to open group. Data from the present study indicate that laparoscopic surgical treatment of patients with peptic ulcer perforation can be implemented and completed safely in a large proportion of patients with this life-threatening condition, given that the responsible surgical team has the appropriate technical expertise. Upper GI endoscopy is the method of choice for investigation of uncomplicated ulcers as well as bleeding peptic ulcers, while plain X-ray abdomen is still the preferred investigation in suspected cases of perforation. We need to do study with more number of cases as to claim advantage of laparoscopic surgery.

Conclusion

Based on our study, we conclude that the laparoscopic repair of perforated peptic ulcer is safe and reliable procedure, it has lesser morbidity and mortality compare to open surgery, given that responsible surgical team has appropriate technical expertise.

REFERENCES

- Ates, M., Coban, S., Sevil, S., Terzi, A. 2008. The efficacy of laparoscopic surgery in patients with peritonitis. *SurgLaparoscEndoscPercutan Tech*, 18(5):453-456
- Ates, M., Sevil, S., Bakircioglu, E., Colak, C. 2007. Laparoscopic repair of peptic ulcer perforation without omental patch versus conventional open repair. *J LaparoendoscAdvSurg Tech A*, 17(5):615-619
- Leeman, M.F., Skouras, C., Paterson-Brown, S. 2013. The management of perforated gastric ulcers. *Int J Surg*, 2013;
- Liubskaja, L.A., Kolesnikovallu, Grigor'evalu V. 2013. Clinical and endoscopic features and treatment problems in patients with perforated duodenal ulcer. *TerArkh*. 2013; 85(12):51-4.
- Møller, M.H., Vester-Andersen, M., Thomsen, R.W. 2013. Long-term mortality following peptic ulcer perforation in the PULP trial a nationwide follow-up study. *Scand J Gastroenterol*. Feb; 48(2):168-75.
- Nomani, A.Z., Malik, A.K., Qureshi, M.S. 2014. A new prognostic scoring system for perforation peritonitis secondary to duodenal ulcers. *J Pak Med Assoc.*, 2014 Jan;64(1):50-6.
- Seelig, M.H., Seelig, S.K., Behr, C., Schonleben, K. 2003. Comparison between open and laparoscopic technique in the management of perforated: gastroduodenal ulcers. *J ClinGastroenterol* 37(3):226-229
- Thorsen, K., Soreide, J.A., Kvaloy, J.T., Glomsaker, T., Soreide, K. 2013. Epidemiology of perforated peptic ulcer: age- and gender-adjusted analysis of incidence and mortality. *WorldJ Gastroenterol*, 19: 347-354.
- Towfigh, S., Chandler, C., Hines, O.J., and McFadden, D.W. Outcomes from peptic ulcer surGuglielminotti P, Bini R, Fontana D, Leli R. Laparoscopic repair for perforated peptic ulcers with U-CLIP(R). *World J Emerg Surg*. 2009 Jul 29;4:28. gery have not benefited from advances