



## Full Length Review Article

### ENDODONTIC MANAGEMENT OF MIDDLE MESIAL CANAL IN MANDIBULAR SECOND MOLAR USING CONE BEAM COMPUTED TOMOGRAPHY

\*<sup>1</sup>Dr.Ritu Meel, Dr. Pratibha Chaudhary and <sup>2</sup>Dr. Neetu Meel

<sup>1</sup>Department of Conservative Dentistry and Endodontics, Mahatma Gandhi University of Medical Sciences and Technology, Jaipur (302022)

<sup>2</sup>Department of Orthodontics and Dentifacial Orthopaedics, Rajasthan University of Health Science, Jaipur(302033)

#### ARTICLE INFO

##### Article History:

Received 07<sup>th</sup> September, 2016

Received in revised form

30<sup>th</sup> October, 2016

Accepted 16<sup>th</sup> November, 2016

Published online 30<sup>th</sup> December, 2016

#### ABSTRACT

This clinical case report describes the management of the mandibular molar with three separate mesial canals including middle mesial canal, in which the diagnosis was confirmed with the help of cone beam computerized tomography.

#### Key Words:

Mandibular molar,  
Middle mesial canal,  
Intraoral periapical radiograph,  
Cone Beam Computed Tomography.

Copyright©2016, Dr.Ritu Meel et al. This is an open access article distributed under the Creative Commons Attribution License, which permits unrestricted use, distribution, and reproduction in any medium, provided the original work is properly cited.

#### INTRODUCTION

As right quoted by MT Barrett, "of all the phases of anatomic study in human system, one of the most complex is the pulp cavity morphology." The external and internal morphology of the tooth varies from person to person. For each tooth in permanent dentition, there is a wide range of variation reported in literature with the respect to frequency of occurrence of the number and shape of the canal in each root, the number of roots and incidence of molar root fusion (Ingle, Bakland). A number of factors contribute to the variation found in these studies, such as the ethnic background, age of the patient, gender and also methods of used to assess these teeth (Fava, 2001 and Cleghorn, 2006). As a cause of treatment failures, lack of working knowledge of pulp anatomy ranks second only to errors in diagnosis and treatment planning. Knowledge of the pulp anatomy must be three-dimensional. Over the years, there have been numerous studies that describe the morphology of teeth, including mandibular first molars. Skidmore and Bjorndal, Pineda and Kuttler, and Vertucci

(Skidmore, 1971 and Pineda, 1972 and Vertucci, 1984), have all reported on the morphology of the mandibular first molar. According to Vertucci (Vertucci, 1984), the mandibular second molar is similar to the first except the roots are shorter, the canals are more curved and the range of variations broader. The root canal anatomy of mandibular second molars has been described by a number of investigators. The main areas of dispute are the number of roots possessed by mandibular second molars, and the type and shape of the canals. Meanwhile, an *in vitro* investigation of mandibular second molar root canal morphology has reported that 73% of mesial roots have one canal at the apex and 27% have two canals at the apex. In the distal root, 95% have one canal at the apex (Peiris, 2007). In addition, Beatty and Krell (Beatty, 1987). Documented a mandibular second molar with five canals, three canals in the mesial root and two in the distal root. C shape canal and single canal as well as single rooted mandibular second molar is also documented. However, these canal variations have commonly been found in two-rooted mandibular second molars. Every attempt should be made to find and treat all root canals to ensure successful endodontic treatment. The clinician must have a thorough understanding of normal anatomy and of common variations. The clinician must also be prepared to identify those teeth that exhibit unusual anatomical configurations (Nallapati, 2005). Intraoral

#### \*Corresponding author: Dr.Ritu Meel

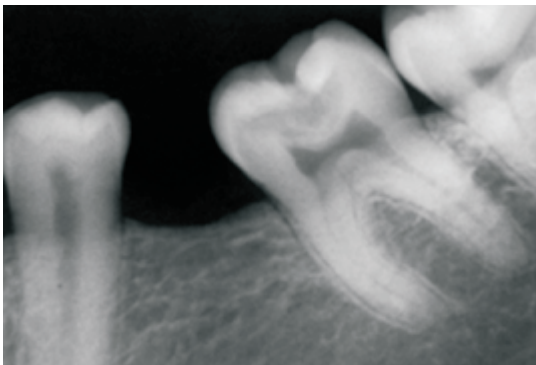
Department of Conservative Dentistry and Endodontics, Mahatma Gandhi University of Medical Sciences and Technology, Jaipur (302022)

periapical radiographic (IOPA) examination is important for the evaluation of the number of roots and canal configuration. However, it has inherent limitation to assess the root canal system completely as it provides only two dimensional image. Conventional multidetector computed tomography (CT) imaging has been widely used in medicine since the 1970s and was introduced in the endodontic field in 1990. Recently, as an alternative to multidetector CT imaging, cone beam CT (CBCT) imaging has been shown to provide three dimensional images at reduced dose as it is possible to take small field (FOV) view images. Cotton et al reported various useful applications of CBCT imaging in endodontics including identification of complex root canal system. This case report describes rare cases of mandibular second molar with four canals– three in mesial root (MB, MM, ML – Mesio buccal, Middle Mesial, Mesiolingual) and one canal in distal root.

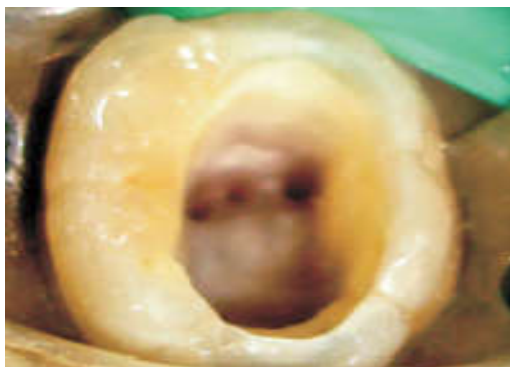**Case Report**

A 30 year old patient reported in the Department of Conservative Dentistry and Endodontics with the chief complaint of pain in the lower right back tooth region. Pain was moderate, intermittent and increased while chewing food. The patient’s medical history was non-contributory. Clinical examination revealed that tooth 47 had deep occlusal caries. The tooth was tender to percussion and gave delayed response to electric pulp tester.

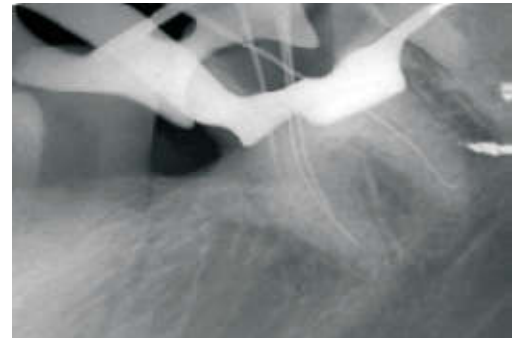
canal and one distal canal) were located (Figure b). Working length were estimated by using an electronic apex locator (propexII, Dentsply) and then confirmed with radiograph (Figure c). Chemomechanical preparation was then scheduled in the next appointment before which the patient was sent for CBCT to confirm the unusual morphology (Figure d). In coronal third of CBCT view, three mesial canals, i.e., mesio buccal, middle mesial, mesio lingual (Figure d).



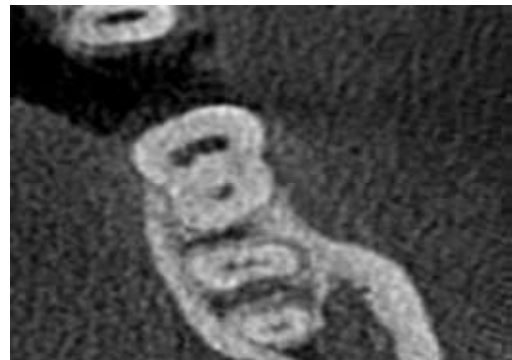**Figure 1a. Preoperative intraoral radiograph**



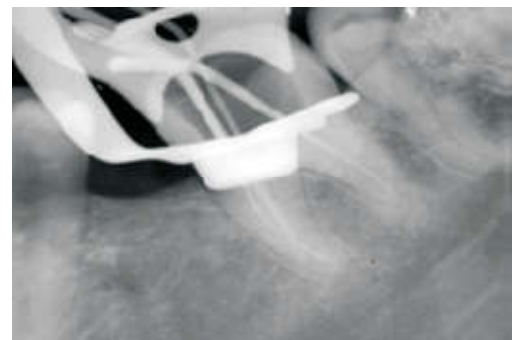
**Figure 1b. Clinical photograph showing five canals**



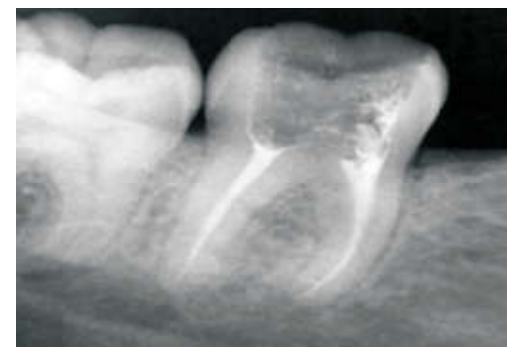**Figure 1c. working length determination radiograph**



**Figure 1d. CBCT image showing presence of five canals (coronal view)**



**Figure 1e. Master cone iopa**



**Figure f. Post-obturation intraoral periapical radiograph**

The clinical and radiographic findings led to a diagnosis of chronic irreversible pulpitis of the right mandibular second molar 47, necessitating endodontic therapy. Radiographic evaluation of the involved tooth indicated a deep occlusal caries approximating the pulp with apparently normal periapex (Figurea). After administering local anesthesia and rubber dam isolation, all carious tissue was remove an access cavity was prepared.Five orifices and canals were located (three mesial

All the canal were cleaned and shaped with Protaper Series nickel -titanium rotary instruments under copious irrigation with 5.25% sodium hypochlorite and normal saline. All canal were dried with absorbent points. A gutta-percha cone fit radiograph was made and the canal was obturated (Figure e and f). Using cold lateral compaction of gutta-percha and resin sealer. The patient experienced no post treatment discomfort and the tooth was referred for a full coverage restoration.

## DISCUSSION

Before root canal treatment is performed, the clinician should ideally have adequate knowledge of the pulp chamber and internal anatomy of the teeth. All root canals should be accessed, cleaned, and shaped to achieve a hermetic obturation of the entire root canal space. There is an abundant amount of reports that relate the anatomic variations of mandibular molars (Cleghorn, 2008). This should induce the clinician to accurately observe the pulp chamber floor to locate possible canal orifices. This will increase the long term prognosis of endodontic therapy. Searching for additional canal orifices should be standard practice for clinicians. A round bur or an ultrasonic tip can be used for removal of any protuberance from the mesial axial wall which would prevent direct access to the developmental groove between MB and ML orifices. This developmental groove should be carefully checked with the sharp tip of an endodontic explorer. If depression or orifices are located, the groove can be troughed with ultrasonic tips at its mesial aspect until a small file can negotiate this intermediate canal (Vertucci, 2005). A significant limitation in conventional radiography is that it yields a two dimensional image of a 3D object, which results in overlapping of the overlying structures. Therefore in this case report, the use of CBCT as a diagnostic tool in endodontics has been highlighted. In the present case, CBCT analysis was done to verify the presence of additional canals (Ankur Mahesh Banode, 2016). New technologies, such as the dental operating microscope and dental loupes, offer magnification and illumination of the operating field and substantially improve the visualization of root canal orifices (Barletta et al., 2008 and De Carvalho, 2000). It is possible that more cases may have been discovered with magnification and extra illumination. The presence of a third canal (middle mesial) in the mesial root of the mandibular molars has been reported to have an incidence of 0.95%-15% (Fabra-Campos, 1985). In almost all of the clinical cases reported until today, this canal joined the mesiobuccal or mesiolingual canal in the apical third (Fabra-Campos, 1985 and Vertucci, 2005). However a few mandibular first molars that had three independent canals in their mesial root have been reported (Cleghorn, 2006).

## Conclusion

Treating additional aberrant canals can be challenging, but the inability to find root canals may cause failures.

The evaluation of CBCT images can result in better understanding of root canal anatomy, which enables the clinician to investigate the root canal system and to clean, shape, and obturate it more efficiently.

## REFERENCES

- Ankur Mahesh Banode, 2016. Endodontic management of mandibular first molar with seven canals using conebeam computed tomography. *Contemporary Clinical Dentistry* | Apr-Jun | Vol 7 | Issue 2
- Barletta, F.B., Dotto, S.R., Reis, Mde, S., Ferreira, R., Travassos, R.M. 2008. Mandibular molar with five root canals. *Aust Endod J*, 34:129-32.
- Beatty, R.G., Krell, K. 1987. Mandibular molars with five canals: report of two cases. *J Am Dent Assoc*, 114:802-804.
- Cleghorn, B., Christie, W., Dong, C. 2006. Root and canal morphology of the human permanent maxillary first molar: A Literature Review. *J ENDOD*, 32:813-21.
- Cleghorn, B.M., Goodacre, C.J., Christie, W.H. 2008. Morphology of teeth and their root canal system. In: Ingle JI, Bakland LK, Baumgarthner JC: *ENDODONTICS*, 6th Edition. BC Decker: Inc, pp. 151-210
- De Carvalho, M.C., Zuolo, M.L. 2000. Orifice locating with a microscope. *J Endod*, 26:532-4.
- Fabra-Campos H. 1985. Unusual root anatomy of mandibular first molars. *J Endod*, 11:568-72.
- Fava, L.R. 2001. Root canal treatment in an unusual maxillary first molar: a case report. *Int Endod J.*, 34:649-53.
- Ingle, Bakland, Baumgartner. Morphology of teeth and their root canal system endodontics)(6 th edition ), chapter 6, 151-220.
- Nallapati S. 2005. Three canal mandibular first and second premolars: a treatment approach. A case report. *J Endod* 31;474-476.
- Peiris, R., Takahashi, M., Sasaki, K., Kanazawa, E. 2007. Root and canal morphology of permanent mandibular molars in a Sri Lankan population. *Odontology*, 95:16-23.
- Pineda, F., Kuttler, Y. 1972. Mesiodistal and buccolingual roentgenographic investigation of 7,275 root canals. *Oral Surg*, 33:101-10.
- Skidmore, A.E., Bjorndal, A.M. 1971. Root canal morphology of the human mandibular first molar. *Oral Surg*; 32:778-84.
- Vertucci F. 1984. Root canal anatomy of the human permanent teeth. *Oral Surg*, 58:589-99.
- Vertucci, F.J. 2005. Root canal morphology and its relationship to endodontic procedures. *Endod Topics*, 10:3-29.

\*\*\*\*\*