



Full Length Research Article

EOSINOPHILIA AS AN IMPORTANT INDICATOR OF HOOKWORM INFECTION IN OUR STUDY

***Govindarajalu Ganesan**

Department of General Surgery, Indira Gandhi Medical College and Research Institute, Puducherry-605009

ARTICLE INFO

Article History:

Received 19th June, 2016
Received in revised form
24th July, 2016
Accepted 30th August, 2016
Published online 30th September, 2016

Key Words:

Eosinophilia,
Severe eosinophilia,
Hookworm infection,
Upper gastro-intestinal endoscopy.

ABSTRACT

Objective: Eosinophilia is commonly reported to occur in hookworm infection. Hence a detailed study was done to highlight the importance of eosinophilia as an important indicator of hookworm infection diagnosed by doing upper gastro intestinal endoscopy.

Methods: A study of 1137 patients who had undergone upper gastro-intestinal endoscopy for a period of four years and eight months from May 2009 to December 2013 was carried out. In each of these 1307 patients, the first and second part of duodenum were carefully examined to find out the presence of hookworms. In all the patients found to have hookworms in duodenum, investigations were done to know about the presence or absence of eosinophilia and the presence of severe eosinophilia. The results were found as given below.

Results: Out of these 1137 patients, 14 patients found to have hookworms in duodenum while doing upper gastro-intestinal endoscopy were taken into consideration for our study. Out of these 14 patients with hookworms in duodenum, as many as 10 patients with hookworms in duodenum were found to have eosinophilia [71%]. Severe eosinophilia was found in 4 out of 10 patients with eosinophilia (40%). 4 patients did not have any eosinophilia [29%].

Conclusion: Hence, eosinophilia occurs commonly in patients with hookworm infection. Severe eosinophilia also occurs in significant number of patients with hookworm infection. Hence eosinophilia and severe eosinophilia is an important indicator of hookworm infection.

Copyright © 2016, Govindarajalu Ganesan. This is an open access article distributed under the Creative Commons Attribution License, which permits unrestricted use, distribution, and reproduction in any medium, provided the original work is properly cited.

INTRODUCTION

Eosinophilia occurs very commonly in hookworm infection (1 to 13). Hence a detailed study was done to highlight the importance of eosinophilia as an important indicator of hookworm infection diagnosed by doing upper gastro intestinal endoscopy.

MATERIALS AND METHODS

This study was conducted in the department of general surgery, Aarupadai Veedu Medical College and Hospital, Puducherry. A study of 1137 patients who had undergone upper gastro-intestinal endoscopy for a period of four years and eight months from May 2009 to December 2013 was carried out. In each of these 1137 patients, the first and second part of duodenum were carefully examined to find out the presence of hookworms. In all the patients found to have

hookworms in duodenum, investigations were done to know about the presence or absence of eosinophilia and severe eosinophilia and investigations were done to know about the presence or absence of anaemia. Anaemia is defined as haemoglobin < 12g/dl or 12g% in women and haemoglobin < 13g/dl or 13g% in men. Mild anaemia is taken as haemoglobin 10 to 12g/dl or g%, moderate anaemia is taken as haemoglobin 7 to 10g/dl or g% and severe anaemia is taken as haemoglobin < 7g/dl or g%. Eosinophilia is defined as eosinophils > or = 500 cells/cu.mm (14). Severe eosinophilia is defined as eosinophils > 1000 cells/cu.mm (4). The results were found as given below.

RESULTS

1. Out of these 1137 patients, 14 patients found to have hookworms in duodenum while doing upper gastro-intestinal endoscopy were taken into consideration for our study.
2. Out of these 14 patients with hookworms in duodenum, 4 patients did not have any eosinophilia [29%].

**Corresponding author: Govindarajalu Ganesan,*
Department of General Surgery, Indira Gandhi Medical College and Research Institute, Puducherry-605009

3. Out of these 14 patients with hookworms in duodenum, as many as 10 patients with hookworms in duodenum were found to have absolute eosinophil count $>$ or $=$ 500 cells/cu.mm or eosinophilia [71%].
4. 6 out of 10 patients with eosinophilia had absolute eosinophil count between 500 cells/cu.mm and 1000 cells/cu.mm.
5. 4 out of 10 patients with eosinophilia (40%) had absolute eosinophil count $>$ 1000 cells/cu.mm or severe eosinophilia

DISCUSSION

Absence of both eosinophilia and anaemia [1 patient]

1. One patient with hookworm infection in our study neither had eosinophilia [absolute eosinophil count - 160 cells/cu.mm] nor had anaemia [haemoglobin - 14 g%].
2. Eosinophilia only peaks at 5 to 9 weeks after the onset of infection, a period that coincides with the appearance of adult hookworms in the intestine (15).
3. Hence eosinophilia will not be present in the early stage of hookworm infection before 5 to 9 weeks after the onset of infection.

Absence of eosinophilia and presence of anaemia [3 patients]

1. 2 patients had mild anaemia without eosinophilia [1. haemoglobin 11.2 g%, absolute eosinophil count - 396 cells/cu.mm 2. haemoglobin 10 g%, absolute eosinophil count - 364 cells/cu.mm].
2. Single hookworm in duodenum found in the patient with mild anaemia [haemoglobin 10 g%] without eosinophilia [absolute eosinophil count - 364 cells/cu.mm] is shown in Fig 1.
3. The hookworm in duodenum is identified by its bent head which looks like a hook (Fig 1) and by its S-shaped appearance (16) (Fig 1).
4. Severe anaemia without eosinophilia was present in one patient in our study [haemoglobin 2.1 g%, absolute eosinophil count - 366 cells/cu.mm].

Mild eosinophilia [6 patients]

1. 6 out of 10 patients with eosinophilia had absolute eosinophil count between 500 cells/cu.mm and 1000 cells/cu.mm.
2. Single hookworm in duodenum with eosinophilia [absolute eosinophil count - 858 cells/cu.mm] seen in a patient in our study is shown in Fig. 2. The hookworm in duodenum is identified by its bent head which looks like a hook (Fig. 2) and by its S-shaped appearance (16) (Fig. 2).
3. Single hookworm in duodenum with eosinophilia [absolute eosinophil count - 870 cells/cu.mm] seen in a patient in our study is shown in Fig. 3. The hookworm in duodenum is identified by its bent head which looks like a hook (Fig. 3) and by its S-shaped appearance (16) (Fig. 3).
4. Hence eosinophilia is an important indicator of hookworm infection.

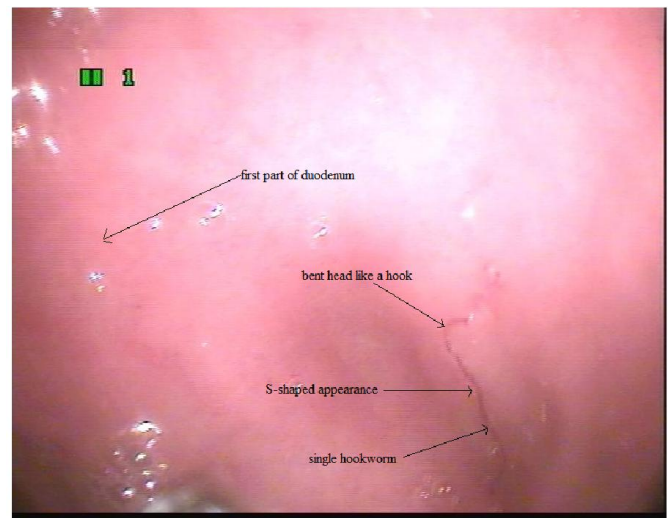


Fig. 1. Single hookworm in duodenum with its bent head like a hook and S-shaped appearance with mild anaemia [haemoglobin 10 g%] without eosinophilia [absolute eosinophil count - 364 cells/cu.mm]

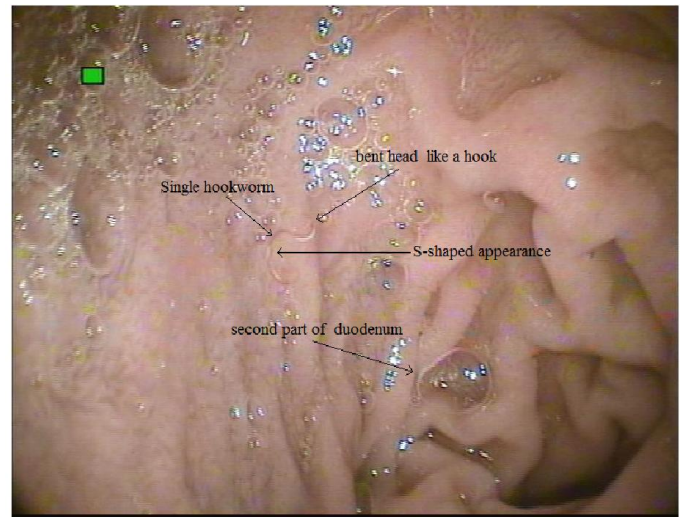


Fig. 2. Single hookworm in duodenum with its bent head and S-shaped appearance in a patient with eosinophilia [absolute eosinophil count - 858 cells/cu.mm]

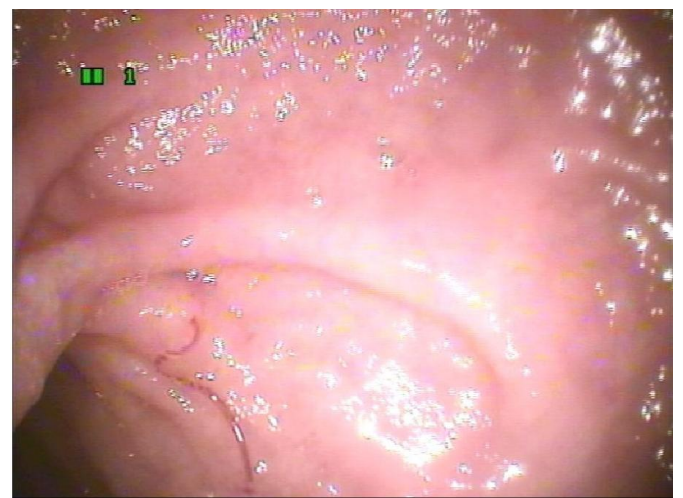

Fig. 3. Single hookworm in duodenum in a patient with its bent head and S-shaped appearance with eosinophilia [absolute eosinophil count - 870 cells/cu.mm]

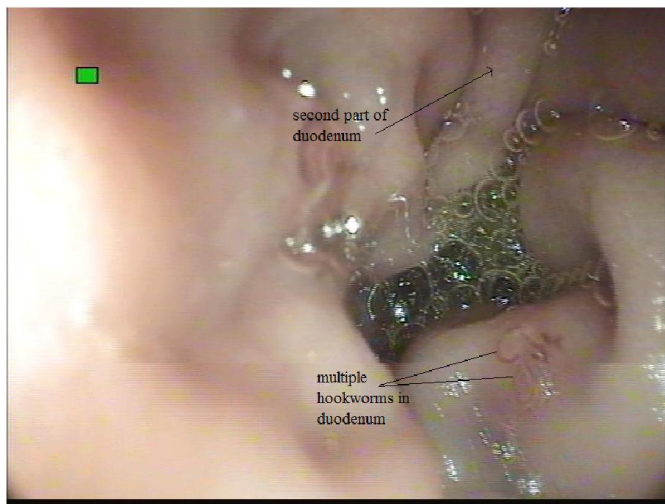


Fig. 4. Multiple hookworms in duodenum in a patient with severe eosinophilia [absolute eosinophil count – 1248 cells/cu.mm]

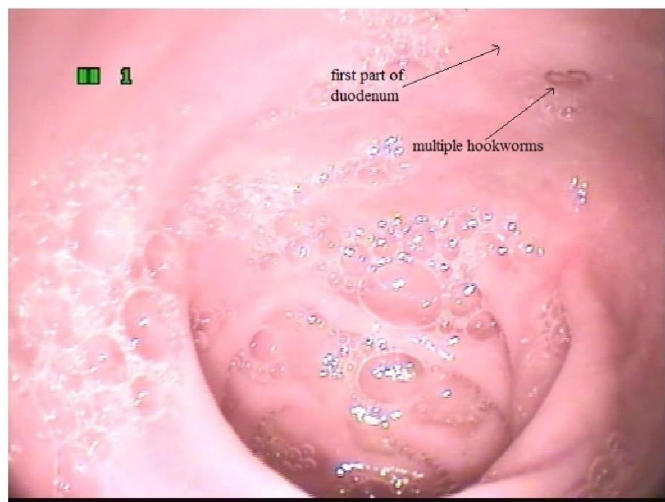

Fig. 5. Multiple hookworms in duodenum in a patient with severe eosinophilia [absolute eosinophil count - 1100cells/cu.mm]

Severe eosinophilia [4patients]

4 out of 10 patients with eosinophilia (40%) had absolute eosinophil count >1000 cells/cu.mm or severe eosinophilia.

a. Severe eosinophilia without anaemia [1patient]

One patient with severe eosinophilia with hookworm infection did not have anaemia (haemoglobin 18g%, absolute eosinophil count - 1000 cells/cu.mm).

b. Severe eosinophilia with anaemia [3 patients]

1. Severe eosinophilia occurring along with mild anaemia was present in one patient in our study (haemoglobin 11.7g%, absolute eosinophil count - 1248 cells/cu.mm). Multiple hookworms in duodenum with severe eosinophilia [absolute eosinophil count - 1248 cells/cu.mm] and with mild anaemia (haemoglobin 11.7g %) seen in this patient is shown in Fig4.

2. Severe eosinophilia with moderate anaemia was present in one patient in our study (haemoglobin 8.6g%, absolute eosinophil count - 1260 cells/cu.mm).
3. Severe eosinophilia with severe anaemia was present in one patient in our study (haemoglobin 3.2g%, absolute eosinophil count - 1100 cells/cu.mm). Multiple hookworms in duodenum seen in a patient with severe eosinophilia (absolute eosinophil count - 1100 cells/cu.mm) is shown in Fig5.
4. Hence severe eosinophilia is an important indicator of hookworm infection.

Conclusion

1. Eosinophilia only peaks at 5 to 9 weeks after the onset of infection, a period that coincides with the appearance of adult hookworms in the intestine.
2. Hence eosinophilia will not be present in the early stage of hookworm infection before 5 to 9 weeks after the onset of infection.
3. Out of 14 patients with hookworms in duodenum, as many as 10 patients with hookworms in duodenum were found to have eosinophilia [71%] as per our study.
4. Hence, eosinophilia occurs commonly in patients with hookworm infection as per our study. Hence eosinophilia is an important indicator of hookworm infection.
5. Severe eosinophilia was found in 4 out of 10 patients with eosinophilia (40%) in our study.
6. Hence severe eosinophilia also occurs in significant number of patients with hookworm infection as seen in our study. Hence severe eosinophilia is an important indicator of hookworm infection.

Acknowledgement

The author sincerely thanks the staff nurses Shenbaghaprabha and Nithya who were assisting the author while doing endoscopy and the staff nurses A.K.Selvi and Nithya for their immense help rendered to the author while conducting this work. The author acknowledges the immense help received from the scholars whose articles are cited and included in references of this manuscript. The author is also grateful to authors / editors / publishers of all those articles, journals and books from where the literature for this article has been reviewed and discussed.

REFERENCES

- Anjum Saeed, Huma Arshad Cheema, Arshad Alvi, Hassan Suleman. Hookworm infestation in children presenting with malena-case series, *Pak J Med Res.*, Oct - Dec 2008;47(4):98-100
- Cedrón-Cheng H, Ortiz C. Hookworm Infestation Diagnosed by Capsule Endoscopy. *J Gastroint Dig Syst*, 2011 S1:003. doi: 10.4172/2161-069X.S1-003
- Heukelbach J, Poggensee G, Winter B, Wilcke T, Kerr-Pontes LR, Feldmeier H. Leukocytosis and blood eosinophilia in a polyparasitised population in north-eastern Brazil. *Trans R Soc Trop Med Hyg.*, 2006 Jan;100(1):32-40. Epub 2005 Sep 23.

- Kato T, Kamoi R, Iida M, Kihara T. Endoscopic diagnosis of hookworm disease of the duodenum *J Clin Gastroenterol.*, 1997 Mar;24(2):100-102
- Kucik CJ, Martin GL, Sortor BV. Common intestinal parasites. *Am Fam Physician.* 2004, Mar 1;69(5):1161-8
- Lawn SDI, Grant AD, Wright SG. Case reports: acute hookworm infection: an unusual cause of profuse watery diarrhoea in returned travelers *Trans R Soc Trop Med Hyg.*, 2003 Jul-Aug;97(4):414-5.
- Lee VJ1, Ong A, Lee NG, Lee WT, Fong KL, Lim PL. Hookworm infections in Singaporean soldiers after jungle training in Brunei Darussalam. *Trans R Soc Trop Med Hyg.*, 2007 Dec;101(12):1214-8. Epub 2007 Oct 4.
- Li ZS1, Liao Z, Ye P, Wu RP. Dancing hookworm in the small bowel detected by capsule endoscopy: a synthesized video. *Endoscopy.* 2007 Feb; 39Suppl 1:E97. Epub 2007 Apr 18.
- Mawhorter SD. Eosinophilia caused by parasites. *Pediatr Ann.*, 1994 Aug;23(8):405, 409-13.
- Maxwell C, Hussain R, Nutman TB, Poindexter RW, Little MD, Schad GA, Ottesen EA. The clinical and immunologic responses of normal human volunteers to low dose hookworm (*Necator americanus*) infection. *Am J Trop Med Hyg.*, 1987 Jul; 37(1):126-34.
- Meltzer E, Percik R, Shatzkes J, Sidi Y, Schwartz E. Eosinophilia among returning travelers: a practical approach, *Am J Trop Med Hyg.*, 2008 May;78(5):702-9.
- Nutman TB, Ottesen EA, Ieng S, Samuels J, Kimball E, Lutkoski M, Zierdt WS, Gam A, Neva FA. Eosinophilia in Southeast Asian refugees: evaluation at a referral center. *J Infect Dis.*, 1987; Feb; 155(2):309-
- Triteeraprapab S, Nuchprayoon I. Eosinophilia, anemia and parasitism in a rural region of northwest Thailand. *Southeast Asian J Trop Med Public Health*, 1998 Sep;29(3): 584-90.
- Verboeket SO1, van den Berk GE., Arends JE, van Dam AP, Peringa J, Jansen RR. Hookworm with hypereosinophilia: atypical presentation of a typical disease. *J Travel Med.*, 2013 Jul-Aug;20(4):265-7
- Wang CH, Lee SC, Huang SS, Chang LC. Hookworm infection in a healthy adult that manifested as severe eosinophilia and diarrhea. *J Microbiol Immunol Infect*, 2011 Dec;44(6):484-7. Epub 2011 May 23.
- Yan SL, Chu YC. Hookworm infestation of the small intestine *Endoscopy* 2007; 39: E162±163.
