



ISSN: 2230-9926

Available online at <http://www.journalijdr.com>

IJDR

International Journal of
DEVELOPMENT RESEARCH

International Journal of Development Research
Vol. 06, Issue, 05, pp. 7732-7740, May, 2016

Full Length Research Article

CHEMOTHERAPEUTIC EFFECT OF CELERY SEED OIL AGAINST HEPATOCELLULAR CARCINOMA INDUCED BY DIETHYLNITROSAMINE IN RATS

¹Omaima A.M. Ahmedy, ¹Mostafa E. El-sayed, ¹Afaf A. Shoka, ¹Hekma A. Abd El-Latif, ¹Ashraf K. Bahgat, ²Somaya Z. Mansour and ³Azza Hassan

¹Department of Pharmacology and Toxicology, Faculty of Pharmacy, Cairo University, Giza, Egypt

²Radiation Biology Department, National Centre for Radiation Research and Technology, Atomic Energy Authority, Cairo, Egypt

³Department of Pathology, Faculty of Veterinary Medicine, Cairo University, Giza, Egypt

ARTICLE INFO

Article History:

Received 21st February, 2016

Received in revised form
24th March, 2016

Accepted 18th April, 2016

Published online 28th May, 2016

Key Words:

Celery,
Hepatocellular Carcinoma,
Diethylnitrosamine,
 α -Fetoprotein,
Immunohistochemistry,

ABSTRACT

Background: Hepatocellular carcinoma (HCC) is one of the world's deadliest cancers and considered as the second main cause of cancer-related mortalities. Therefore, the discovery of effective and safe drugs for chemoprevention and treatment of HCC is of great importance. This study aimed to investigate the potential anticancer activity of celery seed oil (CSO). The serum tumour marker AFP and liver enzymes ALT, AST, γ -GT, ALP, TB, as well as final body weight and liver index are valuable references, widely used in animal studies to diagnose and monitor the development of hepatocarcinogenesis. In the present study, the values of previously mentioned parameters showed sharp increase in diethylnitrosamine (DENA) group as compared with that of the normal control group. Additionally, DENA increased the hepatic expression of the tumour marker hepPar-1 that was immunohistochemically investigated. Moreover, these DENA-induced changes were confirmed histopathologically. CSO treatment significantly decreased the DENA-induced elevated transaminases, γ -GT, AFP, diminished the elevated hepatic expression of hepPar-1 and ameliorated the DENA-induced neoplastic changes histopathologically. However, final body weight, liver index, ALP and TB were improved but did not reach significance. Moreover, the biochemical analysis of hepatic tissues further demonstrated that CSO counteracts DENA-induced oxidative stress through the reduction of MDA and the restoration of antioxidant enzyme catalase. In conclusion, CSO possesses chemotherapeutic activity against HCC in rats which are probably mediated through antioxidant mechanism. Furthermore, CSO can be envisaged for further investigation in efforts to understand the precise mechanism of cytotoxicity.

Copyright © 2016, Omaima A.M. Ahmedy et al. This is an open access article distributed under the Creative Commons Attribution License, which permits unrestricted use, distribution, and reproduction in any medium, provided the original work is properly cited.

INTRODUCTION

Hepatocellular carcinoma (HCC) is a malignant neoplasm of hepatocytes that is considered as the most common primary cancer of liver, one of the world's deadliest cancers and now the second prominent cause of cancer-related mortalities, resulting in 782,000 cases estimated to have occurred in 2012 (El-Serag 2011; Wallace *et al.* 2015). HCC is a distinctive type of cancer that typically arises in the setting of chronic liver disease at a rate dependent upon the complex interaction between the host, disease and environmental factors (Wallace *et al.* 2015).

*Corresponding author: Omaima A.M. Ahmedy,
Department of Pharmacology and Toxicology, Faculty of Pharmacy,
Cairo University, Cairo, Egypt.

Liver cancer has a higher prevalence in patients with HCV-associated cirrhosis than in non-viral aetiologies of chronic liver disease, Egypt has the highest prevalence of HCV in the world and its prevalence is increasing in the last years. Between 1993 and 2002, there was an almost two-fold increase in HCC amongst chronic liver patients in Egypt (Shaker *et al.* 2013). The treatment of hepatocellular carcinoma (HCC) remains a dismal, with 1- and 3-year survival rates of 20% and 5%, respectively and a median survival of 8 months (Befeler and Di Bisceglie 2002). Many treatment options are available for HCC, including surgical resection, orthotopic liver transplantation, percutaneous ethanol injection, radiofrequency thermoablation, chemoembolization and more recently, the use of molecular targeted therapy (sorafenib) (El-Serag *et al.* 2008; Llovet and Bruix 2008).

However there are some obstacles in the implementation of these treatments. Loss of hepatic function is a major important obstacle because most HCC patients suffer from cirrhosis, the loss of hepatic function and the possibility of multicentric neoplastic disease substantially reduces the response to the available treatments. The majority of patients are diagnosed at advanced stages, so an urgent need exists for new systemic therapies (Villanueva and Llovet 2011). Chemically-induced rat liver carcinogenesis, especially one initiated by the environmental carcinogen DENA, has been considered as one of the best-characterized experimental models of carcinogenesis, allowing screening of potential anticancer compounds in various phases of neoplastic development (Chakraborty *et al.* 2007). DENA has been shown to be metabolized to its reactive ethyl metabolites, which interact with DNA causing mutation leading to carcinogenesis (Nakae *et al.* 1997). It is well known that DENA causes the development of HCC through various stages with formation of preneoplastic foci, neoplastic nodules, and ultimately HCC nodules of various sizes (Peto *et al.* 1991). Moreover, DENA has been shown to induce tumors in rodents that closely mimic a subclass of human HCC (Lee *et al.* 2004). It has been postulated that human liver metabolizes nitrosamines in a fashion similar to that of rodent liver, both exhibits similar morphology, genomic alterations and gene expression, despite having differences in the etiology of the disease (Feo *et al.* 2000).

Accumulating evidence has demonstrated that overproduction of reactive oxygen species (ROS) plays a key role in the etiology of hepatocarcinoma, ROS could result in oxidative damage of DNA, which facilitating the formation of hepatocellular carcinomas (Jayaprakash *et al.* 2015). Celery (*Apium graveolens* family *Apiaceae*) locally known as "Karfes" is a biennial or perennial glabrous herb with a heavy aromatic smell, it has been planted for over 3000 years, especially in Egypt. Essential oils, including celery oil, are present in all part of the plant, their content in the roots and leaves may be up to 1%, while in the seeds it may reach 7% (Al-Asmari *et al.* 2014). Celery seedshave been widely used in traditional medicine for the treatment of liver and spleen disorders, jaundice rheumatism, gout, and other inflammatory diseases (Al-Asmari *et al.* 2014). The hepatoprotective activity of the methanolic extract of *A. graveolens* seed has been studied against CCl₄ (Popovic *et al.* 2006) and paracetamol (Singh and Handa 1995) induced liver damage. Moreover, the protective activity of *A. graveolens* was comparable with silymarin and acute toxicity studies on *A. graveolens* extract in rats showed no adverse symptoms. Lethal dose in 50% of rats (LD₅₀) was found to be of 7.5 g/kg body weight clearly suggesting its large margin of safety (Popovic *et al.* 2006).

Although extensive studies have been conducted on the anticarcinogenic properties of celery in several target organs reviewed in (Ren and Lien 1997), liver cancer therapeutic effect of this dietary agent has not been adequately investigated in vivo. In a previous study, pretreatment of rats with celery methanolic extract of showed chemopreventive effects against Solt Farber protocol of hepatocarcinogenesis (Sultana *et al.* 2005).

On the other hand, no reports have described the chemotherapeutic effect of CSO on established hepatocellular carcinoma in rodents. In this study, we analysed the therapeutic effect of CSO on the hepatic neoplastic changes in rats, employing a long term DENA administration carcinogenic model.

MATERIALS AND METHODS

Chemicals

Diethylnitrosamine (DENA) was purchased from Sigma (St. Louis, MO, USA) and celery seed oil was obtained from a commercial source (Hashem Brothers for essential oils & aromatic products, Benisuef, Egypt) under supervision of Ministry of Health of Egypt. All other chemicals used were of the highest purity and analytical grade.

Animals and diet

Male Wistar albino rats weighing 90-120 g were used in the present study. They were obtained from the breeding colony maintained at the animal house of the Nile Pharmaceuticals Company (Cairo, Egypt). They were allowed an acclimatization period for at least one week prior to testing. Animals were kept under controlled environmental conditions; room temperature (24-27°C), constant humidity (60 ± 10%), with alternating 12 h light and dark cycles. Standard pellet diet and water were allowed ad libitum. All animals' procedures were performed in accordance with the ethical procedures and policies approved by the Ethics Committee of Faculty of Pharmacy, Cairo University and complies with the *Guide for the Care and Use of Laboratory Animals published by the US National Institutes of Health (NIH Publication No. 85-23, revised 1996)*.

Experimental design

After a period of adaptation, all animals except the normal group were intraperitoneally injected with DENA (20 mg/kg) five times weekly for 6 consecutive weeks to induce HCC (Ahmed *et al.* 2013). Animals were randomly assigned into a normal control group and diethyl nitrosamine-induced HCC group (DENA). After tumour induction (6 weeks), the DENA group was distributed into 2 groups, a control HCC group and CSO treated group, each composed of 8-12 rats. CSO treatment was carried out by the daily oral administration of CSO (300 mg/kg) for four consecutive weeks from the 7th week until the end of the 10th week (Baananou *et al.* 2013). Body and liver weights were determined at the end of the experimental period (10 weeks).

Blood sampling and serum preparation

At the end of the treatment period, blood samples were taken from retro-orbital sinus of rats under ether an aesthesia. Blood samples were allowed to clot at room temperature then serum was separated by centrifugation of blood at 3000 rpm for 15 minutes using a centrifuge (Hettich universal 32A, Germany). Each sample was divided into several aliquots, for the estimation of the biochemical parameters and stored at -80°C until analysis is performed.

Tissue sampling

Animals were then sacrificed by cervical dislocation, livers were carefully and rapidly excised. The removed livers were washed with cold normal saline and dried on filter papers then weighed for the determination of liver index. Liver index percentage was determined ($= \text{liver weight} / \text{body weight} \times 100$). Samples of the liver, from different lobes were homogenized in ice-cold saline, using a homogenizer (Heidolph DiAx 900, Germany), to prepare 20% homogenate. The prepared homogenate was divided into several aliquots that were stored at -80°C until assayed later for estimation of the chosen biochemical parameters. Samples from the remaining parts were fixed with 10% formaldehyde for immunohistochemical and histopathological examination. The dead bodies were frozen till incineration.

Estimation of Biochemical Parameters

Estimation of oxidative stress parameters

Liver homogenate was used for determination of thiobarbituric acid reactive substances (TBARS), measured as MDA (Mihara and Uchiyama 1978), reduced glutathione (GSH) (Beutler *et al.* 1963) and catalase (Sinha 1972).

Estimation of liver function tests

Serum alanine transaminase (ALT) and aspartate aminotransferase (AST) were determined according to the method of Reitman and Frankel (Reitman and Frankel 1957). Serum alkaline phosphatase (ALP) was assessed according to the method of Klein *et al.* (Klein *et al.* 1960), serum total bilirubin (TB) was evaluated using the method of Jendrassik and Grof (Jendrassik and Grof 1938), and serum γ -glutamyltransferase (γ -GT) was evaluated according to the method of Szasz (Szasz 1969).

Estimation of serum α -fetoprotein

α -fetoprotein (AFP) in serum was assessed using commercial enzyme-linked immunosorbent assay (ELISA) kits (Monobind, USA)

Histopathological examination of liver tissue

Parts of the isolated liver tissue obtained from each animal were fixed in 10% formalin solution, dehydrated in ascending grades of alcohol and embedded in paraffin wax. Sections of 5 μm thickness were taken, stained with hematoxylin and eosin (H&E) and examined under light microscope.

Immunohistochemical analysis of liver tissue

Five μm thick sections were prepared from formalin fixed livers of different animal groups and immunohistochemistry was performed. Sections were placed on positively charged slides, deparaffinised, rehydrated and endogenous peroxidase activity was blocked with H_2O_2 in methanol. Sections were pre-treated in citrate buffer (pH 6.0) in a microwave. The sections were incubated with the rabbit polyclonal antibody anti-hepatocyte paraffin 1 (hepPar-1) (Thermo Scientific, USA). The sections were incubated with biotinylated goat anti-polyvalent, then with streptavidin peroxidase and finally

with diaminobenzidine plus chromogen. The slides were visualized under light microscope and the extent of cell immunopositivity was assessed. The number of immunopositive cells was counted in 10 separate microscopic fields/animal, the results were expressed as percentage of total cell per field and the mean value for each slide was obtained, then the mean \pm S.E.M. was calculated for each group ($n=5$).

Statistical analysis

Data are expressed as means \pm standard error (S.E.M). Comparisons between means were carried out using one way analysis of variance (ANOVA) test followed by Tukey-Kramer multiple comparison's test. For all statistical tests, the level of significance was fixed at $p < 0.05$. GraphPad Prism® software package, version 6 (GraphPad Software, Inc., USA) was used to carry out all statistical tests.

RESULTS

Effects of celery seed oil on final body weight and liver index in DENA-induced HCC in rats

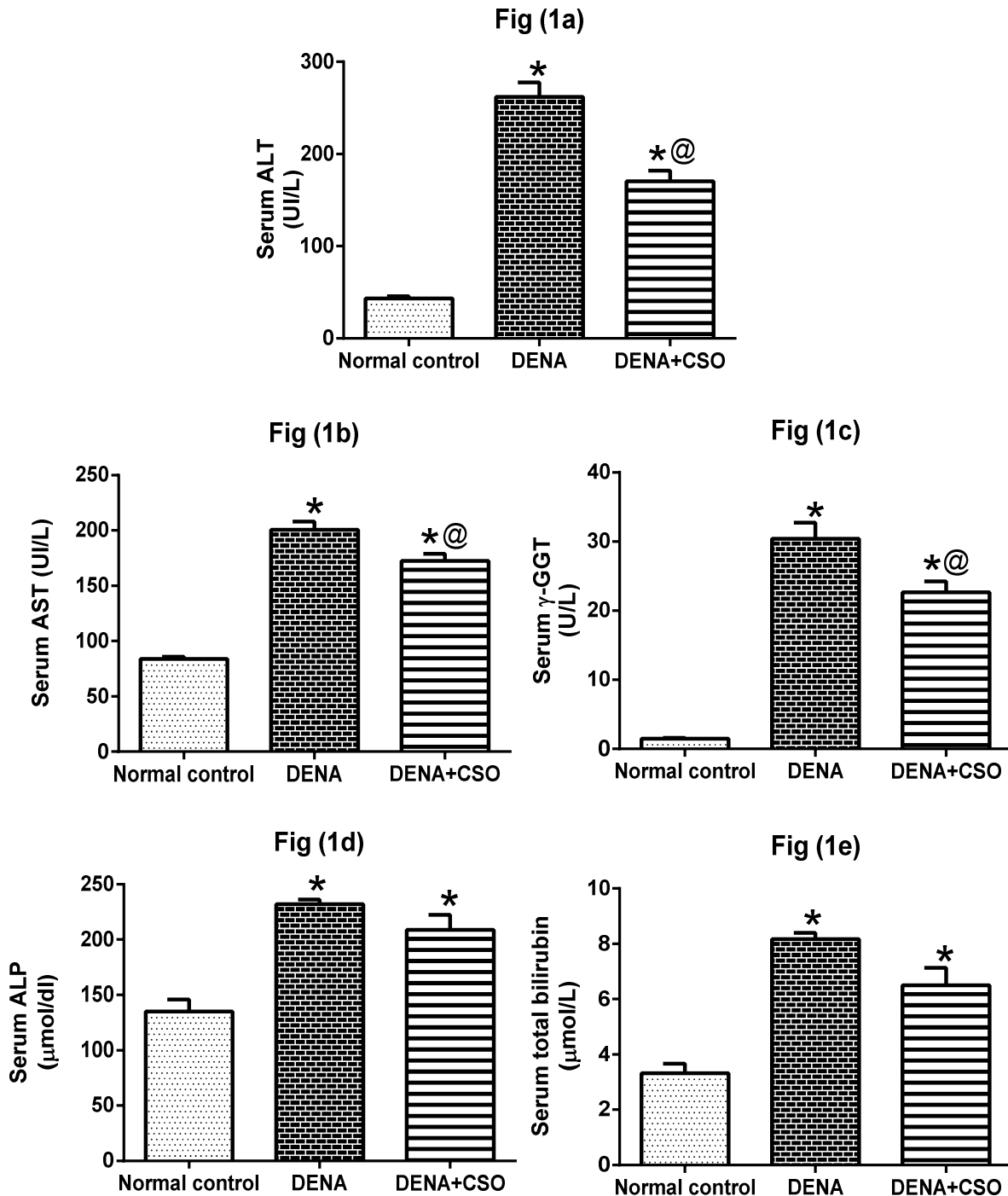
As presented in Table (1) there was an increase in the final body weight in all groups although the extent was variable. Rats in the normal control group showed marked increase in the final body weight, signs of good health, and high-quality fur were also observed. At the termination of the experiment (at the 12th week), rats in the DENA-induced HCC group displayed signs of poor health, including apathy, reduced activity and significant decrease in final body weight as compared to the normal control group (24.57%). Oral administration of CSO for four weeks insignificantly increased the final body as compared with DENA group (8.07%). Moreover, a marked increase in the liver index was noticed in the DENA group as compared to normal control (58.17%), treatment with CSO slightly decreased the liver index as compared to DENA group (21.28%).

Effect of celery seed oil on liver oxidant status in DENA-induced HCC in rats

Table (2) depicts that rats subjected to DENA exhibited a 4 fold elevation in liver TBARS content, a hallmark of lipid peroxidation, as compared to the normal control group. This was significantly mitigated by CSO administration relative to untreated HCC rats (46.86%). In parallel a marked depletion of GSH, the key non enzymatic tissue antioxidant, was observed in DENA-induced HCC group (29.65%). This metabolite was partially replenished by CSO as compared to DENA group (20.79%). Likewise, DENA-induced HCC animals demonstrated a pronounced decrease in catalase activity as compared to the normal control group (44.34%). CSO oral administration for 4 weeks after HCC induction remarkably increased the hepatic catalase activity in comparison with DENA-induced HCC rats (42.37%).

Effect of celery seed oil on serum liver enzymes in DENA-induced HCC in rats

As shown in Figure 1(a, b, c, d & e), DENA significantly increased the activity of ALT, AST, γ -GGT and ALP and augmented the serum TB level as compared to the normal control group.



DENA=diethylnitrosamine, CSO=celery seed oil, HCC= hepatocellular carcinoma, AST=aspartate aminotransferase, ALT= alanine aminotransferase, γ -GT=gamma glutamyltransferase, ALP= alkaline phosphatase and TB=total bilirubin.

Values are expressed as means \pm S.E.M. (n=6-8).

The significance of the difference between means was tested by ANOVA followed by Tukey-Kramer multiple comparisons test.

* Significantly different from control, @ Significantly different from DENA at $p < 0.05$.

Figure (1). Effect of celery seed oil (300 mg/kg) on serum (a) ALT, (b) AST, (c) γ -GT, (d) ALP and (e) TB in DENA-induced HCC in rats

CSO treatment opposed the injurious effect of DENA and significantly decreased the activity of ALT, AST and γ -GGT as compared to DENA group. However, ALP and TB were also reduced, but this was not statistically significant relative to DENA group.

Effect of celery seed oil on serum tumour marker α -fetoprotein in DENA-induced HCC in rats

Figure 2 depicts the level of the tumour marker (AFP) in serum as assessed by an ELISA assay.

Table 1. Effect of celery seed oil (300 mg/kg) on final body weight and liver index of rats exposed to diethylnitrosamine

Parameters Groups	Initial body weight (gm)	Final body weight (gm)	Liver index (%)
Normal control	98.1± 7.3	211.67±10.11	3.06±0.23
(DENA) (20mg/kg, i.p.)	101.62±8.2	159.67* ±11.21	4.84* ±0.35
DENA + CSO (300mg/kg/p.o.)	97.6±5.6	172.55±9.33	3.81 ±0.29

DENA=diethylnitrosamine, CSO=celery seed oil.

Values are expressed as means±S.E.M. (n=6-8).

The significance of the difference between means was tested by ANOVA followed by Tukey Kramer multiple comparisons test.

* Significantly different from control, @ Significantly different from DENA at p< 0.05.

Table 2. Effect of celery seed oil (300 mg/kg) on oxidative stress biomarkers in liver of rats exposed to diethylnitrosamine

Parameters Groups	TBARS (nmol/g tissue)	GSH (mg/g tissue)	Catalase (nmol/g tissue)
Normal control	50.78±5.26	7.52±0.40	0.106±0.0033
(DENA) (20mg/kg, i.p.)	212.27*±10.12	5.29*±0.08	0.059*±0.0043
DENA + CSO (300mg/kg/p.o.)	112.81*±7.90	6.39±0.47	0.084*±0.0049

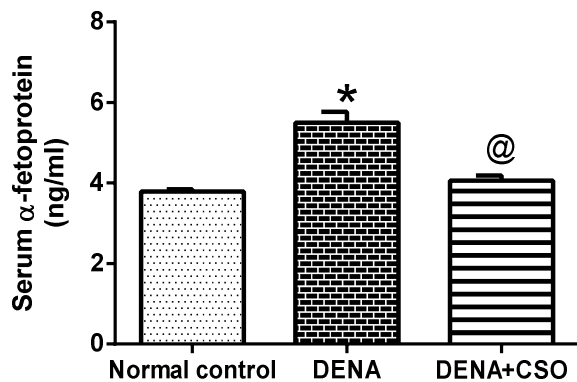
DENA=diethylnitrosamine, CSO=celery seed oil.

Values are expressed as means±S.E.M. (n=6-8).

The significance of the difference between means was tested by ANOVA followed by Tukey- Kramer multiple comparisons test.

* Significantly different from control, @ Significantly different from DENA at p< 0.05.

While in the DENA-induced HCC control group, there was a marked increase in AFP level compared to the normal control group, the levels of AFP were significantly reduced in the CSO treated group compared to the DENA group.



DENA=diethylnitrosamine, CSO=celery seed oil, HCC= hepatocellular carcinoma.

Values are expressed as means±S.E.M. (n= 6-8).

The significance of the difference between means was tested by ANOVA followed by Tukey Kramer multiple comparisons test.

* Significantly different from control, @ Significantly different from DENA at p< 0.05.

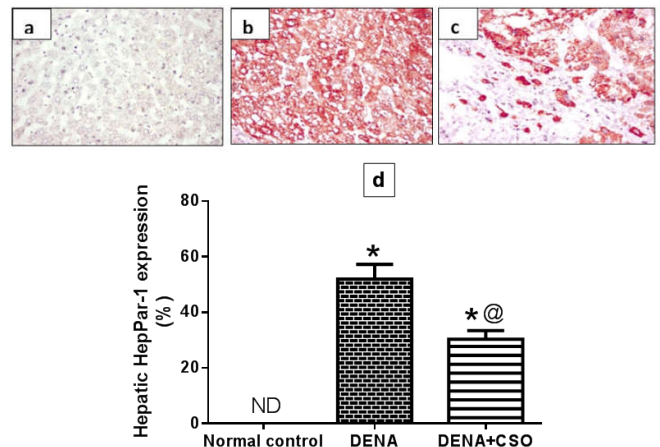
Figure 2. Effect of celery seed oil (300mg/kg) on serum tumour marker α-fetoprotein in DENA-induced HCC in rats

Effect of celery seed oil on the hepatic expression the of hepPar-1 in DENA-induced HCC in rats

As shown in figure.3 (a, b, c & d) the hepatic expression of the tumour marker hepPar-1 was not detectable in the normal control group. DENA administration displayed a remarkable increase in the hepatic expression of hepPar-1 relative to the normal control group. Treatment of the rats given DENA with CSO significantly reduced the hepatic expression of hepPar-1 relative to DENA group.

Effect of celery seed oil on the histopathology of rat liver

Macroscopic and microscopic features of the liver were evaluated in all animals. As expected, in normal control group without DENA treatment, no tumours were observed and the liver histology showed a normal appearance. Multiple white nodules were macroscopically observed in the groups treated with DENA and DENA+CSO.

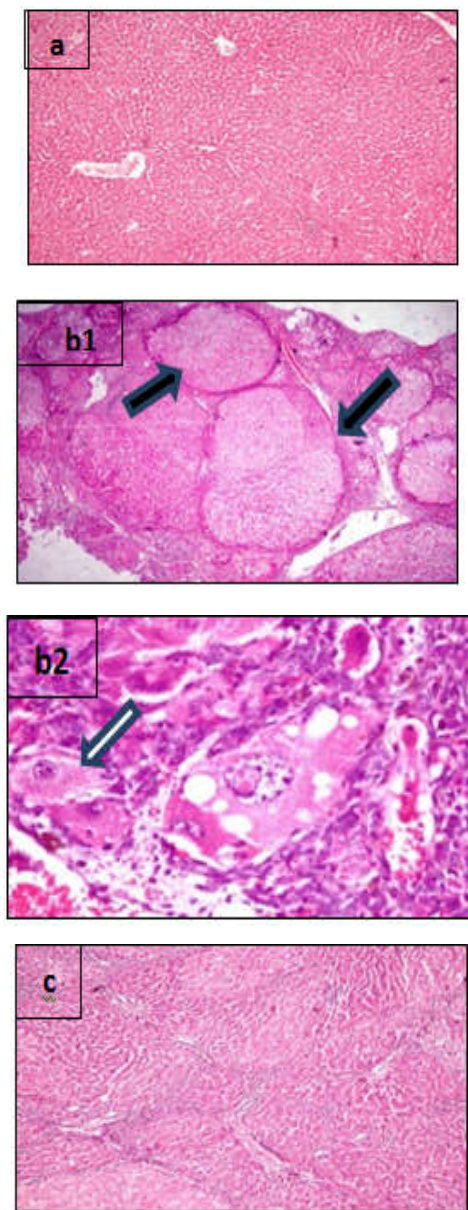


DENA=diethylnitrosamine, CSO=celery seed oil, HCC= hepatocellular carcinoma and HepPar-1= hepatocyte paraffin ND = non detectable Values are expressed as means±S.E.M. (n=6-8).

The significance of the difference between means was tested by ANOVA followed by Tukey Kramer multiple comparisons test.

* Significantly different from control, @ Significantly different from DENA at p< 0.05.

Figure 3. Effect of celery seed oil (300mg/kg) on hepPar-1 expression in DENA-induced HCC in rats Representative photomicrograph of immunohistochemical staining of hepPar-1 in rat liver from: (A, 400x) normal control group showing no expression of hepPar-1; (B, 400x) DENA-induced hepatocellular carcinoma showing a significant increase in hepPar-1 immunoreactivity in the cytoplasm of hepatocytes; (C, 400x) DENA + CSO group showing a significant reduction in hepPar-1 immunostaining. Brown colour indicates hepPar-1 positivity; (D) percentage expression of hepPar-1



DENA=diethylnitrosamine, CSO=celery seed oil, HCC= hepatocellular carcinoma

Figure 4. Photomicrographs of rat liver (H&E, 100×) from: (a) control group showing normal hepatic architecture; (b1, 100x and b2, 400x) hepatocellular carcinoma group without CSO treatment showing the multinodular pattern of HCC (b1, black arrow), distortion of normal architecture and irregularly-shaped hepatocytes. Many cells show dysplastic changes in the form of enlarged nuclei accompanied by greater nuclear/cytoplasmic ratio (b2, white arrows), polymorphic cells showing different shapes and sizes. (c) CSO treated hepatocellular carcinoma rats group showing a histological picture comparable to that of the control group with minimal dysplasia of hepatocytes and numerous altered foci.

In the histological analysis, the white nodules were demonstrated to be HCC. Liver of control rats showed normal hepatic parenchyma with preserved architecture (fig.4, a), whereas those of DENA intoxicated group revealed multi nodular pattern of hepatocellular carcinoma. The malignant hepatocytes were arranged either in irregular trabeculae of three or more cells thick or solid compact pattern with frequent mitotic activity (fig.4, b1).

The tumour cells are polygonal in shape with round vesicular nuclei and prominent nucleoli as well as nuclear atypia and increased nuclear/cytoplasmic ratio were frequently demonstrated (fig.4, b2). Consistent with the microscopic findings, the HCC nodular area was significantly modified by CSO treatment (fig.4, c).

DISCUSSION

Hepatocellular carcinoma (HCC) constitutes about 85% of primary liver cancer and is a highly aggressive cancer associated with a high mortality rate because of poor or ineffective treatments (El-Serag and Rudolph 2007). Therefore, development of novel, safe and effective chemotherapeutic agents for the treatment of HCC has always been an attractive area of investigation. The present study was designed to determine whether celery seed oil (CSO) could afford an anticancer effect when administered after HCC induction. To the best of our knowledge, this is the first study about the chemotherapeutic activity of CSO against chemically-induced HCC in rats.

Celery has been used as a food, and at various times both the whole plant and the seeds have been consumed as a medicine, the seeds extract of celery are used to treat bronchitis, asthma, liver and spleen diseases (Singh and Handa 1995b). Moreover, hepatoprotective effect (Ahmed *et al.* 2002), inactivation of toxic metabolites in liver (El-Shinnawy 2015), chemopreventive (Sultana *et al.* 2005), anti-inflammatory (Atta and Alkofahi 1998), antioxidant, cyclooxygenase- and topoisomerase-inhibitory activity (Momin and Nair 2002) have been observed in celery seed extracts. The present study demonstrated that treatment with CSO for four weeks provided a significant chemotherapeutic activity against HCC induced by DENA in rats. Chemically-induced liver carcinogenesis in rats, especially one initiated by the environmental carcinogen DENA, has been considered as one of the best-characterized experimental models of carcinogenesis, allowing screening of potential anticancer compounds in various phases of neoplastic development (Chakraborty *et al.* 2007). DENA has been shown to induce tumours in rodents that closely mimic a subclass of human HCC (Lee *et al.* 2004). The present results showed that DENA long term administration significantly increased the tumour serum AFP and increased the expression of hepPar-1 level in the hepatocytes which supports the hepatocarcinogenicity of DENA as an experimental model. These results are in agreement with other studies regarding the hepatocarcinogenic effect of the used DENA dose in rats (Ahmed *et al.* 2013; Song *et al.* 2013).

In the present study, the first observation with DENA administration was an undesirable decrease in the final body weight accompanied by a significant increase in liver index, an effect that could be attributed to the hepatotoxic and hepatocarcinogenic effects of DENA (Sayed-Ahmed *et al.* 2010). However CSO treated HCC rats showed an improvement that could be attributed to the hepatoprotective effect of CSO. Liver is the main site of DENA metabolism. The generation of ROS in the liver is recognized as an important contributor in DENA-induced carcinogenic effects (Shaarawy *et al.* 2009).

ROS are continuously generated *in vivo* as a result of DENA administration causing oxidative stress that seriously damage the biological systems by injuring tissues, altering biochemical compounds, causing chromosomal instability, eroding cell membranes and mutation, which are involved in all steps of carcinogenesis, i.e. initiation, promotion and progression (Karbownik *et al.* 2001). MDA is an end product of lipid peroxidation, the content of MDA directly reflects the free radical levels and is an important indicator of oxidative liver injury (Sayed-Ahmed *et al.* 2010). In the present investigation, we found that the level of MDA was significantly elevated by DENA. In agreement with our finding, Jayaprakash *et al.* 2015 reported that animals treated with DENA showed increased lipid peroxide formation and cell membrane damage and decreased levels of antiperoxidative enzymes. However, the animals treated with CSO displayed a manifest reduction in the level of MDA compared with that in DENA group. The observed reduction in the level of MDA in CSO treated animals was presumably due to the increase of anti-oxidative capabilities (Li *et al.* 2014).

For the purpose of preventing cellular damage induced by ROS, the organism has a lot of antioxidative defence system, including the non-enzymatic (mainly GSH) and enzymatic antioxidant defences such as catalase. GSH plays an important role in maintaining the normal reduced state of cells and counteracting the harmful effects of oxidative stress (Ramakrishnan *et al.* 2006). GSH can effectively scavenge free radicals and other oxygen species through non-enzymatic and enzymatic process by conjugation with GPx and GST (Saydam *et al.* 1997). Catalase acts as supporting antioxidant enzymes by transforming H_2O_2 to H_2O , thereby providing protection against ROS (Ramakrishnan *et al.* 2006). In the present study, DENA resulted in significant decreases in the level of GSH and the activity of the antioxidant enzyme catalase. The depletion of GSH content and the reduction in the activity of this enzyme may be a result of excessive MDA production during DENA metabolism. In the current investigation, administration of CSO partially counteracted the effects of DENA, which suggests that the elevation in catalase activity and the slight elevation in of GSH might be one of the important mechanisms for CSO protection against DENA-induced HCC.

ALT, AST, ALP, γ -GT and AFP are valuable references, widely used in animal studies to diagnose and monitor the development of hepatocarcinogenesis (Liu *et al.* 2006). The increase in serum ALT, AST, γ -GT, ALP and TB indicated that DENA may induce acute liver injury. During carcinogenesis, these enzymes could be used as biomarkers of HCC response to therapy. As seen in the present study, treatment with CSO significantly reduced serum ALT, AST and γ -GGT levels compared to DENA-treated rats, which suggests that CSO may be a promising protective and therapeutic agent against the DENA-induced liver toxicity. AFP, a tumour-associated fetal protein, has long been employed as a reference serum tumour biomarker to validate the diagnosis and monitor disease progression in human (Abelevet *et al.* 1963; Liu *et al.* 2006). However, normal physiological-levels of AFP are observed in approximately one third of HCC cases.

Furthermore, a number of HCC positive patients show AFP levels less than the threshold value of 400 ng/mL. These factors make an AFP-based diagnosis of HCC far from reliable. However, in animal models it is one of the useful markers to analyse HCC serum level of AFP, which is dependent on regimen and in general AFP level of liver is related to growth rate, size and so on (Johnson 2001; Sell 2008). Moreover, high diagnostic accuracy indices have been reported when AFP is combined with other biomarkers such as γ -GGT (Khatab *et al.* 2015). In our study, there was a marked increase in serum AFP level in DENA-induced HCC control group animals. This finding is consistent with previous report that showed that DENA-induced HCC in rats led to an increase in serum AFP (Song *et al.* 2013). Treatment with CSO significantly reduced serum AFP level, suggesting that CSO might reduce lesion of the liver and delay the DEN-induced HCC in rats. Immunohistochemical staining is a useful tool for diagnosis of HCC from other malignancies, however, the use of this technique was limited due to the lack of a reliable positive marker for HCC. A recent antibody designated hepPar-1 (hepatocyte paraffin 1) using formalin-fixed paraffin embedded liver tissue samples was developed by Wennerberg and co-workers (1993).

HepPar-1 antibody recognizes an antigen thought to be specific for hepatocyte mitochondria, several reports demonstrated that hepPar-1 is a very sensitive and specific positive immunohistochemical marker for HCC (Minervini *et al.* 1997; Murakata *et al.* 2000), and about 95% of HCCs showed staining at any level of differentiation (Fan *et al.* 2003). The present study revealed that DENA markedly augmented the hepatic expression of the immunomarker hepPar-1, thus confirming the hepatocarcinogenicity of DENA. CSO treatment significantly reduced this overexpression in the liver cells of rats received DENA indicating the beneficial anti-carcinogenic effect of CSO in HCC. The DENA-induced neoplastic histopathological changes observed in the current study are in harmony with previous reports (Goldfarb *et al.* 1983; Pascale *et al.* 1993). Moreover, the observed CSO-induced improvement in the histopathological findings confirms the anticarcinogenic effect of CSO against DENA-induced HCC and the efficacy of CSO may be attributed to the antiproliferative and hepatoprotective effects of its active constituents (Fotsis *et al.* 1997).

Conclusion

In conclusion, data from this study suggest that CSO treatment provided a significant chemotherapeutic effect in rats with chemically induced HCC. This will encourage the conduction of further studies to determine more precise mechanisms underlying this effect. Moreover, these findings will open new perspectives for the use of CSO alone or in combination with other chemotherapeutic agents or natural chemo preventive compounds to prevent, slow or reverse the incidence of liver cancer which is one of the most common malignancies worldwide.

Conflict of interest

There are no conflicts to disclose.

REFERENCE

- Abelev, G. I., Perova, S. D., Khramkova, N. I., Postnikova, Z. A. and IRLIN, I. S. 1963. Production of embryonal alpha-globulin by transplantable mouse hepatomas. *Transplantation*1, pp. 174-180.
- Ahmed, B., Alam, T., Varshney, M. and Khan, S. A. 2002. Hepatoprotective activity of two plants belonging to the Apiaceae and the Euphorbiaceae family. *J Ethnopharmacol.*79(3), pp. 313-316.
- Ahmed, H. H., Shousha, W. G., El-Mezayen, H. A., Ismaiel, N. N. and Mahmoud, N. S. 2013. In vivo antitumor potential of carvacrol against hepatocellular carcinoma in rat model. *World Journal of Pharmacy and Pharmaceutical Sciences* 2(5), pp. 2367-2396.
- Al-Asmari, A. K., Al-Elaiwi, A. M., Athar, M. T., Tariq, M., Al, E. A. and Al-Asmary, S. M. 2014. A review of hepatoprotective plants used in Saudi traditional medicine. *Evid. Based. Complement Alternat. Med.*2014, pp. 842-890.
- Atta, A. H. and Alkofahi, A. 1998. Anti-nociceptive and anti-inflammatory effects of some Jordanian medicinal plant extracts. *J Ethnopharmacol.*60(2), pp. 117-124.
- Baananou, S., Bouftira, I., Mahmoud, A., Boukef, K., Marongiu, B. and Boughattas, N. A. 2013. Antiulcerogenic and antibacterial activities of *Apium graveolens* essential oil and extract. *Nat. Prod. Res.*27(12), pp. 1075-1083.
- Befeler, A. S. and Di Bisceglie, A. M. 2002. Hepatocellular carcinoma: diagnosis and treatment. *Gastroenterology*122(6), pp. 1609-1619.
- Beutler, E., Duron, O. and Kelly, B. M. 1963. Improved method for the determination of blood glutathione. *J Lab Clin. Med.*61, pp. 882-888.
- Chakraborty, T., Chatterjee, A., Rana, A., Dhachinamoorthi, D., Kumar, P. A. and Chatterjee, M. 2007. Carcinogen-induced early molecular events and its implication in the initiation of chemical hepatocarcinogenesis in rats: chemopreventive role of vanadium on this process. *Biochim. Biophys. Acta*1772(1), pp. 48-59.
- El-Serag, H. B. 2011. Hepatocellular carcinoma. *N. Engl. J Med.*365(12), pp. 1118-1127.
- El-Serag, H. B. and Rudolph, K. L. 2007. Hepatocellular carcinoma: epidemiology and molecular carcinogenesis. *Gastroenterology*132(7), pp. 2557-2576.
- El-Serag, H. B., Marrero, J. A., Rudolph, L. and Reddy, K. R. 2008. Diagnosis and treatment of hepatocellular carcinoma. *Gastroenterology*134(6), pp. 1752-1763.
- El-Shinnawy, N. A. 2015. The therapeutic applications of celery oil seed extract on the plasticizer di(2-ethylhexyl) phthalate toxicity. *Toxicol. Ind. Health*31(4), pp. 355-366.
- Fan, Z., van de Rijn, M., Montgomery, K. and Rouse, R. V. 2003. Hep par 1 antibody stain for the differential diagnosis of hepatocellular carcinoma: 676 tumors tested using tissue microarrays and conventional tissue sections. *Mod. Pathol.*16(2), pp. 137-144.
- Feo, F., Pascale, R. M., Simile, M. M., De Miglio, M. R., Muroli, M. R. and Calvisi, D. 2000. Genetic alterations in liver carcinogenesis: implications for new preventive and therapeutic strategies. *Crit Rev. Oncog.*11(1), pp. 19-62.
- Fotsis, T., Pepper, M. S., Aktas, E., Breit, S., Rasku, S., Adlercreutz, H., Wahala, K., Montesano, R. and Schweigerer, L. 1997. Flavonoids, dietary-derived inhibitors of cell proliferation and in vitro angiogenesis. *Cancer Res.*57(14), pp. 2916-2921.
- Goldfarb, S., Pugh, T. D., Koen, H. and He, Y. Z. 1983. Preneoplastic and neoplastic progression during hepatocarcinogenesis in mice injected with diethylnitrosamine in infancy. *Environ. Health Perspect.*50, pp. 149-161.
- Jayaprakash, R., Ramesh, V., Sridhar, M. P. and Sasikala, C. 2015. Antioxidant activity of ethanolic extract of *Tinospora cordifolia* on N-nitrosodiethylamine (diethylnitrosamine) induced liver cancer in male Wistar albino rats. *J Pharm. Bioallied. Sci.*7(Suppl 1), S40-S45.
- Jendrassik, L. and Grof, P. 1938. *Biochem. Z.*(297), pp. 81-89.
- Johnson, P. J. 2001. The role of serum alpha-fetoprotein estimation in the diagnosis and management of hepatocellular carcinoma. *Clin. Liver Dis.*5(1), pp. 145-159.
- Karbownik, M., Lewinski, A. and Reiter, R. J. 2001. Anticarcinogenic actions of melatonin which involve antioxidative processes: comparison with other antioxidants. *Int. J Biochem. Cell Biol.*33(8), pp. 735-753.
- Khatab, M., Fouad, M. and Ahmed, E. 2015. Role of biomarkers in the prediction and diagnosis of hepatocellular carcinoma. *World J Hepatol.*7(23), pp. 2474-2481.
- Klein, B., Read, P. A. and Babson, A. L. 1960. Rapid method for the quantitative determination of serum alkaline phosphatase. *Clin. Chem.*6, pp. 269-275.
- Lee, J. S., Chu, I. S., Mikaelyan, A., Calvisi, D. F., Heo, J., Reddy, J. K. and Thorgeirsson, S. S. 2004. Application of comparative functional genomics to identify best-fit mouse models to study human cancer. *Nat. Genet.*36(12), pp. 1306-1311.
- Li, P., Jia, J., Zhang, D., Xie, J., Xu, X. and Wei, D. 2014. In vitro and in vivo antioxidant activities of a flavonoid isolated from celery (*Apium graveolens* L. var. dulce). *Food Funct.*5(1), pp. 50-56.
- Liu, J. G., Zhao, H. J., Liu, Y. J. and Wang, X. L. 2006. Effect of selenium-enriched malt on hepatocarcinogenesis, paraneoplastic syndrome and the hormones regulating blood glucose in rats treated by diethylnitrosamine. *Life Sci.*78(20), pp. 2315-2321.
- Llovet, J. M. and Bruix, J. 2008. Novel advancements in the management of hepatocellular carcinoma in 2008. *J Hepatol.*48 Suppl 1, S20-S37.
- Mihara, M. and Uchiyama, M. 1978. Determination of malonaldehyde precursor in tissues by thiobarbituric acid test. *Anal. Biochem.*86(1), pp. 271-278.
- Minervini, M. I., Demetris, A. J., Lee, R. G., Carr, B. I., Madariaga, J. and Nalesnik, M. A. 1997. Utilization of hepatocyte-specific antibody in the immunocytochemical evaluation of liver tumors. *Mod. Pathol.*10(7), pp. 686-692.
- Momin, R. A. and Nair, M. G. 2002. Antioxidant, cyclooxygenase and topoisomerase inhibitory compounds from *Apium graveolens* Linn. seeds. *Phytomedicine.*9(4), pp. 312-318.
- Murakata, L. A., Ishak, K. G. and Nzeako, U. C. 2000. Clear cell carcinoma of the liver: a comparative immunohistochemical study with renal clear cell carcinoma. *Mod. Pathol.*13(8), pp. 874-881.

- Nakae, D., Kobayashi, Y., Akai, H., Andoh, N., Satoh, H., Ohashi, K., Tsutsumi, M. and Konishi, Y. 1997. Involvement of 8-hydroxyguanine formation in the initiation of rat liver carcinogenesis by low dose levels of N-nitrosodiethylamine. *Cancer Res.*57(7), pp. 1281-1287.
- Pascale, R. M., Simile, M. M. and Feo, F. 1993. Genomic abnormalities in hepatocarcinogenesis. Implications for a chemopreventive strategy. *Anticancer Res.*13(5A), pp. 1341-1356.
- Peto, R., Gray, R., Brantom, P. and Grasso, P. 1991. Dose and time relationships for tumor induction in the liver and esophagus of 4080 inbred rats by chronic ingestion of N-nitrosodiethylamine or N-nitrosodimethylamine. *Cancer Res.*51(23 Pt 2), pp. 6452-6469.
- Popovic, M., Kaurinovic, B., Trivic, S., Mimica-Dukic, N. and Bursac, M. 2006. Effect of celery (*Apium graveolens*) extracts on some biochemical parameters of oxidative stress in mice treated with carbon tetrachloride. *Phytother. Res.*20(7), pp. 531-537.
- Ramakrishnan, G., Raghavendran, H. R., Vinodhkumar, R. and Devaki, T. 2006. Suppression of N-nitrosodiethylamine induced hepatocarcinogenesis by silymarin in rats. *Chem. Biol. Interact.*161(2), pp. 104-114.
- Reitman, S. and Frankel, S. 1957. A colorimetric method for the determination of serum glutamic oxalacetic and glutamic pyruvic transaminases. *Am. J Clin. Pathol.*28(1), pp. 56-63.
- Ren, S. and Lien, E. J. 1997. Natural products and their derivatives as cancer chemopreventive agents. *Prog. Drug Res.*48, pp. 147-171.
- Saydam, N., Kirb, A., Demir, O., Hazan, E., Oto, O., Saydam, O. and Guner, G. 1997. Determination of glutathione, glutathione reductase, glutathione peroxidase and glutathione S-transferase levels in human lung cancer tissues. *Cancer Lett.*119(1), pp. 13-19.
- Sayed-Ahmed, M. M., Aleisa, A. M., Al-Rejaie, S. S., Al-Yahya, A. A., Al-Shabanah, O. A., Hafez, M. M. and Nagi, M. N. 2010. Thymoquinone attenuates diethylnitrosamine induction of hepatic carcinogenesis through antioxidant signaling. *Oxid. Med. Cell Longev.*3(4), pp. 254-261.
- Sell, S. 2008. Alpha-fetoprotein, stem cells and cancer: how study of the production of alpha-fetoprotein during chemical hepatocarcinogenesis led to reaffirmation of the stem cell theory of cancer. *Tumour. Biol.*29(3), pp. 161-180.
- Shaarawy, S. M., Tohamy, A. A., Elgendy, S. M., Elmageed, Z. Y., Bahnasy, A., Mohamed, M. S., Kandil, E. and Matrougui, K. 2009. Protective effects of garlic and silymarin on NDEA-induced rats hepatotoxicity. *Int. J Biol. Sci.*5(6), pp. 549-557.
- Shaker, M. K., Abdella, H. M., Khalifa, M. O. and El Dorry, A. K. 2013. Epidemiological characteristics of hepatocellular carcinoma in Egypt: a retrospective analysis of 1313 cases. *Liver Int.*33(10), pp. 1601-1606.
- Singh, A. and Handa, S. S. 1995a. Hepatoprotective activity of *Apium graveolens* and *Hygrophila auriculata* against paracetamol and thioacetamide intoxication in rats. *J Ethnopharmacol.*49(3), pp. 119-126.
- Sinha, A. K. 1972. Colorimetric assay of catalase. *Anal. Biochem.*47(2), pp. 389-394.
- Song, Y., Jin, S. J., Cui, L. H., Ji, X. J. and Yang, F. G. 2013. Immunomodulatory effect of *Stichopus japonicus* acid mucopolysaccharide on experimental hepatocellular carcinoma in rats. *Molecules.*18(6), pp. 7179-7193.
- Sultana, S., Ahmed, S., Jahangir, T. and Sharma, S. 2005. Inhibitory effect of celery seeds extract on chemically induced hepatocarcinogenesis: modulation of cell proliferation, metabolism and altered hepatic foci development. *Cancer Lett.*221(1), pp. 11-20.
- Szasz, G. 1969. A kinetic photometric method for serum gamma-glutamyl transpeptidase. *Clin. Chem.*15(2), pp. 124-136.
- Villanueva, A. and Llovet, J. M. 2011. Targeted therapies for hepatocellular carcinoma. *Gastroenterology*140(5), pp. 1410-1426.
- Wallace, M. C., Preen, D., Jeffrey, G. P. and Adams, L. A. 2015. The evolving epidemiology of hepatocellular carcinoma: a global perspective. *Expert. Rev. Gastroenterol. Hepatol.*9(6), pp. 765-779.
- Wennerberg, A. E., Nalesnik, M. A. and Coleman, W. B. 1993. Hepatocyte paraffin 1: a monoclonal antibody that reacts with hepatocytes and can be used for differential diagnosis of hepatic tumors. *Am. J Pathol.*143(4), pp. 1050-1054.
