



Full Length Research Article

CORELATIVE STUDY OF PLACENTA IN PREGNANCY INDUCED HYPERTENSION CASES

***Dr. Gaurav Gautam, Dr. Arvind Bhake, Dr. N. Samal, Dr. S. Shukla, Dr. Moushmi Gautam and
Dr. Parikshit Patil**

Department of Pathology, Jawaharlal Nehru Medical College, Sawangi (Meghe) Wardha, Maharashtra 442004,
India

ARTICLE INFO

Article History:

Received 13th March, 2015
Received in revised form
19th April, 2015
Accepted 30th May, 2015
Published online 28th June, 2015

Key Words:

Placenta,
PIH,
Perinatal

ABSTRACT

Introduction: Placenta is directly related to the growth and development of the fetus in utero. Hypertensive disorders of pregnancy are strongly associated with fetal growth restriction, prematurity, contributing largely to perinatal mortality and morbidity.

Aims and Objectives: 1. Identification of morphological changes in placenta in patients with PIH.

2. Correlating these changes which may contribute or cause adverse pregnancy or fetal outcome.

Materials and Methods: The present study is a prospective one which was carried out at Dept. of Pathology JNMC and AVBRH HOSPITAL. Pathological examination of 50 placentae were done and were reported according to the guidelines.

Conclusion: Hypertensive disorders of pregnancy, adversely influence the morphology of the placenta. The pathological changes observed in placenta of patients with hypertensive disorders of pregnancy like infarction adversely influence the perinatal outcome. However, none of these pathological changes of placenta are specific to hypertensive disorders of pregnancy.

Copyright © 2015 Dr. Gaurav Gautam. This is an open access article distributed under the Creative Commons Attribution License, which permits unrestricted use, distribution, and reproduction in any medium, provided the original work is properly cited.

INTRODUCTION

In 1937 Noseman defined the placenta as a fusion of the fetal membranes to the uterine mucosa for the transfer of oxygen and metabolites between maternal and fetal blood. It provides oxygen, nourishment and protection to the fetus. It also has secretory and endocrine function. Many of the disorders of pregnancy which are associated with high perinatal morbidity and mortality are accompanied by gross pathological changes in placenta. Hypertensive disorders of pregnancy are common and forms one of the deadly triad, along with hemorrhage and infection that greatly contribute to maternal mortality and morbidity. In addition hypertensive disorders of pregnancy are strongly associated with fetal growth restriction, prematurity, contributing largely to perinatal mortality and morbidity. Preeclampsia is defined as blood pressure 140/90 mm Hg or an increase of 30mmHg systolic or 15 mmHg diastolic over baseline values on at least two occasions > 6 hrs apart with proteinuria or generalized edema. The purpose of the present study is to correlate study of placenta in pregnancy induced hypertension cases and in normal pregnancy .

AIMS AND OBJECTIVES

A study of placenta-

- Identification of morphological changes in placenta in patients with pregnancy induced hypertension.
- correlating these findings which may contribute in causing adverse effect on maternal health and fetal weight

MATERIALS AND METHODS

The present study is a cross-sectional prospective study which was carried out at Dept. of Pathology J.N. Medical College and Acharya Vinoba Bhave Rural Hospital to study the placenta in pregnancy induced hypertensive patients. The period of study was 2 years from July 2011- August 2013. 100 patients i.e 50 Mothers with normal pregnancy and 50 mothers with Pregnancy Induced Hypertension were selected from indoor patients of department of gynecology and obstetrics irrespective of their parity were selected for the study. In this study, the age range of these mothers varied from 20 years to 38 years. Mothers were examined along with recording of their medical history. Their investigation reports were checked. Mothers with blood pressure ranging above 140/90 mm Hg with oedema, with or without albuminuria were

***Corresponding author: Dr. Gaurav Gautam**

Department of Pathology, Jawaharlal Nehru Medical College,
Sawangi (Meghe) Wardha, Maharashtra 442004, India

considered. Cases were diagnosed by treating obstetrician as per acclaimed criteria and were subdivided into mild PIH, severe PIH and eclampsia. After delivery, placentae were collected for morbid and histopathological studies. Size, weight of placentae were noted along with inspection of marginal veins for any thrombus, the number of cotyledons, condition of membranes, presence of infarction and calcification. Tissues were taken from the following placental sites for histopathological studies:-

- Near the implantation of umbilical cord.
- Margins - 1, 2, 3, 6, 9 o' clock positions
- Centre of the placenta, if any.
- Fibrotic area, if any
- Infarcted area, if any

Their birth weights were noted and feto-placental weight ratio was calculated in each case. Descriptive statistical analysis had been carried out in the present study.

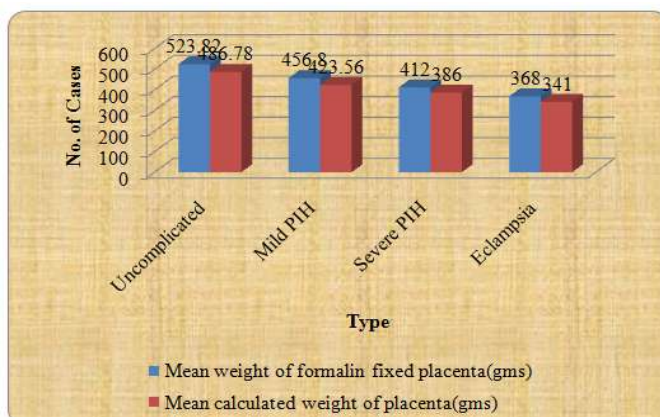
RESULTS

100 patients i.e 50 Mothers with normal pregnancy and 50 mothers with pregnancy induced Hypertension were selected from indoor patients of department of gynecology and obstetrics.

Type	No of cases n=100	Percentage (%)
Uncomplicated (normal)	50	50
Mild PIH	29	58
Severe PIH	17	34
Eclampsia	4	8

In the present study group, the maximum i.e. 29 cases belonged to mild PIH, 17 cases belonged to severe PIH and minimum of 4 cases were of eclampsia. There were 50 cases of uncomplicated pregnancies as control group.

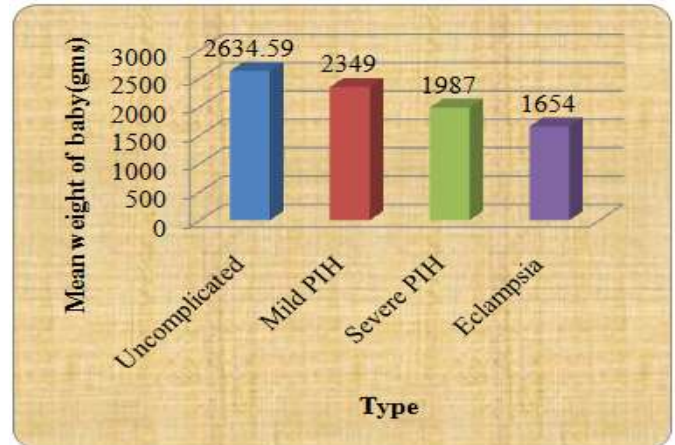
Type	Mean weight of formalin fixed placenta (gms)	Mean calculated weight of placenta (gms)
Uncomplicated (normal)	523.82	486.78
Mild PIH	456.8	423.56
Severe PIH	412	386
Eclampsia	368	341



The mean weight of placentae in PIH is lower than the normal placentae. The findings are statistically highly significant. In

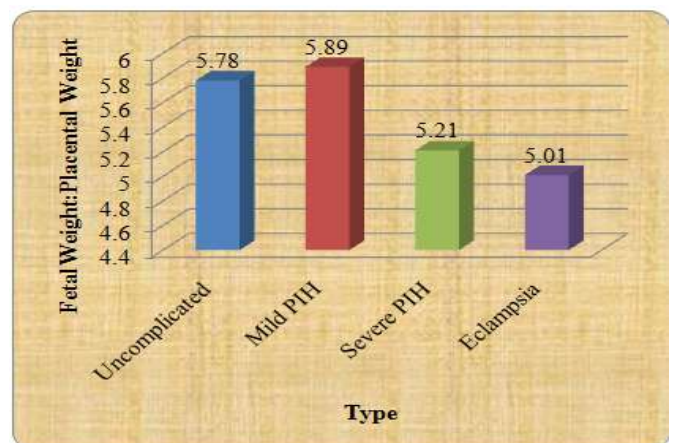
the present study the mean calculated placental weight was more in the mild PIH Group and minimum in eclampsia group i.e. 456.8gms and 412gms respectively. Placental weight decreases as the severity of disease progresses.

Type	Mean weight of baby(gms)
Uncomplicated (normal)	2634.59
Mild PIH	2349
Severe PIH	1987
Eclampsia	1654



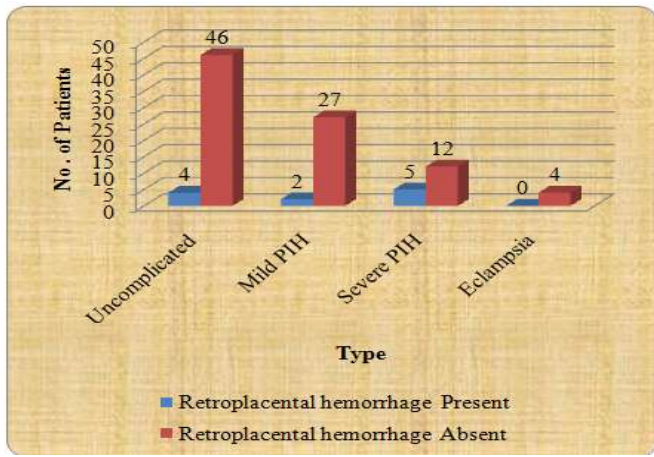
Fetal birth weight was highest in the uncomplicated pregnancy group i.e. 2634.59gms and lowest in eclampsia i.e.1654 gms. Fetal birth weight decreases with increasing grades of PIH. The mean of ratio in PIH group is significantly lower than normal. The findings are statistically significant.

Type	Fetal Weight: Placental Weight
Uncomplicated (normal)	5.78
Mild PIH	5.89
Severe PIH	5.21
Eclampsia	5.01



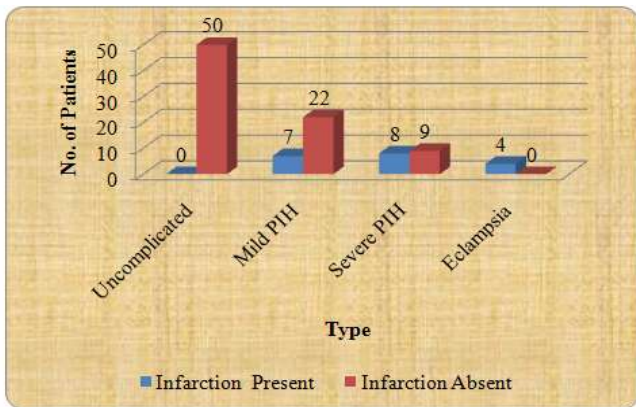
Fetoplacental weight ratio decreases with increasing degree of PIH.

Type	Retroplacental hemorrhage Present	Retroplacental hemorrhage Absent
Uncomplicated (normal)	4	46
Mild PIH	2	27
Severe PIH	5	12
Eclampsia	0	4



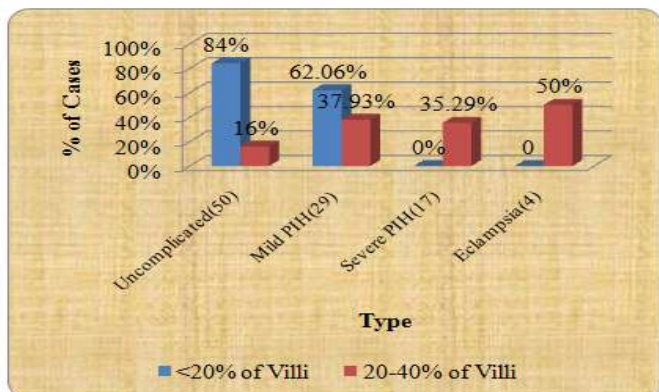
In the present study, 7 cases out of a total number of 50 cases of PIH showed retroplacental hemorrhage. All the cases belonged mild and severe PIH group.

Type	Infarction Present	Infarction Absent
Uncomplicated (normal)	0	50
Mild PIH	7	22
Severe PIH	8	9
Eclampsia	4	0

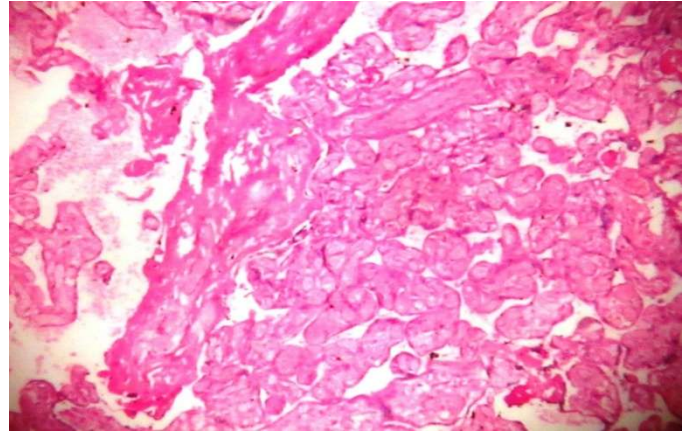


In present study no placenta from normal cases showed presence of placental infarction while it is present in 19 placentae from PIH group. Placental infarction was more in cases of PIH than the normal. The findings were statistically significant.

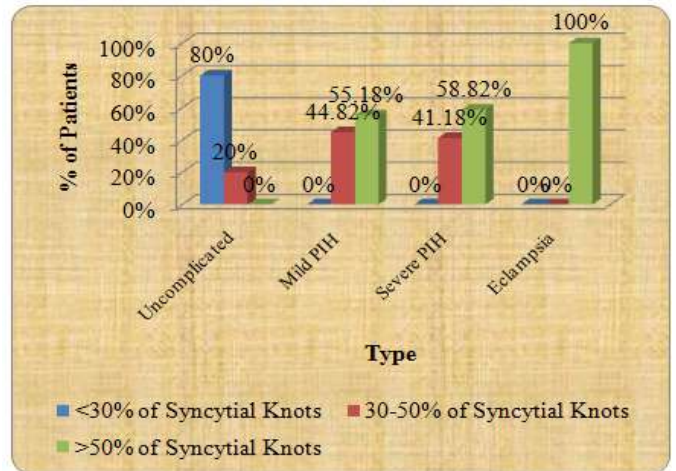
Type	<20% of Villi	20-40% of Villi	>40% of Villi
Uncomplicated (normal)	42(84%)	8(16%)	0(0%)
Mild PIH	18(62.06%)	11(37.93%)	0(0%)
Severe PIH	0(0%)	6(35.29%)	11(64.7%)
Eclampsia	0	2(50%)	2(50%)



Cytotrophoblastic proliferation of 20-40 % was seen in all the mild PIH, severe PIH and eclampsia cases. 11 cases of severe PIH and 2 (50%) cases of eclampsia showed >40% cytotrophoblastic hyperplasia. Cytotrophoblastic proliferation of >20% was more in PIH (66% cases) than in the control group (16%) placentae from PIH. The findings were statistically significant



Type	<30% of Syncytial Knots	30-50% of Syncytial Knots	>50% of Syncytial Knots
Uncomplicated (normal)	40(80%)	10(20%)	0(0%)
Mild PIH	0(0%)	13(44.82%)	16(55.18%)
Severe PIH	0(0%)	7(41.18%)	10(58.82%)
Eclampsia	0(0%)	0(0%)	4(100%)



All the the cases of severe PIH showed syncytial knots of > 30% and all cases of eclampsia showed syncytial knots>50% while only 55.18 % cases of mild PIH and 58.82 % cases of severe PIH showed the same. Normal (control) group showed 80% placentae with <30% syncytial knots and only 10% placentae with > 30% syncytial knots.

Type	Fibrinoid Necrosis >3% Villi	Fibrinoid Necrosis <3% Villi
Uncomplicated (normal)	4(8%)	46(94%)
Mild PIH	11(38%)	18(62%)
Severe PIH	9(53%)	8(47%)
Eclampsia	3(75%)	1(25%)

DISCUSSION

	Udainia A. (2001)	Majumdar S et al. (2005)	Kurdukar et al (2007)	Present study
Mean placental weight	In normal group - 495g and in PIH 405 g, placental weight decreased in PIH	In normal group - 485.85g and in PIH 399g, placental weight decreased in PIH	In normal group - 475g and in mild PIH 423.4g, in severe 390.2, eclampsia 364. placental weight decreased with increase in severity of PIH	In normal group - 486.78g and in mild PIH 423.4g, in severe 386, eclampsia 341. placental weight decreased with increase in severity of PIH
Mean fetal birth weight	In normal group- 2640g, in PIH 2368g, so fetal weight decreased in PIH	In normal group- 2800g, in PIH 2040g, so fetal weight decreased in PIH	In normal group-2800g, in mild PIH 2460g, in severe 1960g, eclampsia 1740g. So, fetal weight decreased with increase in severity of PIH	In normal group-2634.59g, in mild PIH 2349g, in severe 1987g, eclampsia 1654g. So, fetal weight decreased with increase in severity of PIH

	Udainia A. (2001)	Majumdar S et al. (2005)	Kurdukar et al (2007)	Present study
Fetal placental weight ratio	-	In normal group-6:23:1, in PIH 5.22:1, so fetal weight decreased in PIH	In normal group- 5:86:1, in PIH 5.17:1. So, fetal placental weight decreased with increase in severity of PIH	In normal group-5.78:1, in mild PIH 5.89:1, in severe 5.21:1, eclampsia 5.01:1. So, fetal placental weight ratio decreased with increase in severity of PIH

	Dutta DK, Dutta B (1989)	Sodhis et al (1990)	Majumdar S et al. (2005)	Kurdukar et al (2007)	Present study
Retroplacental haematoma	In PIH patients showing Retroplacental haematoma 18 out of 59, i.e 30.7 %	In PIH patients showing Retroplacental haematoma 2out of 20, i.e 10 %	-	Retroplacental haematoma showed in mild PIH, 2 out of 23 i.e 8.69 %, in severe 2 out of 16 i.e 12.5 %, eclampsia 2 out of 10 i.e 20 %.	Retroplacental haematoma showed in mild PIH, 2 out of 29 i.e 6.8 %, in severe 5 out of 17 i.e 29.4 %, eclampsia 4 out of 4 i.e 100 % which was comparable to other studies
Placental infarction	-	-	-	Placental infarction (involving >5% of parenchyma) showed in mild PIH, 3 out of 23 i.e 13 %, in severe 7 out of 16 i.e 43.7 %, eclampsia 4 out of 10 i.e 40 %.	Placental infarction (involving >5% of parenchyma) showed in mild PIH, 5 out of 29 i.e 17.24 %, in severe 7 out of 17 i.e 41.27 %, eclampsia 4 out of 4 i.e 100 % which was clinically significant. Seen more in eclampsia patients

	Dutta DK, Dutta B (1989)	Sodhis et al (1990)	Majumdar S et al. (2005)	Kurdukar et al (2007)	Present study
Cytotrophoblastic proliferation	-	Cytotrophoblastic proliferation observed in the range of 20- 40 % were 39.13 %, 37.5% and 30 % in mild, severe PIH and eclampsia, was significant	-	Cytotrophoblastic proliferation observed in the range of 20- 40 % were 39.13 %, 37.5% and 30 % in mild, severe PIH and eclampsia, was significant	Cytotrophoblastic proliferation observed in the range of 20- 40 % were 37.9 %, 35.2% and 50 % in mild, severe PIH and eclampsia was significant
Syncytial Knots	-	-	increase number of syncytial knots in PIH patients	84 % syncytial knots in severe PIH and 100 % syncytial knots in eclampsia	Syncytial knots present in all types of PIH with increase in severity of disease
Fibrinoid necrosis	-	-	-	3% of villi in mature placenta show fibrinoid necrosis	Similar findings were seen as in kurdukar et al

In present study placenta from normal, 40(80%) cases showed presence of syncytial knots <30% of villi, while 10 (16%) cases showed syncytial knots in >30% villi. The findings were statistically significant

75% of cases of eclampsia and 53% severe PIH cases showed fibrinoid necrosis in >3% only 38% cases of mild eclampsia showed this feature. In present study 2(4%) placentae from normal cases showed presence of fibrinoid necrosis in > 3% of villi. 22(44%) placentae from PIH group showed fibrinoid necrosis. Fibrinoid necrosis in < 3% of villi was seen in 28(56%) cases of PIH and 48(96%) cases of the normal. The findings were statistically significant.

Conclusion

Hypertensive disorders of pregnancy, adversely influence the morphology of the placenta. The pathological changes observed in placentae of patients with hypertensive disorders of pregnancy adversely influence the maternal health and perinatal outcome.

REFERENCES

Avasthi, K. and Micha, U. 1991. Histopathology of placenta and its correlation with fetal outcome. *J Obstetric Gynaecol Ind*; 41: 317.

- Boyd, JD. and Hamilton, WJ. 1970. The Human placenta, 1st ed. Cambridge, England: W. Heffer and sons. p. 114-189.
- Dutta, DC. 1992. The placenta. In Dutta DC, ed. Text book of obstetrics including perinatology and contraception, 3rd ed. Calcutta, India: New central book Agency: p. 28-40.
- Fox, H. 1995. General Pathology of placenta. Obstetrics and gynaecological Pathology ed. Fox H. New York: Churchill Livingstone, p. 1477-1508.
- Joshi, V. V. 1994. Handbook of placental pathology published by Igaku Shoin Medical publisher.
- Kurdukar, M. D., Deshpande, N. M., Shete, S. S. and Zavar, M. P. 2007. Placenta in PIH: Indian Journal of Pathology and Microbiology; 50(3); 493-497
- Majumdar, S. et al. 2005. Study of placenta in normal and hypertensive pregnancies *J.Anat.Soc. India*: 54 (2): 34-38
- Naeye, RL. 1987. Functionally important disorders of the placenta, umbilical cord and fetal membranes. *Hum Pathol.*; 18:680-691.
- Nobis, P., Das, U. 1991. Placental morphology in hypertensive pregnancy *J Obstet and Gynecol India*; 41: 166-9.
- Sodhi, S., Mohan, H., Jaiswal, TS., Mohan, PS. and Rathee, S. 1990. Placental pathology in pre-eclampsia eclampsia syndrome. *Indian Journal of Pathology and Microbiology*; 33(1):11-6.
- Udainia, A. and Jain, M.L. 2001. Morphological study of placenta in pregnancy induced hypertension with its clinical relevance. *J. Anatomical society of India* 2001; 50: 24-7.
