



ISSN: 2230-9926

Available online at <http://www.journalijdr.com>

IJDR

International Journal of Development Research
Vol. 5, Issue, 06, pp. 4771-4775, June, 2015

International Journal of
DEVELOPMENT RESEARCH

CASE REPORT

“ACNE KELOIDALIS NUCHAE IN BROTHERS”-OUR EXPERIENCE IN SUCCESSFUL SURGICAL MANAGEMENT OF EXTENSIVE LESIONS

^{1,*}Dr. Anji Reddy Kallam, ²Dr. Ananta Satya Narayana, M. and ³Dr. Rama Krishna, B. A.

¹Department of Plastic Surgery, Alluri Sitarama Raju Academy of Medical Sciences, Eluru, AP., India

^{2,3}Department of Pathology, Alluri Sitarama Raju Academy of Medical Sciences, Eluru, AP., India

ARTICLE INFO

Article History:

Received 02nd March, 2015
Received in revised form
08th April, 2015
Accepted 20th May, 2015
Published online 28th June, 2015

Key Words:

Acne keloidalis,
Acne keloidalis nuchae,
Folliculitis keloidalis

ABSTRACT

Acne keloidalis nuchae (AKN) is a chronic, idiopathic, inflammatory condition most commonly occurring in young black males and represents nearly 0.45% of all dermatoses affecting black patients. The male to female ratio is 20:1. It is initially characterized as firm skin colored papules and pustules on the occipital region of the scalp and posterior aspect of the upper part of the neck. These lesions later coalesce and may ultimately develop into tumor-like masses giving the appearance of keloidal plaques with destruction of hair follicles and loss of hair. Intracutaneous abscesses and sinus tracts with purulent discharge appear in advanced cases. While the pathogenesis remains uncertain, precipitating factors include localized trauma, chronic irritation, seborrhea, and androgen excess. In this article we review our experiences in two patients with extensive lesions who are brothers in the same family and discuss the advantages of management by electrosurgical excision followed by primary skin grafting.

Copyright © 2015 Dr. Anji Reddy Kallam et al. This is an open access article distributed under the Creative Commons Attribution License, which permits unrestricted use, distribution, and reproduction in any medium, provided the original work is properly cited.

INTRODUCTION

Case no.1: A 39 year old black obese individual, an employee of state government presented with multiple papulo pustular lesions with keloidal scar formation in the nape of the neck (Figure 1). The lesion started 6 years back with isolated lesions and over the last 6 months they are growing in size and troubling with pain, itching, discharge with foul smell and feeling uncomfortable to go for his regular duties. There is superficial excoriation with discharge and absence of hair. He had taken different antibiotics and homeopathy treatment without any benefit.

Case no.2: A 36 years old black, obese, younger brother of 1st patient developed papulo pustular lesions in the nape of the neck 4 years back. He took several antibiotics and local applications of ointments as prescribed by physicians and dermatologists without any result. Over the last 3 months the lesions are increasing in size, itching and painful with tumor formation and loss of hair over the lesions (Figure 6).

Treatment: After necessary local preparation both the patients were operated under general endotracheal anesthesia, keeping

the patient in prone position. The entire lesion was excised, with horizontal elliptical incision using electro surgical cautery going up to the deep dermis ensuring complete removal of the lesion (Figure 2, 7). Bleeding was minimal and estimated, less than 200 ml for the entire procedure. The raw area was covered primarily by single sheet of meshed split skin graft of medium thickness, harvested from anteromedial aspect of thigh (Figure 3, 8). Soft medium sized cervical collar was given to restrict the movements of the neck. The graft took up completely when primary dressing was done after 5 days and the patient was discharged from the hospital on 7th postoperative day. The diagnosis was confirmed by histopathology (Figures 4&9). They are followed up regularly every month and they returned to their work within 2 weeks after surgery. First patient who came for follow up after one month and after 2 years 3 months (Figure 5). Showed no evidence of recurrence and extremely happy without any symptoms and the grafted area did not pose any cosmetic problem. Second patient followed one year after operation and the grafted site completely healed and doing his regular work and has no cosmetic problem (Figure 10).

DISCUSSION

Kaposi first described this lesion in 1869 and described as dermatitis papillaris capilliti (Kaposi, 1869).

*Corresponding author: Dr. Anji Reddy Kallam
Department of Plastic Surgery, Alluri Sitarama Raju Academy of
Medical Sciences, Eluru, AP., India

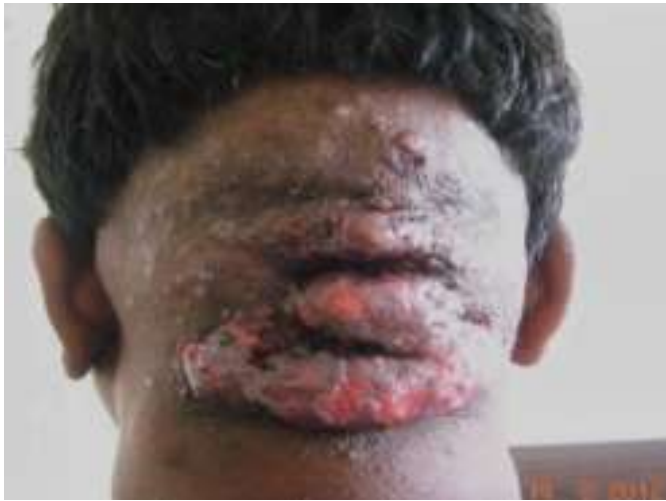

Figure 1. Case 1. Preoperative photograph

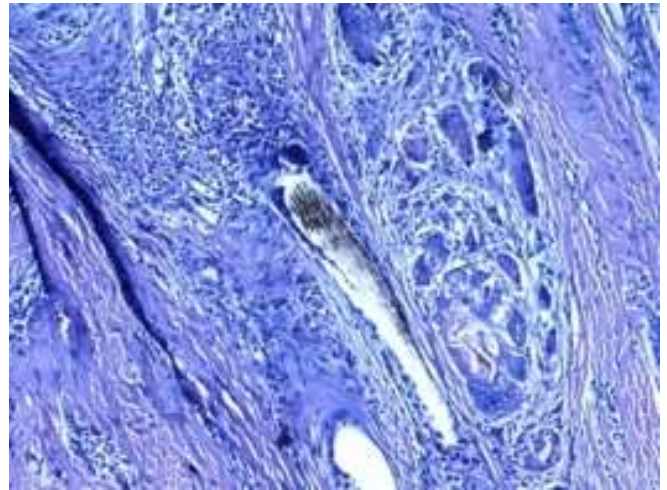


Figure 4. Case 1. Photomicrograph of Acne keloidalis showing perifollicular lymphoplasmacytic infiltrate along with foreign body giant cell reaction

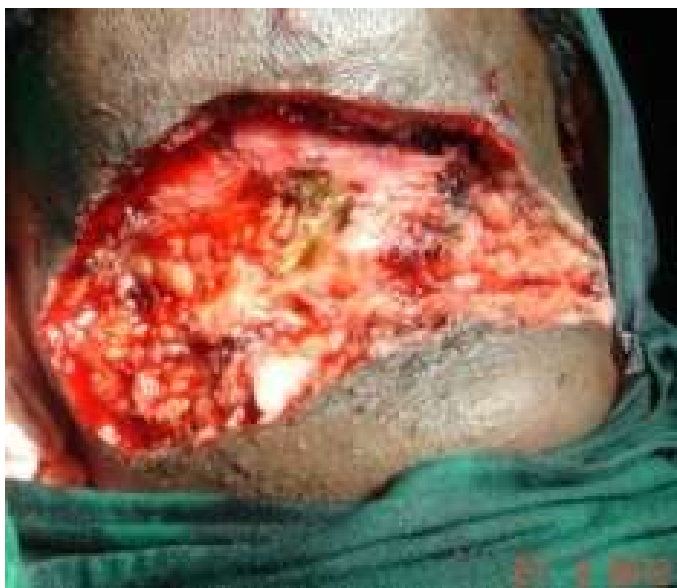

Figure 2. Case 1. Excision was performed in a horizontal elliptical fashion

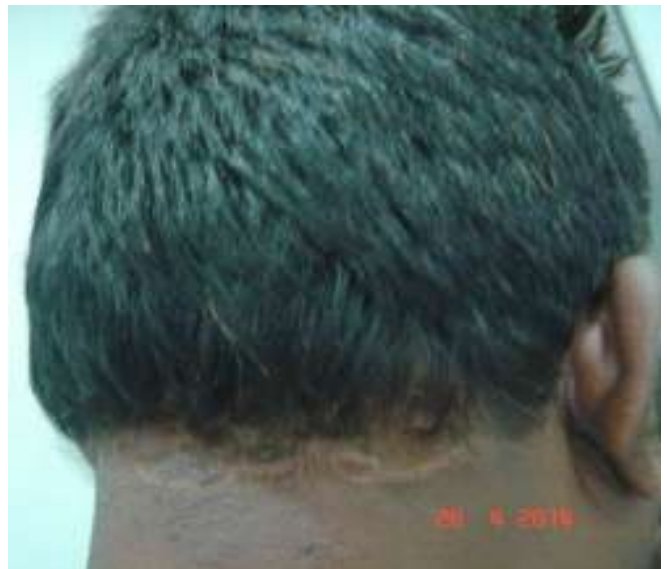

Figure 5. Case 1. Postoperative photograph after 2 years 3 months, with good result

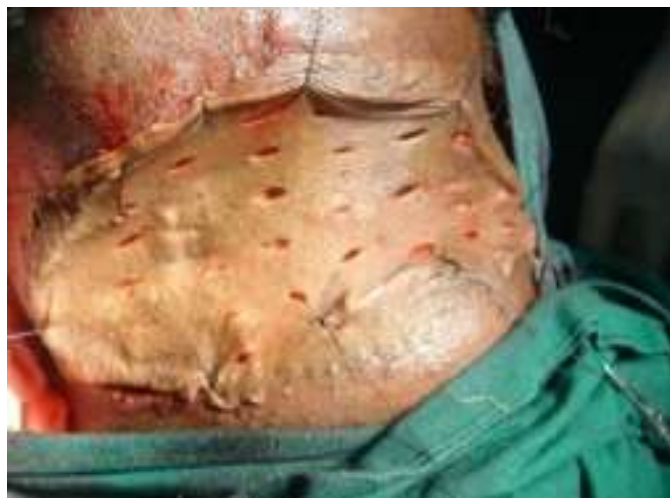

Figure 3. Case 1. The raw area was covered primarily by single sheet of meshed split skin graft of medium thickness

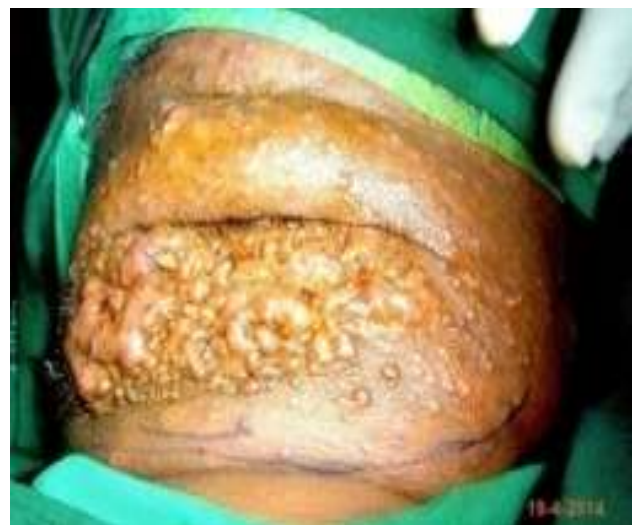

Figure 6. Case 2. Preoperative photograph

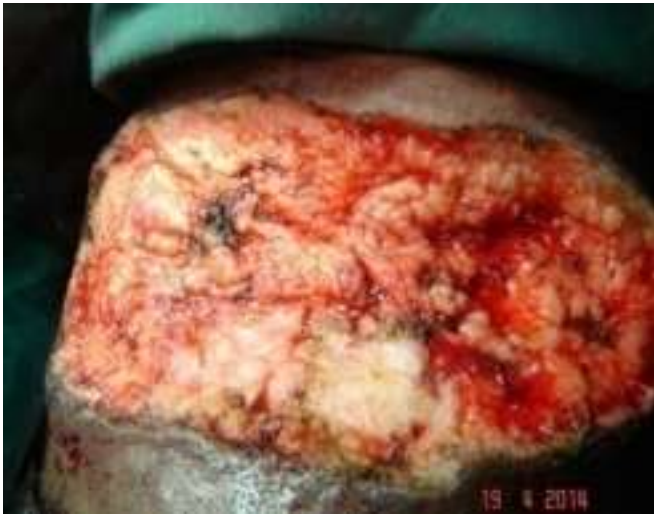

Figure 7. Case 2. Defect after excision

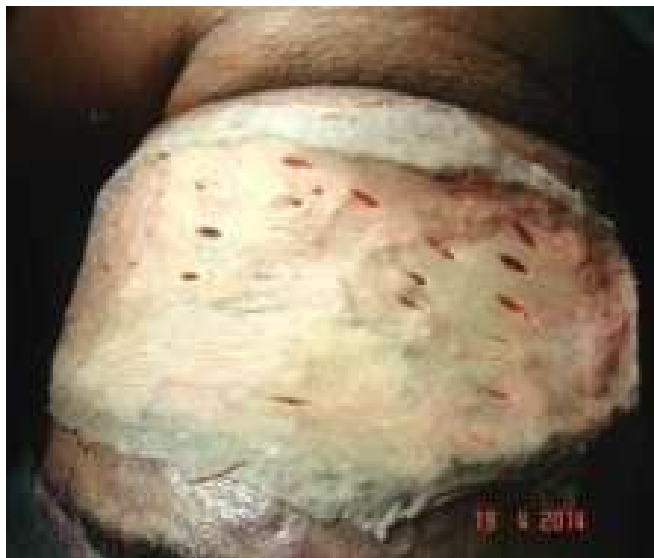

Figure 8. Case 2. The raw area was covered primarily by single sheet of meshed split skin graft of medium thickness

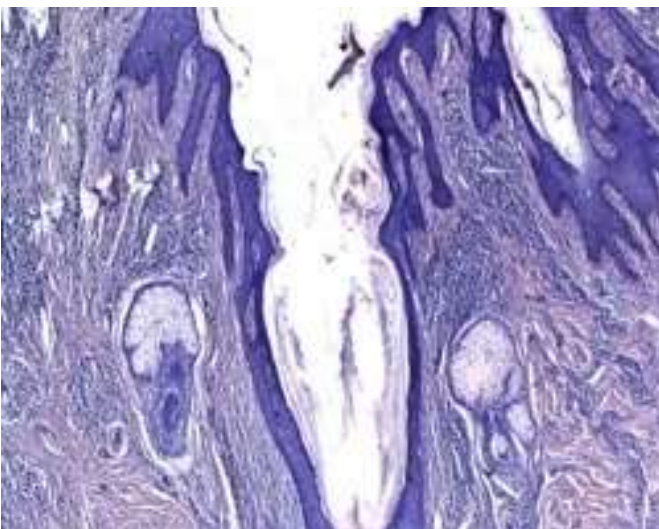


Figure 9. Case 2. Photomicrograph of Acne keloidalis showing perifolliculitis with destruction of hair and hair follicle

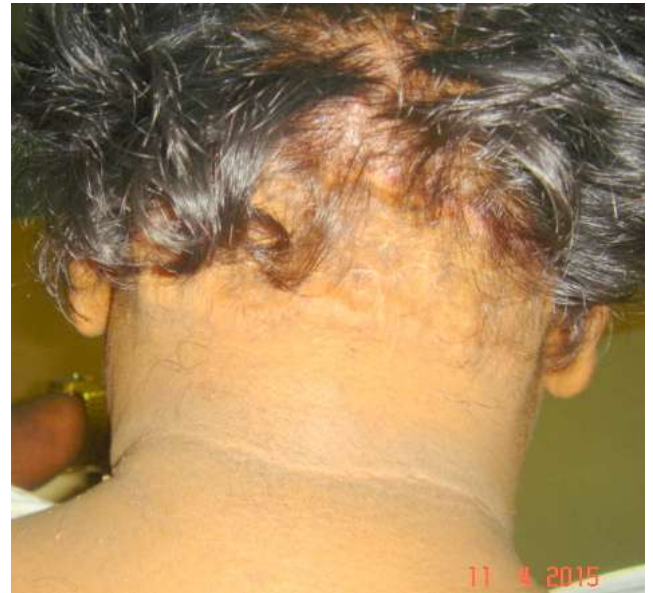

Figure 10. Case 2. Postoperative photograph after 1 year

Bazin in 1872 first named this lesion as Acne Keloidalis (Cosman and Wolff, 1972). This idiopathic inflammatory condition is most commonly seen in young African-American men after puberty, representing approximately 0.45 percent of all dermatoses affecting African Americans. (Ogunbiyi and George, 2005) The male-to-female ratio is approximately 20:1, and these cases are rarely reported in women (Dinehart *et al.*, 1989). The cause of this lesion is unknown and is not a true keloid and has no relationship with Acne Vulgaris. Many have proposed an etiology similar to that of pseudofolliculitis barbae, implicating the action of hairs curving into the skin leading to a foreign body inflammatory reaction (Kelly, 2003). Close shaving of hair in the low neck area with the curved, coarse type of hair that is typically seen in black patients has been proposed as an etiological factor in 90 percent of AKN cases (Salami *et al.*, 2007). But such an appearance is not seen in our patients.

Additional proposed etiological factors include constant irritation from shirt collars, wearing helmets and chronic low-grade folliculitis. (Halder, 1983) In a small case series, four patients with AKN were found to have an associated acanthosis nigricans, suggesting that acne keloidalis may represent a cutaneous sign for the metabolic syndrome (Verma and Wollina, 2010). Cases of acne keloidalis occurring in Caucasian patients after cyclosporin use following organ transplantation have also been reported (Azurdia *et al.*, 2000 and Carnero *et al.*, 2001). The development of this disease in brothers of same family as our two cases needs further probe regarding any hereditary factor. The clinical spectrum of AKN is broad. Initial lesions are small, firm, discrete, follicular papules and pustules on the occipital scalp and posterior neck. With time, the papules coalesce into horizontal hairless keloidal plaques, which may be fringed with tufted hairs. In the most extreme forms, disfiguring tumor-like masses or abscesses exuding odiferous pus may be present. Although many cases of AKN are asymptomatic, patients may complain of pruritus or pain, and the lesions are often a cause of tremendous cosmetic concern.

Pathology

Histologically, in early stages there will be dense follicular and perifollicular infiltration consisting of neutrophils and lymphocytes (Kelly, 2003). In advanced cases disrupted and broken hair follicles are surrounded by granulomatous inflammation, perifollicular abscess formation and fibrosis. The dermal fibrosis resembles collagen in scar formation and differs from that seen in true keloids (Figure 9). The choice of therapeutic modality largely depends on the clinical stage of disease. Papulopustular lesions may respond to topical therapies, intralesional therapy, or physical modalities, while larger plaques and tumors generally require surgical excision. Topical therapies include corticosteroids, antibiotics, retinoids, and immune modulators, used as monotherapy or in combination. Class I or II topical corticosteroids applied twice daily may be efficacious and a recent open-label study found topical clobetasol propionate foam to be effective in improving mild-to-moderate lesions. When pustules or other evidence of infection are present, topical clindamycin or erythromycin is warranted to decrease inflammation.

Combination antibiotic and corticosteroid preparations are quite popular. Imiquimod cream prescribed daily for five consecutive days for a total of eight weeks has been successful in a few patients (Kelly, 2003). For mild-to-moderate cases not responsive to topical therapy, intralesional corticosteroids, usually triamcinolone acetonide, may be injected at three- to four-week intervals. Laser therapy (carbon dioxide or neodymium-doped yttrium aluminium garnet) and cryotherapy have also been proven successful in some patients (Kelly, 2003). The late lesions with discharging keloidal masses are refractory to topical medication and intralesional injections of Triamcinolone. Surgical excision is the mainstay in proper management of these late and advanced cases as seen in both of our cases. Several options are proposed like staged excision, excision with primary closure, excision and leave the raw area for secondary healing and excision followed by primary skin grafting. Regardless of the type of closure chosen, the affected tissue must be excised to a depth extending at least to the base of the hair follicles in order to prevent recurrences. Different modalities were described by different authors for excision like use of laser and cryo but the electrosurgical excision is quite convenient, with less of bleeding and ensuring complete excision without the possibility of local recurrence. Each method has its own advantages and disadvantages.

Our experience in these two cases showed electrosurgical excision with primary skin grafting of the raw area gives excellent results and satisfaction to the patients, as seen by our patients followed for 1 to 2 years. Gloster opined excision with skin grafting is generally an inferior option as the cosmetic outcome is poor. Split-thickness skin grafts are typically atrophic, depressed, and do not match the surrounding skin in color, texture, or thickness. Excision and primary layered suture is not possible in such extensive defects, since there is no redundant skin over the nape of the neck and forceful closure may result in dehiscence, restricted movements of the neck and recurrence. Excision followed by dressings for secondary healing is troublesome to the patients, takes very long time for several months and more expensive and inconvenient and has to be away from regular work for long

time. Nashida *et al* reported excision with secondary intention healing is an effective option in the treatment of extensive AKN that fails to respond to medical treatment or minor surgical intervention. Although the average time for wound healing is 6 to 8 weeks, this approach offers good cosmetic results as the wound often retracts to form a scar that is much smaller and flatter than the original one. Cosmesis is further improved when the excision is a horizontal ellipse of the posterior hairline and posterior aspect of the scalp, resulting in a more natural-appearing hairline. In addition, recurrences may be fewer with secondary intention healing. Staged excision at intervals is not recommended in such extensive lesions with infection and discharge. Considering all the pros and cons of these alternative methods, we are of the opinion, electrosurgical excision followed by primary skin grafting gives very good results with short recovery time, pain and suffering and less cost of treatment and in both of our cases the patients are 100% satisfied without any cosmetic problem who are followed nearly for 2 years. Adjuvant therapy is not routinely recommended following surgical excision of AKN, but can be useful if an elevated scar develops after complete healing. In these two cases, flat scar was present following electrosurgical excision, negating a need for adjuvant therapy. Minor recurrences are generally due to inadequate removal of hair follicles within the affected tissue.

Conclusions

The two patients are brothers from the same family and we have to further probe the possibility of hereditary factor in the causation of this condition. Both are dark skinned and obese. In these two cases we found the following advantages for complete excision and primary skin grafting.

- 1) Electro surgical cautery was used for excision thus ensuring complete excision up to subcutaneous level reducing the chances of recurrence.
- 2) The blood loss is minimal with less than 200 ml in both the cases and operation could be completed in less than 45 minutes.
- 3) Comfortable postoperative period, early recovery with short hospital stay (Both are discharged within one week).
- 4) They could return back to their duties within 2 weeks and productive man hours are saved since both are employees.
- 5) They do not have any cosmetic problem as seen from both the patients when they came for follow up regularly.

REFERENCES

- Azurdia, RM., Graham, RM., Weismann, K., Guerin, DM. and Parslew, R. 2000. Acne keloidalis in Caucasian patients on cyclosporine following organ transplantation. *Br J Dermatol.*; 143:465-7.
- Carnero, L., Silvestre, JF., Guijarro, J., Albares, MP. and Botella, R. 2001. Nuchal acne keloidalis associated with cyclosporine. *Br J Dermatol.*; 144:429-430.
- Cosman, B. and Wolff, M. 1972. Acne keloidalis. *Plast Reconstr Surg.*; 50:25-30.
- Dinehart, SM., Tanner, L. and Mallory, S. 1989. Acne keloidalis in women. *Cutis.*; 44:250-2.
- Halder, R. 1983. Hair and scalp disorders in blacks. *Cutis.*; 32:378-380.

- Kaposi, M. 1869. (Ueber die sogenannte framboesia und mehrere andere arten von papillaren Neubildungen der haut.) *Arch Dermatol Syph.*; 1:382-423.
- Kelly, AP. 2003. Pseudofolliculitis barbae and acne keloidalis nuchae. *Dermatol Clin.*; 21:645-653.
- Ogunbiyi, A. and George, A. 2005. Acne keloidalis in females: case report and review of literature. *J Natl Med Assoc.*; 97:736-738.
- Salami, T., Omeife, H. and Samuel, S. 2007. Prevalence of acne keloidalis nuchae in Nigerians. *Int J Dermatol.*; 46:482-4.
- Verma, SB. and Wollina, U. 2010. Acne keloidalis nuchae: another cutaneous symptom of metabolic syndrome, truncal obesity, and impending/overt diabetes mellitus? *Am J Clin Dermatol.*; 11(6):433-6.
