



ISSN: 2230-9926

Available online at <http://www.journalijdr.com>

# IJDR

International Journal of Development Research

Vol. 13, Issue, 06, pp. 63007-63011, June, 2023

<https://doi.org/10.37118/ijdr.26802.6.2023>



RESEARCH ARTICLE

OPEN ACCESS

## RADIOLOGICAL AND BIOCHEMICAL ANALYSIS OF INDIVIDUALS AFFECTED AND NOT AFFECTED BY COVID-19: VACCINATION AS A RESEARCH FACTOR

\*Lucas Mainardo Rodrigues Bezerra, Pedro Oliveira Carvalho Neto, Fernando José De Moraes Silva, Werrington Medeiros Da Silva and Uziel Nunes Silva and Luan Kelves Miranda de Souza

Faculdade De Ciências Humanas, Exatas E Da Saúde Do Piauí, Brasil

### ARTICLE INFO

#### Article History:

Received 20<sup>th</sup> April, 2023

Received in revised form

29<sup>th</sup> April, 2023

Accepted 18<sup>th</sup> May, 2023

Published online 30<sup>th</sup> June, 2023

#### Key Words:

Coronavírus,  
Perfilbioquímico,  
Perfilradiográfico

#### \*Corresponding author:

Lucas Mainardo Rodrigues Bezerra

### ABSTRACT

**Introdução:** A pandemia de Covid-19 causada por um novo tipo de Coronavírus (Sars-Cov-2), que surgiu na cidade chinesa de Wuhan em 2019, transformou a vida da população mundial e é considerada um dos maiores desafios para a sociedade global comunidade neste século. A ameaça de um vírus desconhecido fez com que a comunidade científica unisse esforços para conter a propagação do vírus por meio da criação de uma vacina, considerando o potencial da doença em causar comorbidades nos mais diversos sistemas do corpo humano. **Metodologia:** Trata-se de uma revisão integrativa da literatura realizada, que utiliza uma metodologia exploratória e descritiva, o tema e os critérios para a seleção das fontes que serão utilizadas, análise dos dados, seleção do material temático, interpretação dos resultados e apresentação dos aspectos relevantes obtidos com a revisão, e será embasada para a elaboração dos artigos dos trabalhos finais encontrados nas bases de dados Scientific Electronic Library Online (SciELO), Medical Literature Analysis and Retrieval System Online (Medline) e Literatura Latino-Americana e do Caribe em Ciências da Saúde (Lilacs). **Resultados E Discussão:** Com esse estudo, espera-se no final ter uma base de dados suficiente para comparar as repercussões da COVID-19 em paciente que receberam os diferentes esquemas vacinais, e assim chegar a uma conclusão sobre qual o melhor esquema vacinal disponível para o COVID-19. **Conclusão:** É evidente que os exames laboratoriais são de fundamental importância na avaliação de marcadores de lesão sistêmica ou localizada e inflamação e os exames de imagem podem revelar e sugerir alterações decorrentes de cada fase da infecção. No entanto, mais estudos são necessários para revelar um padrão sindrômico que possa orientar o manejo e o manejo dessa patologia.

Copyright©2023, Lucas Mainardo Rodrigues Bezerra et al. This is an open access article distributed under the Creative Commons Attribution License, which permits unrestricted use, distribution, and reproduction in any medium, provided the original work is properly cited.

Citation: Lucas Mainardo Rodrigues Bezerra, Pedro Oliveira Carvalho Neto, Fernando José De Moraes Silva et al. 2023. "Radiological and biochemical analysis of individuals affected and not affected by covid-19: vaccination as a research factor", *International Journal of Development Research*, 13, (06), 63007-63011.

## INTRODUCTION

SARS-CoV-2, known as the novel Coronavirus, is an emerging zoonotic agent that emerged in December 2019 and causes Coronavirus Disease 2019 (COVID-19). This pathogen results in a syndrome that leads, in some cases, to an intensive care respiratory condition, which requires specialized management in intensive care units (ICU) in many of them, which has often overburdened health systems in recent years. worldwide (MORALES et al, 2020). SARS-CoV-2 was first identified from patient selection in Wuhan, China. The symptoms expressed by patients with COVID-19 are non-specific and cannot be used for an accurate diagnosis (UDUGAMA, Buddhisha et al, 2020). People with COVID-19 may experience a cough, breathing difficulties and, in severe cases, pneumonia. Doctors use chest imaging tests, such as radiography and computed tomography to diagnose the disease, when waiting for results of

RT-PCR tests, considered the standard for most COVID-19 diagnostic studies, for example, or when RT-PCR results are negative and the person has symptoms of COVID-19 (ISLAM, Nayaar et al, 2020). Covid-19 causes several effects on the health of the population, and in the course of the new coronavirus pandemic, the scientific community made efforts to create vaccines that could minimize the effects of the virus on individuals and try to restore a minimally normal life, such as in the pre-pandemic scenario. (NDWANDWE & WIYSONGE, 2021). The population's need for the vaccine has mobilized WHO, government, scientists, pharmacists and non-governmental institutions, leading more than 40 countries to an unprecedented movement to raise funds for the development and production of a vaccine that is made available as a public good. global (Hosangadi et al., 2020). The vaccine production process follows the stages of a clinical study, with pre-clinical stages, carried out in laboratories, in general, in animal models, aiming to evaluate the dose and toxicity in this population.

Clinical trials in humans are divided into three stages. (NDWANDWE & WIYSONGE, 2021). This work aims to analyze the biochemical and radiological profile of individuals affected and not affected by COVID-19, with vaccination as a research factor.

## METHODOLOGY

This is an integrative literature review conducted, which uses an exploratory and descriptive methodology (PEREIRA, et al., 2018). It encompasses steps, such as, establishing the theme and the criteria for the selection of the sources that will be used, data analysis, selection of thematic material, interpretation of results and presentation of relevant aspects obtained with the review, and will be based for the preparation of the final work articles found in the databases Scientific Electronic Library Online (SciELO), Medical Literature Analysis and Retrieval System Online (Medline), and Latin American and Caribbean Literature on Health Sciences (Lilacs), using the descriptors: Coronavirus OR Coronavirus OR Coronavirus; "Thoracic Radiography" OR "Radiography, Thoracic" OR "Thoracic Radiography"; Prognosis OR Prognosis OR Pronosis. Using the Boolean operator "AND".

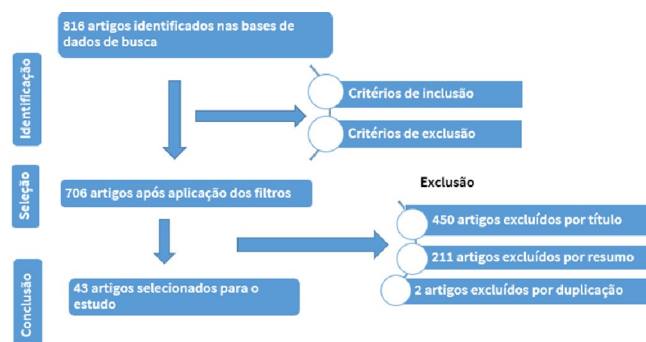
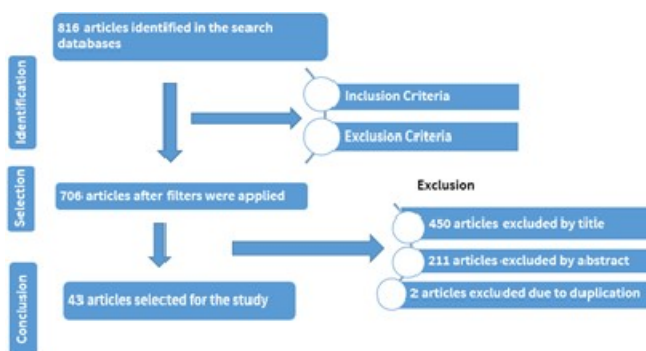


Figure 1. Flowchart of Research and Article Selection



The data were organized during the literature review in order to list the studies related to the theme in question. The filtering of the articles found had as inclusion criteria, articles in the years 2020, 2021 and 2022, in Portuguese, English and Spanish, with full text available, including articles containing primary data; and as exclusion criteria, articles that did not address the research question, publications of theses and dissertations, articles in other languages, texts before 2020, and texts with only the abstract available were discarded. After this filtering, 86 articles were available, and after reading the titles and abstracts, 16 articles were selected that best fit the proposal of this study to compose the present review. The study did not require submission to the Research Ethics Committee, since it is research with secondary data and of public domain, thus not involving any clinical research with humans and animals.

## RESULTS AND DISCUSSION

According to the World Health Organization (WHO), the SARS-CoV-2 virus, which causes COVID-19, was first described in December 2019, in the city of Wuhan, China, and quickly became a

global issue, infecting more than 170 million people and causing over 3.5 million deaths worldwide. It became a public health emergency in January 2020 and was characterized by the WHO as a pandemic. (BAO, ET AL., 2020). According to the World Health Organization (2020), the symptoms of COVID-19 are dry cough, fatigue, and fever, and some people may experience body aches, headache, nasal congestion, hypogeusia, and anosmia, among others. As the SARS-CoV-2 virus is easily transmitted, it is important to educate the global population about ways to protect against infection, including basic precautions such as hand hygiene and social distancing, with the aim of preventing the spread of infection. COVID-19 presents itself in a spectrum from mild flu-like symptoms to severe respiratory impairments and multiple organ failure. It is suggested that SARS-CoV-2 infection be classified into three different stages: the initial stage of infection, characterized by dry cough, fever, and headache; the pulmonary phase, characterized by respiratory distress with or without hypoxemia and changes in lung imaging; and the hyperinflammatory phase, characterized by the cytokine storm, acute hypoxemic respiratory failure, acute respiratory failure, and multiple organ dysfunction (HANI, et al., 2020). With the rapid increase in COVID-19 cases, which continued to overwhelm public health systems worldwide, the first indications of other secondary manifestations of the infection emerged, beyond the respiratory system. In addition to the disease itself, prolonged hospitalization (with or without mechanical ventilation) can lead to deleterious effects, such as pulmonary, cardiovascular, muscular, and cognitive changes, as well as anxiety and depression. Many patients have presented neurological, cardiovascular, circulatory, renal, and hepatic disorders. In the nervous system, changes ranging from olfaction and taste to stroke, meningitis, and encephalitis have been reported, partly due to the neurotropism of SARS-CoV-2 by angiotensin-converting enzyme 2 (ACE2), which, like it is abundantly found in the respiratory system, is also present in neurons and glial cells (BRANDO, 2021; DE BRITO, 2020).

Respiratory infection can play an important role in short-term increases in cardiovascular repercussions, such as an increased chance of acute myocardial infarction and ischemic stroke, as well as systemic arterial hypertension that is strongly associated with SARS-CoV-2 infection, possibly due to the pro-inflammatory state and hypercytokinemia that occur in this disease, which are directly linked to the occurrence of acute cardiac injury, shock, and arrhythmias (FERRARI, 2020). The circulatory repercussions of COVID-19 are mainly due to the abundant expression of angiotensin-converting enzyme 2 (ACE2) in endothelial cells, which plays an important role in immune regulation and inflammation, making them a direct target of SARS-CoV-2 infection (SIDDIQI; LIBBY; RIDKER, 2020). There is a mechanism of kidney injury related to COVID-19, connected to viral tropism, which enters cells by binding to ACE2 through its spike membrane protein.

ACE2 is also highly found in renal tubular epithelial cells and podocytes, explaining COVID-19's tropism towards the kidneys. Furthermore, phenomena such as coagulopathy, complement system activation, and endothelial dysfunction likely play a role in renal injury from SARS-CoV-2 infection (KAYE et al, 2021). Another system that the virus has affinity for is the liver system, given the high expression of ACE2 receptors in cholangiocytes, making this organ a potential target of SARS-CoV-2 infection (JOTHIMANI, 2020). The most practical and inexpensive test for patients with clinical presentation of COVID-19 is chest radiography. However, this test has low sensitivity in the analysis of patients with suspected COVID-19 symptoms, ranging from 30-69%, and some patients may have normal results in the early stages of the disease. In the analysis of altered radiographs, we can have consolidation (36-47% of affected individuals) and low-density opacity, usually with a peripheral basal predominance (20-33%) as the main findings. On the other hand, findings such as pleural effusion are rarer, specified in only about 3% of patients. These findings are visible around 10 to 12 days after the onset of symptoms, and lung abnormalities can progress to the middle and upper fields or diffuse lung involvement (DEGERLI et al., 2021).

Table 1. articles used

ARTICLE TITLE	DATABASE	YEAR OF PUBLICATION
Chest CT manifestations of new coronavirus disease 2019 (COVID-19): a pictorial review	Pubmed	2020
Chest CT score in COVID-19 patients: correlation with disease severity and short-term prognosis	PubMed	2020
Classification of COVID-19 in chest X-ray images using DeTraC deep convolutional neural network	Pubmed	2021
Clinical, laboratory and imaging features of COVID-19: A systematic review and meta-analysis.	Pubmed	2020
Clinical, radiological, and laboratory characteristics and risk factors for severity and mortality of 289 hospitalized COVID-19 patients.	PubMed	2021
Coronavirus Disease 2019 (COVID-19) CT Findings: A Systematic Review and Meta-analysis.	Pubmed	2020
Covid-19 and the cardiovascular system: a comprehensive review.	Pubmed	2021
COVID-19 impact on the renal system: pathophysiology and clinical outcomes.	Pubmed	2021
COVID-19 infection map generation and detection from chest X-ray images	Pubmed	2021
COVID-19 pneumonia: A review of typical CT findings and differential diagnosis	Pubmed	2020
COVID-19: a multimodality review of radiologic techniques, clinical utility, and imaging features.	PubMed	2020
COVID-19: dados atualizados e sua relação com o sistema cardiovascular.	SciELO	2020
COVID-19: The Disease, the Immunological Challenges, the Treatment with Pharmaceuticals and Low-Dose Ionizing Radiation	Pubmed	2021
COVID-19: Vaccines	Pubmed	2021
C-reactive protein correlates with computed tomographic findings and predicts severe COVID-19 early.	PubMed	2020
Diagnosing COVID-19 in the Emergency Department: A Scoping Review of Clinical Examinations, Laboratory Tests, Imaging Accuracy, and Biases.	Pubmed	2020
Diagnosing COVID-19 in the Emergency Department: A Scoping Review of Clinical Exam, Labs, Imaging Accuracy and Biases	Pubmed	2020
Diagnosing COVID-19: The Disease and Tools for Detection	Pubmed	2020
Diagnosis for COVID-19: current status and future prospects.	PubMed	2021
Diagnostic testing for severe acute respiratory syndrome-related coronavirus 2: a narrative review	Pubmed	2020
Diagnostic testing for severe acute respiratory syndrome-related coronavirus 2: a narrative review	PubMed	2020
Extrapulmonary manifestations of COVID-19: Radiologic and clinical overview	Pubmed	2020
Imaging of COVID-19: CT, MRI, and PET	Pubmed	2020
Integrated immune dynamics define correlates of COVID-19 severity and antibody responses.	PubMed	2021
Interim Results of a Phase 1-2a Trial of Ad26.COV2. S Covid-19 Vaccine	Pubmed	2021
Interpretation of hematological, biochemical, and immunological findings of COVID-19 disease: biomarkers associated with severity and mortality.	PubMed	2021
Kinetic changes in virology, specific antibody response and imaging during the clinical course of COVID-19: a descriptive study.	PubMed	2020
Planning and coordination of the radiological response to the coronavirus disease 2019 (COVID-19) pandemic: the Singapore experience.	PubMed	2020
Prognostic value of inflammatory biomarkers for predicting the extent of lung involvement and final clinical outcome in patients with COVID-19.	PubMed	2021
Rapid, point-of-care antigen and molecular-based tests for diagnosis of SARS-CoV-2 infection	PubMed	2021
Reabilitação pulmonar pós-COVID-19	SciELO	2021
Role of computed tomography in COVID-19.	Pubmed	2021
Routine laboratory testing to determine if a patient has COVID-19	PubMed	2020
SARS-CoV-2 causing pneumonia-associated respiratory disorder (COVID-19): diagnostic and proposed therapeutic options.	PubMed	2020
Spontaneous pneumomediastinum, pneumothorax and subcutaneous emphysema in COVID-19: case report and literature review.	PubMed	2020
Systematic review with meta-analysis of the accuracy of diagnostic tests for COVID-19	PubMed	2021
Temporal changes of CT findings in 90 patients with COVID-19 pneumonia: a longitudinal study.	PubMed	2020
The role of imaging and other diagnostic approaches in COVID-19.	PubMed	2020
Thoracic imaging tests for the diagnosis of COVID-19.	Pubmed	2021
Time Course of Redox Biomarkers in COVID-19 Pneumonia: Relation with Inflammatory, Multiorgan Impairment Biomarkers and CT Findings.	PubMed	2021
Waning of COVID-19 vaccine effectiveness: individual and public health risk	PubMed	2022
YU, Jihang et al. COVID-19: The Disease, the Immunological Challenges, the Treatment with Pharmaceuticals and Low-Dose Ionizing Radiation. <i>Cells</i> , v. 10, n. 9, p. 2212, 2021.	PubMed	2021
ZHANG, Jin-jin et al. Clinical, radiological, and laboratory characteristics and risk factors for severity and mortality of 289 hospitalized COVID-19 patients. <i>Allergy</i> , v. 76, n. 2, p. 533-550, 2021.	PubMed	2021

Moreover, chest CT is considered the best method for evaluating patients with suspected COVID-19, presenting higher sensitivity than chest radiography. Usually, the exam is performed without the use of intravenous contrast, with contrast only being used when findings corroborate with suspicions of complications such as pulmonary thromboembolism. The main findings in CT of patients with suspected COVID-19 are ground-glass opacity, pleural thickening, inverted halo sign, mosaic pavement, reticular opacity, subpleural lines, and consolidation. On the other hand, pericardial effusion, airway changes, pulmonary nodules, lymph node enlargement, and vascular dilatation are less frequent findings in chest CT of COVID-19 patients. However, it is worth noting that lymph node enlargement, pleural effusion, and pericardial effusion are generally indicators of worse prognosis, indicating anything from decompensation of pre-existing cardiac diseases to the development of acute cardiovascular lesions (FIELDS et al., 2021). COVID-19 causes a number of impacts on the human body, whether it's clotting, inflammation, oxidation or other effects on target organs. A variety of biomarkers can be used to trace the biochemical profile of the patient who is or has had COVID-19, which can serve to analyze complications arising from this infection. As an example, we have multiple organ failure, which can result in increased troponin and other cardiac markers, and also in the elevation of alanine aminotransferase (ALT) and aspartate aminotransferase (AST), which are liver enzymes, in addition, we have other repercussions on renal markers, such as creatinine and urea, and on coagulation markers, such as prothrombin time (PT) and d-dimer (SHAMMUS et al, 2020). There are several other markers for each type of causative effect, in the case of oxidation, which is not yet a well-defined parameter for COVID-19. In these cases, by-products of oxidative stress are analyzed, such as advanced oxidation protein products (AOPPs) and 8-hydroxy-2'-deoxyguanosine (8-OHdG) (KOSANOVI et al, 2021). The body's immune responses against COVID-19 are manifested through inflammation marked by interleukin-6 (IL-6), corticosteroids such as dexamethasone, other cytokines such as IL-18, hyperactive immune responses of high CD38 expression and the expression of the isotope human leukocyte antigen (HLA-DR), among others (KOUTSAKOS, 2021). With the outbreak of the pandemic, global efforts have been directed toward developing a vaccine against the disease of COVID-19, disproportionately to any other time in public health history. Vaccination is the best way to curb the curve of contamination of new cases, being an important tool also for the attenuation of the symptomatology in people who are infected by SARS-COV-2 after receiving doses of the vaccine, in this way with the decrease in the number of infected people we will have a lower proportion of circulating virus, which also becomes effective for the prevention of the emergence of new variants of the coronavirus. (NDWANDWE & WIYSONGE, 2021). Regarding vaccination, it is important to note that this immunization is achieved when it reaches a high coverage, developing the so-called "collective immunity" or "herd immunity", that is, vaccination must be applied en masse. In addition to providing individual protection, this immunization offers indirect protection to susceptible people who often suffer from contraindications to the vaccine, such as people with compromised immunity, pregnant women, premature infants and people who have not been vaccinated for personal reasons, and this logistics is the structure of vaccination actions within public health (NDWANDWE & WIYSONGE, 2021).

The effectiveness of the vaccine may be different depending on some variants, such as: infectiousness, infection, disease outcomes and the various strains that may arise. For a correct evaluation it is important to take into account the effectiveness of the dosing schedules, the interval between each dosage and the technology used in each vaccine. (SADOFF, et al., 2021). Therefore, it is important to highlight that the evaluation of the protection of the vaccine and its side effects requires long-term studies, and it is important to adopt effective practices for the investigation of vaccines against COVID-19. Thus, the present study will seek to investigate the effects of various vaccination schedules on the population, correlated with the radiological and biochemical analysis of these patients.

## CONCLUSION

The COVID-19 pandemic caused by the SARS-CoV-2 virus has had a significant impact on global public health, infecting millions of people and causing millions of deaths worldwide. The virus is easily transmitted, and its symptoms can range from mild to severe, affecting multiple organs and systems in the body. It is important to continue practicing basic hygiene measures such as hand washing and social distancing to prevent the spread of the virus. Ongoing research is essential to better understand the virus and develop effective treatments and vaccines to control its spread and minimize its impact on human health. Therefore, regarding the biochemical profile, it is evident that laboratory tests are of fundamental importance in the evaluation of markers of systemic or localized injury and inflammation. In addition, imaging exams can reveal and suggest changes resulting from each phase of the infection. In this sense, further studies are needed to reveal a syndromic pattern that can guide the management and handling of this pathology.

## REFERENCES

- Abbas, A., Abdelsamea, M. M., & Gaber, M. M. (2021). Classification of COVID-19 in chest X-ray images using DeTraC deep convolutional neural network. *Applied Intelligence*, 51, 854-864.
- Abrishami, A., Eslami, V., Arab-Ahmadi, M., Alahyari, S., Azhideh, A., & Sanei-Taheri, M. (2021). Prognostic value of inflammatory biomarkers for predicting the extent of lung involvement and final clinical outcome in patients with COVID-19. *Journal of Research in Medical Sciences: The Official Journal of Isfahan University of Medical Sciences*, 26.
- Azevedo, R. B., Botelho, B. G., Hollanda, J. V. G. D., Ferreira, L. V. L., Junqueira de Andrade, L. Z., Oei, S. S. M. L., & Muxfeldt, E. S. (2021). Covid-19 and the cardiovascular system: a comprehensive review. *Journal of human hypertension*, 35(1), 4-11.
- Bao, C., Liu, X., Zhang, H., Li, Y., & Liu, J. (2020). Coronavirus disease 2019 (COVID-19) CT findings: a systematic review and meta-analysis. *Journal of the American college of radiology*, 17(6), 701-709.
- Behzad, S., Aghaghazvini, L., Radmard, A. R., & Gholamrezaezhad, A. (2020). Extrapulmonary manifestations of COVID-19: radiologic and clinical overview. *Clinical imaging*, 66, 35-41.
- Böger, B., Fachi, M. M., Vilhena, R. O., Cobre, A. F., Tonin, F. S., & Pontarolo, R. (2021). Systematic review with meta-analysis of the accuracy of diagnostic tests for COVID-19. *American journal of infection control*, 49(1), 21-29.
- Carpenter, C. R., Mudd, P. A., West, C. P., Wilber, E., & Wilber, S. T. (2020). Diagnosing COVID-19 in the emergency department: a scoping review of clinical examinations, laboratory tests, imaging accuracy, and biases. *Academic Emergency Medicine*, 27(8), 653-670.
- Chakraborty, C., Sharma, A. R., Sharma, G., Bhattacharya, M., & Lee, S. S. (2020). SARS-CoV-2 causing pneumonia-associated respiratory disorder (COVID-19): diagnostic and proposed therapeutic options. *Eur Rev Med Pharmacol Sci*, 24(7), 4016-4026.
- Cheng, M. P., Papenburg, J., Desjardins, M., Kanjilal, S., Quach, C., Libman, M., & Yansouni, C. P. (2020). Diagnostic testing for severe acute respiratory syndrome-related coronavirus 2: a narrative review. *Annals of internal medicine*, 172(11), 726-734.
- Cochrane Infectious Diseases Group, Stegeman, I., Ochodo, E. A., Guleid, F., Holtman, G. A., Yang, B., & Cochrane COVID-19 Diagnostic Test Accuracy Group. (1996). Routine laboratory testing to determine if a patient has COVID-19. *Cochrane Database of Systematic Reviews*, 2020(11).
- Degerli, A., Ahishali, M., Yamac, M., Kiranyaz, S., Chowdhury, M. E., Hameed, K., & Gabbouj, M. (2021). COVID-19 infection map generation and detection from chest X-ray images. *Health information science and systems*, 9(1), 15.

- Edwards, K. M., & Orenstein, W. A. (2022). COVID-19: vaccines. *Hirsch MSB, Allyson., ed. UptoDate. UptoDate.*
- Ferrari, F. (2020). COVID-19: dados atualizados e sua relação com o sistema cardiovascular. *Arquivos Brasileiros de Cardiologia, 114*, 823-826.
- Fields, B. K., Demirjian, N. L., Dadgar, H., & Gholamrezaezhad, A. (2021, July). Imaging of covid-19: Ct, mri, and pet. In *Seminars in Nuclear Medicine* (Vol. 51, No. 4, pp. 312-320). WB Saunders.
- Fox, T., Geppert, J., Dinnes, J., Scandrett, K., Bigio, J., Sulis, G., & Cochrane COVID-19 Diagnostic Test Accuracy Group. (2022). Antibody tests for identification of current and past infection with SARS-CoV-2. *Cochrane database of Systematic reviews*, (11).
- Francone, M., Iaffate, F., Masci, G. M., Coco, S., Cilia, F., Manganaro, L., & Catalano, C. (2020). Chest CT score in COVID-19 patients: correlation with disease severity and short-term prognosis. *European radiology, 30*, 6808-6817.
- Ghazanfari, T., Salehi, M. R., Namaki, S., Arabkheradmand, J., Rostamian, A., Rajabnia Chenary, M., & Faghihzadeh, S. (2021). Interpretation of Hematological, Biochemical, and Immunological Findings of COVID-19 Disease: Biomarkers Associated with Severity and Mortality. *Iran J Allergy Asthma Immunol*, 46-66.
- Hani, C., Trieu, N. H., Saab, I., Dangeard, S., Bennani, S., Chassagnon, G., & Revel, M. P. (2020). COVID-19 pneumonia: a review of typical CT findings and differential diagnosis. *Diagnostic and interventional imaging, 101*(5), 263-268.
- Islam, N., Ebrahimzadeh, S., Salameh, J. P., Kazi, S., Fabiano, N., Treanor, L., & Cochrane COVID-19 Diagnostic Test Accuracy Group. (2021). Thoracic imaging tests for the diagnosis of COVID-19. *Cochrane Database of Systematic Reviews*, (3).
- Jothimani, D., Venugopal, R., Abedin, M. F., Kaliamoorthy, I., & Rela, M. (2020). COVID-19 and the liver. *Journal of hepatology, 73*(5), 1231-1240.
- Jothimani, D., Venugopal, R., Abedin, M. F., Kaliamoorthy, I., & Rela, M. (2020). COVID-19 and the liver. *Journal of hepatology, 73*(5), 1231-1240.
- Kabir, M. A., Ahmed, R., Iqbal, S. M. A., Chowdhury, R., Paulmurugan, R., Demirci, U., & Asghar, W. (2021). Diagnosis for COVID-19: current status and future prospects. *Expert Review of Molecular Diagnostics, 21*(3), 269-288.
- Kaye, A. D., Okeagu, C. N., Tortorich, G., Pham, A. D., Ly, E. I., Brondeel, K. C., & Cornett, E. M. (2021). COVID-19 impact on the renal system: Pathophysiology and clinical outcomes. *Best Practice & Research Clinical Anaesthesiology, 35*(3), 449-459.
- KOSANOVIC, Tijana et al. Time course of redox biomarkers in COVID-19 pneumonia: relation with inflammatory, multiorgan impairment biomarkers and CT findings. *Antioxidants*, v. 10, n. 7, p. 1126, 2021.
- Koutsakos, M., Rowntree, L. C., Hensen, L., Chua, B. Y., Van De Sandt, C. E., Habel, J. R., & Kedzierska, K. (2021). Integrated immune dynamics define correlates of COVID-19 severity and antibody responses. *Cell Reports Medicine, 2*(3), 100208.
- Manna, S., Wruble, J., Maron, S. Z., Toussie, D., Voutsinas, N., Finkelstein, M., & Bernheim, A. (2020). COVID-19: a multimodality review of radiologic techniques, clinical utility, and imaging features. *Radiology: Cardiothoracic Imaging, 2*(3), e200210.
- Ndwandwe, D., & Wiysonge, C. S. (2021). COVID-19 vaccines. *Current opinion in immunology, 71*, 111-116.
- Piechotta, V., & Harder, T. (2022). Waning of COVID-19 vaccine effectiveness: individual and public health risk. *The Lancet, 399*(10328), 887-889.
- Pontone, G., Scafuri, S., Mancini, M. E., Agalbato, C., Guglielmo, M., Baggiano, A., & Rossi, A. (2021). Role of computed tomography in COVID-19. *Journal of cardiovascular computed tomography, 15*(1), 27-36.
- Rodriguez-Morales, A. J., Cardona-Ospina, J. A., Gutiérrez-Ocampo, E., Villamizar-Peña, R., Holguin-Rivera, Y., Escalera-Antezana, J. P., & Sah, R. (2020). Clinical, laboratory and imaging features of COVID-19: A systematic review and meta-analysis. *Travel medicine and infectious disease, 34*, 101623.
- Sadoff, J., Le Gars, M., Shukarev, G., Heerwegh, D., Truyers, C., de Groot, A. M., & Schuitemaker, H. (2021). Interim results of a phase 1-2a trial of Ad26. COV2. S Covid-19 vaccine. *New England Journal of Medicine, 384*(19), 1824-1835.
- Santana, A. V., Fontana, A. D., & Pitta, F. (2021). Reabilitação pulmonar pós-COVID-19. *Jornal brasileiro de Pneumologia, 47*.
- Shammus, R., Mahbub, S., Rauf, M. A., & Harky, A. (2020). The role of imaging and other diagnostic approaches in COVID-19. *Acta Bio Medica: Atenei Parmensis, 91*(3), e2020019.
- Shan, S., Guangming, L., Wei, L., & Xuedong, Y. (2020). Spontaneous pneumomediastinum, pneumothorax and subcutaneous emphysema in COVID-19: case report and literature review. *Revista do Instituto de Medicina Tropical de São Paulo, 62*.
- Tan, C., Huang, Y., Shi, F., Tan, K., Ma, Q., Chen, Y., & Li, X. (2020). C-reactive protein correlates with computed tomographic findings and predicts severe COVID-19 early. *Journal of medical virology, 92*(7), 856-862.
- Tsou, I. Y. Y., Liew, C. J. Y., Tan, B. P., Chou, H., Wong, S. B. S., Loke, K. S. H., & Tay, K. H. (2020). Planning and coordination of the radiological response to the coronavirus disease 2019 (COVID-19) pandemic: the Singapore experience. *Clinical radiology, 75*(6), 415-422.
- Udugama, B., Kadhiresan, P., Kozlowski, H. N., Malekjahani, A., Osborne, M., Li, V. Y., & Chan, W. C. (2020). Diagnosing COVID-19: the disease and tools for detection. *ACS nano, 14*(4), 3822-3835.
- Wang, Q. J., Yao, Y. Z., Song, J. S., Wang, Q., Xu, L. Y., Bao, Z. J., & Li, S. B. (2020). Kinetic changes in virology, specific antibody response and imaging during the clinical course of COVID-19: a descriptive study. *BMC Infectious Diseases, 20*(1), 1-11.
- Wang, Y., Dong, C., Hu, Y., Li, C., Ren, Q., Zhang, X., & Zhou, M. (2020). Temporal changes of CT findings in 90 patients with COVID-19 pneumonia: a longitudinal study. *Radiology, 296*(2), E55-E64.
- Ye, Z., Zhang, Y., Wang, Y., Huang, Z., & Song, B. (2020). Chest CT manifestations of new coronavirus disease 2019 (COVID-19): a pictorial review. *European radiology, 30*, 4381-4389.
- Yu, J., Azzam, E. I., Jadhav, A. B., & Wang, Y. (2021). COVID-19: The disease, the immunological challenges, the treatment with pharmaceuticals and low-dose ionizing radiation. *Cells, 10*(9), 2212.
- ZHANG, Jin-jin et al. Clinical, radiological, and laboratory characteristics and risk factors for severity and mortality of 289 hospitalized COVID-19 patients. *Allergy, v. 76, n. 2, p. 533-550, 2021.*

\*\*\*\*\*