




ISSN: 2230-9926

Available online at <http://www.journalijdr.com>

# IJDR

International Journal of Development Research  
Vol. 13, Issue, 02, pp. 61649-61651, February, 2023  
<https://doi.org/10.37118/ijdr.26243.02.2023>



RESEARCH ARTICLE

OPEN ACCESS

## RARE VARIATIONS IN BRACHIAL PLEXUS

Dr. Preeti Shivshankar Awari\*<sup>1</sup> and Mr. Harsh Sudhakar Pandey<sup>2</sup>

<sup>1</sup>Associate Professor, Department of Anatomy, Dr.D.Y.Patil Medical College, Hospital and Research Centre, Dr. D.Y. Patil Vidyapeeth (Deemed to be University), Pune, Maharashtra, India; <sup>2</sup>1<sup>st</sup> year MBBS student, Dr.D.Y.Patil Medical College, Hospital and Research Centre, Pune

### ARTICLE INFO

#### Article History:

Received 02<sup>nd</sup> January, 2023  
Received in revised form  
26<sup>th</sup> January, 2023  
Accepted 09<sup>th</sup> February, 2023  
Published online 25<sup>th</sup> February, 2023

#### KeyWords:

Brachial plexus, Regional anesthesia,  
Median nerve.

#### \*Corresponding author:

Dr. Preeti Shivshankar Awari

### ABSTRACT

In the dissection hall while doing routine cadaveric dissection as part of learning human anatomy in a medical college authors noted variations in both sided brachial plexus .On the right side a single cord of brachial plexus was present in a cadaver branching into all nerves to the upper extremity. This cord was related to second part of axillary artery above it. In the left axilla middle trunk was absent, medial cord was absent. Median and ulnar nerve were originating from the posterior cord passing deep to 3<sup>rd</sup> part of axillary artery. Clinicians should be aware of these variations while doing various invasive and noninvasive diagnostic and surgical interventions in relation with brachial plexus and other structures in vicinity of it.

Copyright©2023, Dr. Preeti Shivshankar Awari and Mr. Harsh Sudhakar Pandey. This is an open access article distributed under the Creative Commons Attribution License, which permits unrestricted use, distribution, and reproduction in any medium, provided the original work is properly cited.

Citation: Dr. Preeti Shivshankar Awari and Mr. Harsh Sudhakar Pandey. 2023. "Rare variations in brachial plexus", International Journal of Development Research, 13, (02), 61649-61651.

## INTRODUCTION

Brachial plexus variant anatomy cannot be overlooked as various interventions (radical neck dissection, removal of axillary group of lymph nodes brachial plexus block in regional anesthesia, shoulder arthroscopy, open reduction and fixation in fracture surgical neck of humerus, nerve entrapment syndromes involving different branches of brachial plexus), in relation with brachial plexus and various structures in vicinity of it has gained momentum over the period of time. Acknowledging vary basics of topographic anatomy in relation with any peripheral nerve or plexus of nerves is the fundamental requirement to give regional anesthesia. Spread of anesthetic agent in case of the local anesthesia may get interrupted if anatomical variations are present in that specific region (1,2,3,4,5). While doing routine dissection in a Medical College the authors noticed rarely noted variations in the formation and branching pattern of brachial plexus in both right and left upper extremity. Presence of single cord of brachial plexus and origin of median nerve, ulnar nerve, medial cutaneous nerve of arm and forearm from posterior cord of brachial plexus are quiet rare variations. So the authors studied in detail the brachial plexus anatomy and variation in the cadaver. Same is discussed in detail in this article.

#### Observations

**In the right upper extremity:** Upper trunk of brachial plexus was formed by joining of C5, and C6 nerve roots.

The lower trunk was formed by joining of C7, C8 and T1 nerve roots. Middle trunk was absent. As the trunks entered in axilla they were located lateral to the first part of axillary artery. Deep to pectoralis minor, instead of dividing into the divisions the trunks joined to form single cord which was crossing the 2<sup>nd</sup> part of axillary artery from lateral to medial side, passing above it.

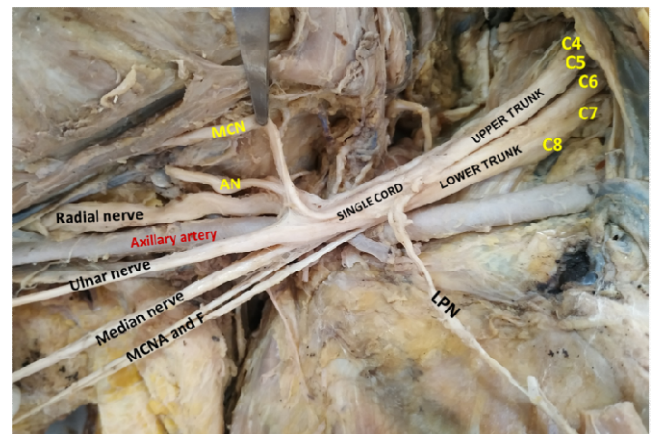
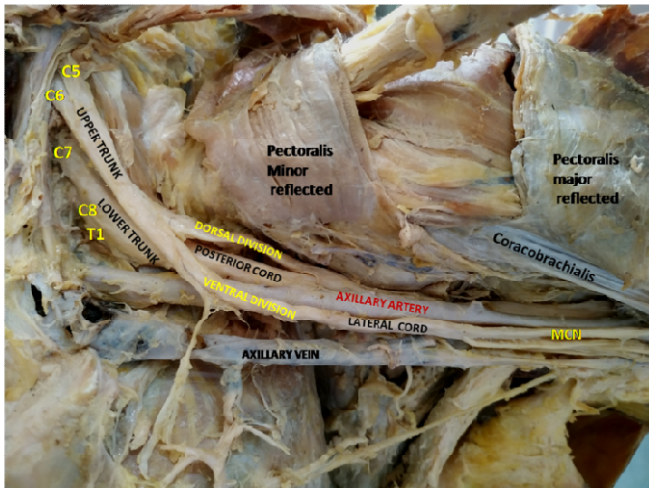


Figure 1. Single cord of brachial plexus dividing into musculocutaneous nerve (MCN), axillary nerve (AN), Radial nerve, Ulnar nerve, Median nerve, Medical cutaneous nerve of arm and forearm (MCNAF)

Then the single cord divided into axillary nerve, radial nerve, musculocutaneous nerve, median nerve, ulnar nerve, medial cutaneous nerve of arm, medial cutaneous nerve of forearm. All these branches are related to the 3<sup>rd</sup> part of the axillary artery. Axillary nerve, radial nerve are lateral to artery. Musculocutaneous nerve above and then going lateral to artery. The median nerve, ulnar nerve and medial cutaneous nerve of arm, medial cutaneous nerve of forearm passing medial to artery. Medial and lateral root of median nerve are absent.

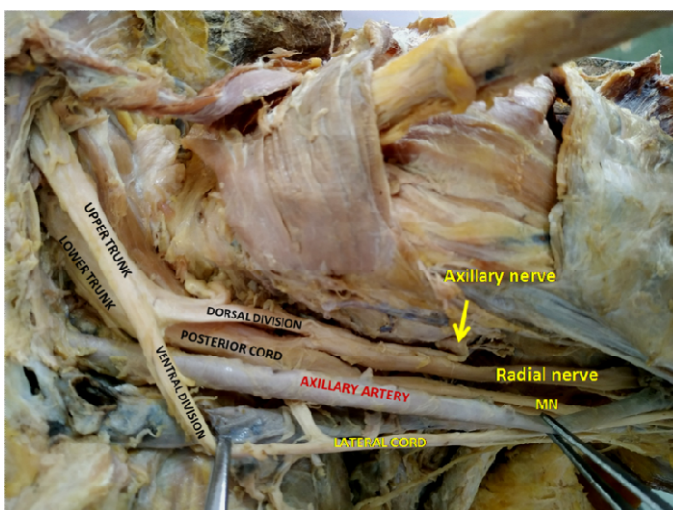
**In the left upper extremity:** Upper trunk formed by joining of C5, and C6 nerve roots. The lower trunk is formed by joining of C7, C8 and T1 nerve roots.



**Figure 2.** Absent middle trunk Lower trunk formed by C7,8,T1 Lower trunk continuing as posterior cord MCN: Musculocutaneous nerve

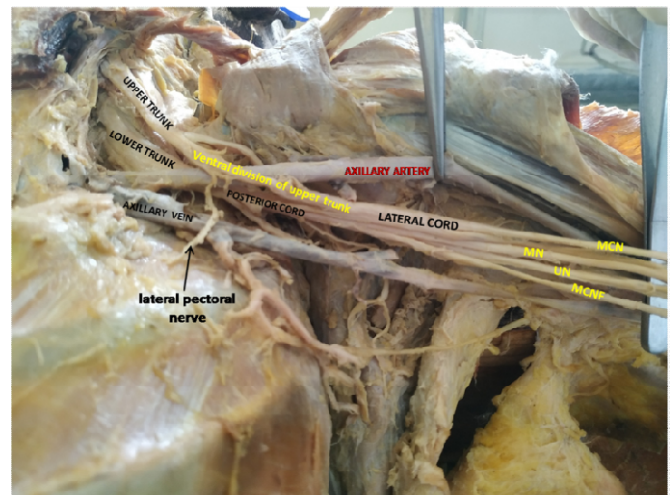
- Middle trunk was absent.
- The upper trunk was dividing into ventral and dorsal divisions.
- The divisions were then passing deep to pectoralis minor.

The lower trunk did not divide into dorsal and ventral divisions; instead it continued as posterior cord. The posterior cord was giving out a branch which is joining with the dorsal division of upper trunk. This unnamed branch is dividing into axillary and radial nerve.



**Figure 3.** A branch from posterior cord uniting with dorsal division of upper trunk to divide into axillary and radial nerves Ventral division of upper trunk continuing as lateral cord

Then the main posterior cord was continuing to divide into median nerve, ulnar nerve, medial cutaneous nerve of forearm, and a small branch which is joining with musculocutaneous nerve (Figure 4).



**Figure 4.** Posterior cord giving origin to median nerve (MN), ulnar nerve (UN), medial cutaneous nerve of forearm (MCNF)

The medial cord was absent.

The ventral division of upper trunk continued as lateral cord. Same is receiving a branch from posterior cord at the junction of 1<sup>st</sup> and 2<sup>nd</sup> part of axillary artery. This branch is running deep to the axillary artery. The lateral cord is dividing into musculocutaneous nerve and a branch to join median nerve.

## DISCUSSION

Presence of single cord of brachial plexus on the right side in the cadaver was noted by the authors. Anjali Aggarwal et al (Year 2012) found that single cord of brachial plexus was present in 4.4% of dissected specimens (6). Authors did extensive search on internet by using Google search engine, but could not find any other study mentioning about incidence of presence of single cord of brachial plexus. Authors, Meenakshisundaram J et al (Year 2012), Hasan M et al (Year 1964), Singer E et al (Year 1933) have reported cases of presence of single cord of brachial plexus (7,8,9). The normal anatomy states that medial cord is medial to axillary artery, lateral cord is lateral to the artery, posterior cord is deep to the axillary artery deep to pectoralis minor muscle. This arrangement helps anesthetists to infiltrate the anesthetic agent at these positions to give infraclavicular brachial plexus block (10). In presence of this kind of variation the anesthetic agent should be infiltrated superior to the axillary artery. On the left side the medial cutaneous nerve of arm and forearm, the ulnar nerve and median nerve were arising from the posterior cord of brachial plexus. They were posterior to the 3<sup>rd</sup> part of axillary artery. If this kind of variation is present in a person in whom the clinician wants to block these nerves; to anesthetize them the needle should be passing deep to the axillary artery. Knowing about variations in brachial plexus formation and branching is at most importance for clinicians, as for neurologists to diagnose and treat any disorder related to it, for radiologists to identify variant structure on ultrasonography while doing USG guided interventions, for anesthetists to improvise the regional block techniques in presence of variant anatomy and for surgeons to minimize chances of morbidity by identifying anatomical variant structure and doing necessary changes in plan of surgery (11).

## CONCLUSION

Even though many articles are published on variant anatomy of brachial plexus, we notice variations which are rarely mentioned anywhere. Clinicians should be aware of these kind variations to improvise on various invasive and noninvasive diagnostic and surgical interventions in relation with brachial plexus and other structures in vicinity of it.

**Conflicts of interest:** none.

**Acknowledgement:** Authors would like to thank the soul of human cadaver who allowed us to dissect and learn Anatomy. We would like to pray for the soul to find the purpose. We also thank the staff of our department of Anatomy of Dr. D Y Patil Medical College, Hospital and Research Center, Dr D Y Patil Vidyapeeth, Pune, India.

## REFERENCES

- Anjali Aggarwal, Daisy Sahni, Harjeet Kaur, Yatindra Kumar Batra, MD, and Rakesh V. Sondekoppam, A Rare Anatomical Variation of the Brachial Plexus: Single Cord Anomaly, February 2012 • Volume 114 • Number 2
- Hasan M, Narayan D. A single cord human brachial plexus. Journal of Anatomical society of India ,1964;13:103-4
- Kim HJ, Park SH, Shin HY, Choi YS. Brachial plexus injury as a complication after nerve block or vessel puncture. Korean J Pain. 2014 Jul;27(3):210-8. doi: 10.3344/kjp.2014.27.3.210. Epub 2014 Jun 30. PMID: 25031806; PMCID: PMC4099233.
- Sweekritha, Sultana Q, Pillai V, Rao CP. A rare case of variation of the cords of brachial plexus. *Int J A J Inst Med Sci* 2012;1:75-7
- Meenakshisundaram J. A single common cord in the infraclavicular part of the brachial plexus. *Int J Health Sci Res* 2012; 2:108-11.
- Oluyemi KA, Adesanya OA, Ofusori DA, Okwuonu CU, Ukwenya VO, Om' iniabohs FA , Odion BI : Abnormal pattern of Brachial plexus Formation : An Original Case Report. *The Internet Journal of Neurosurgery* 2007; 4: Number 2
- Orebaugh SL, Williams BA. Brachial plexus anatomy: normal and variant. *ScientificWorldJournal*. 2009 Apr 28;9:300-12. doi: 10.1100/tsw.2009.39. PMID: 19412559; PMCID: PMC5823154.
- Pester JM, Hendrix JM, Varacallo M. Brachial Plexus Block Techniques. 2022 Nov 30. In: StatPearls [Internet]. Treasure Island (FL): StatPearls Publishing; 2022 Jan-. PMID: 29262036
- Singer E. Human brachial plexus united into a single cord: description and interpretation. *Anat Rec* 1933;55:411-9
- Vendhan Ramanujam , Patrick Van Kirk, Anatomy variation of brachial plexus trunks during supraclavicular nerve block: clinical image, *Brazilian Journal of Anesthesiology* 2022;72(6): 834-835
- Z. Karaca Bozdağ Et Al. , A Rare Variation of the Brachial Plexus Involving The Trunks and Cords: A Case Report, *Istanbul Yeni Yuzyil Universitesi, Yeni Yuzyil Journal of Medical Sciences* , vol.3, no.3, pp.195-198, 2022

\*\*\*\*\*