



ISSN: 2230-9926


Available online at <http://www.journalijdr.com>

IJDR

International Journal of Development Research

Vol. 12, Issue, 10, pp. 59384-59386, October, 2022

<https://doi.org/10.37118/ijdr.25459.10.2022>



RESEARCH ARTICLE

OPEN ACCESS

PITYRIASIS LICHENOIDES AND ACUTE VARIOLIFORMIS (PLEVA): A CASE REPORT AFTER OROPHARYNGEAL INFECTION

Jadson Henrique Braga dos Santos*¹, Larissa de Carvalho Sá Falcão¹, Maykin da Silva Amorim¹, João Paulo da Silva¹ and Tânia Rita de Oliveira Moreno Fernandes²

¹School of Medicine, Federal University of Vale do São Francisco; ²Adjunct Professor of Dermatology at School of Medicine, Federal University of Vale do São Francisco

ARTICLE INFO

Article History:

Received 20th August, 2022

Received in revised form

11th September, 2022

Accepted 28th September, 2022

Published online 22nd October, 2022

Key Words:

Pityriasis Lichenoides. PLEVA.

Oropharyngeal Infection. Methotrexate.

*Corresponding author:

Jadson Henrique Braga dos Santos

ABSTRACT

A 21-year-old male patient presented, ten days after infection of the oropharynx, with papulo-erythematous desquamative lesions that rapidly spread to the trunk and limbs, and rapidly evolved to vesicular papulonecrotic lesions, without systemic repercussions. Forty days after the onset of the clinical picture, he underwent the consultation that originated the current case report. He was hospitalized, biopsied, and the diagnosis of acute lichenoid and varioliform pythiasis was confirmed, with a favorable outcome after the use of corticoid and methotrexate.

Copyright © 2022, Jadson Henrique Braga dos Santos et al. This is an open access article distributed under the Creative Commons Attribution License, which permits unrestricted use, distribution, and reproduction in any medium, provided the original work is properly cited.

Citation: Jadson Henrique Braga dos Santos, Larissa de Carvalho Sá Falcão, Maykin da Silva Amorim, João Paulo da Silva and Tânia Rita de Oliveira Moreno Fernandes, 2022. "Pityriasis lichenoides and acute varioliformis (pleva): a case report after oropharyngeal infection", *International Journal of Development Research*, 12, (10), 59384-59386.

INTRODUCTION

Pityriasis lichenoides (PL) is an infrequent, acquired, benign inflammatory dermatosis with a self-injurious tendency. It can be classified into acute (PLEVA), chronic (PLC), and a febrile ulceronecrotic variant (Mucha-Habermann disease). It is estimated to occur in 1/2000 population, is more frequent in children and young adults, with a slight predominance in males. Twenty percent of cases occur before the age of ten years (peak frequency between five and ten years) (Zegpi *et al.*, 2015). PLEVA is characterized by the appearance of a polymorphic eruption consisting of grayish erythematous papules 3-5 mm in diameter, covered by fine scales and coalescing into plaques. As the disease progresses, vesicles and/or pustules appear that become umbilicated and progress to hemorrhagic necrosis, resulting in purpuric and keratotic lesions that, if removed, reveal necrotic ulcers. The necrotic lesions heal within several weeks, leaving hypopigmented atrophic patches. Recurrences may occur and systemic symptoms are rarely present (Zegpi *et al.*, 2015; Merlotto *et al.*, 2020).

CASE REPORT

A 21-year-old caucasian male reported that 40 days before the current visit and 10 days after presenting fever (not measured), oropharyngeal pain and flu symptoms, he noticed erythematous patches on his thighs and torso (Fig. 1), which evolved with desquamation, vesicles and blisters. He was then medicated with prednisone 20 to 40 mg/day for a short period of time, hydroxyzine, promethazine, acyclovir 400mg five times a day, amoxicillin/clavulanate, dexamethasone, and dapsone, and topical betamethasone associated with gentamicin, water paste, and silver sulfadiazine. On current physical examination, he presented bullous, vesicular lesions, some with serous content, and papules with a necrotic center, sometimes with a varioliform appearance and widespread crusted lesions. Lesions were sparing only the face (Fig. 2). Pityriasis lichenoides et varioliformis acute (PLEVA), was the clinical diagnostic suspicion, with subsequent characteristic histopathological (Fig. 3). At the time of the consultation, he had the exams: tgo, tgp, serum ige, urea, creatinine, erythro and leukogram – all normal, except platelets – 134 (vn- 150 to 400).

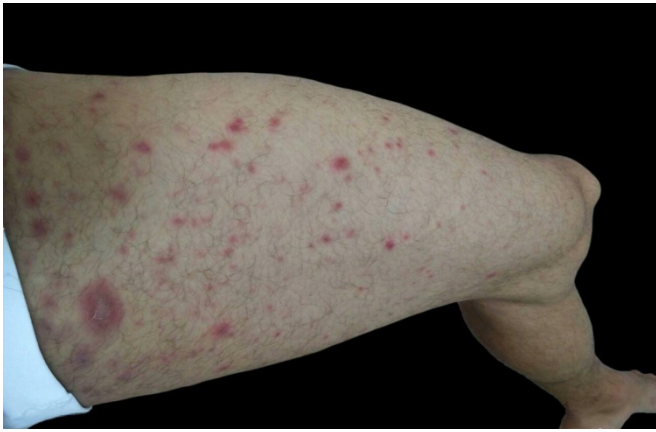


Figure 1. Picture brought by the patient, revealing the initial lesions, composed of erythematous papules, some with slight scaling on the thighs that were similar to lesions in trunk and abdomen

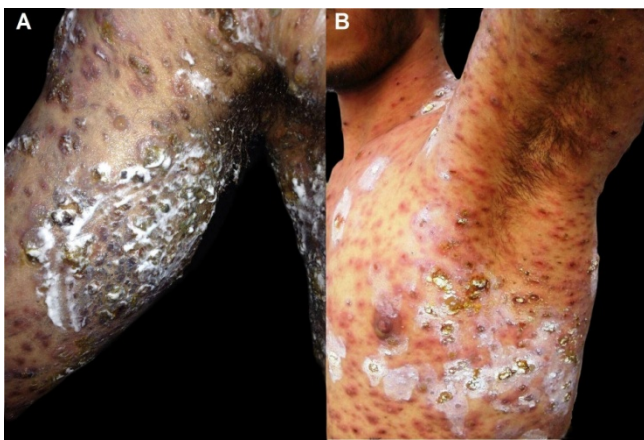


Figure 2. Cutaneous Lesions on the day of consultation-erythematous, crusted papules, vesicles with serous content and varioliform appearance, crusts and polymorphic lesion, some covered with a white residue of water paste localized on the arms (A), axillae and trunk (B)

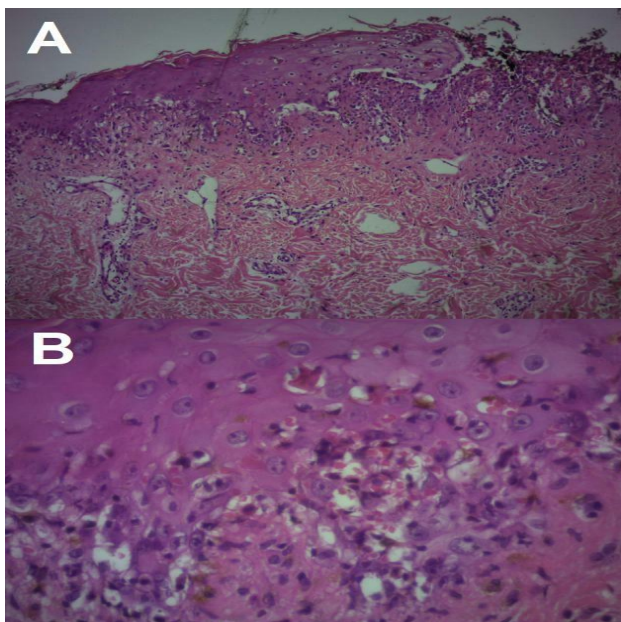
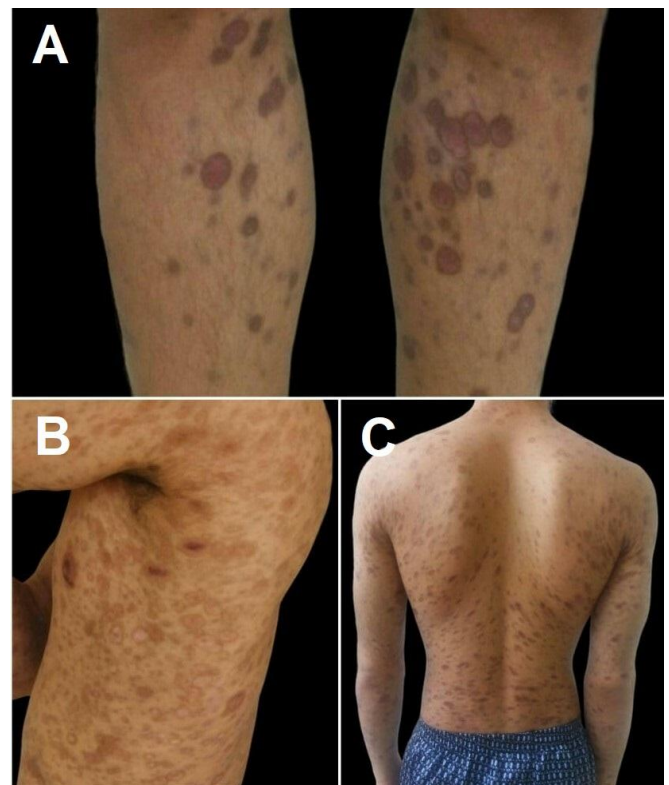


Figure 3. A (10x magnification) and B (40x magnification)-microphotography. HE: superficial inflammatory infiltrate attacking the basal layer of the epidermis, where vacuolization of the same is also noted. Presence of necrotic keratinocytes and apoptotic bodies, extravasation of red blood cells and cornel layer with paraceratosis and neutrophilic aggregates. Magnification: 3A 10 X and 3B 40X.

At this time, serology for HIV 1 and 2, IGM for herpes simplex, HCV and total HBC was requested - all were negative. The patient was hospitalized with a prescription for prednisone 60 mg/day, ciprofloxacin and, topically, potassium permanganate and vaseline bandage to cover the lesions. The patient was discharged after 15 days, showing significant improvement, and was advised to gradually wean off the corticosteroid. When on 20 mg of prednisone, there was recrudescence of a few lesions, this dose was maintained and associated with methotrexate (MTX) 10 mg/week, namely 2.5 mg every 12 hours on two consecutive days, repeating this dosage weekly and folic acid 5 mg for 2 days/week. After 6 weeks of MTX use, the disease was no longer active. After wards weaning from corticosteroids was continued for five weeks and weaning from MTX was started. The patient was discharged as an outpatient without medication. In periodic follow-up for another year, he remained with only residual patches (Fig. 4).



Source: The authors.

Figure 4. A - Residual spots and atrophic scars on knees and legs after treatment. B - Brownish residual spots and trophic lesions on trunk and arms, after treatment. C - Residual spots and atrophic scars on trunk

DISCUSSION

There are three accepted theories to explain the pathogenesis of PL. The first one states that it would be an inflammatory reaction triggered by extrinsic antigens, such as: infectious agents (HIV, cytomegalovirus, Epstein-Barr virus, parvovirus B19, Toxoplasma gondii, Mycoplasma, and Staphylococcus); drugs (hormone therapy with estrogen-progesterone and chemotherapeutic agents); and vaccine (triple viral - mumps, measles, and rubella). The second hypothesis discusses its lymphoproliferative origin. Some authors have demonstrated the loss of mature CD2, CD3 and CD5 T cell antigens in PL, in addition to clonal T cell proliferation in 50% of the cases of PLEVA (association with Hodgkin's lymphoma and lymphomatoid papulosis). Finally, some authors have demonstrated the presence of a component of immune complex-mediated vasculitis (Castro et al., 2015; Araújo et al., 2021). From the patient's history at the first visit, the trigger of the disease was most likely the infectious process presented ten days before the skin lesions and consisted of oropharyngeal pain and flu-like symptoms.

The histopathology of this disease consists of dermal findings: edema with moderately dense lymphohistiocytic infiltrate in a wedge shape, which extends to the reticular dermis and the dermoepidermal junction, besides extravasation of lymphocytes and erythrocytes. The epidermis shows focal and confluent parakeratosis, spongiosis, dyskeratosis, mild to moderate acanthosis, vacuolization of the basal layer, and necrotic keratinocytes. The inflammatory infiltrate may extend into this layer with migration of lymphocytes and erythrocytes. Vascular changes correspond to vessel dilatation in the papillary dermis with endothelial proliferation, vascular congestion, occlusion, bleeding, and extravasation of erythrocytes. The vessels may be invaded by inflammatory infiltrate with fibrin deposits, very rarely there is leukocytoclasia (Khachemoune & Blyumin, 2007; Sisnando et al., 2015; Alonzo-Romero et al., 2017). Findings found in the histopathological analysis of the skin biopsy of the patient in report. When possible, an immunohistochemical examination should be performed, which shows an inflammatory infiltrate predominantly composed of CD8 T cells. Although the diagnosis of this disease is predominantly clinical, skin biopsy is indispensable for confirmation, in view of the extensive range of differential diagnoses, such as psoriasis drops, lichen planus, pityriasis rosea, viral or drug eruptions, polymorphous erythema, small vessel vasculitis, secondary syphilis, papulonecrotic tuberculosis, and lymphomatoid papulosis. The authors, from previous case experience, immediately suggested the diagnostic hypothesis of PLEVA and had histopathological confirmation. A thorough clinical history, followed by a complete histological study and, if possible, immunophenotyping, is imperative, considering the potential for malignant transformation of PLEVA (Alonzo-Romero et al., 2017). As for clinical management, although there is no specific treatment, topical corticosteroids, antibiotics - tetracyclines, erythromycin, azithromycin and dapsone - immunomodulators - such as tacrolimus - and phototherapy have been used. In cases resistant to the therapies mentioned, methotrexate (MTX), acitretin and cyclosporine, as well as systemic corticosteroids can be used (Araújo et al., 2021; Dantas & Egypto, 2021; Van et al., 2019). Our patient benefited from the use of corticosteroids at an effective dose and the introduction of MTX when the lesions recurred.

CONCLUSION

Although it's a rare disease, early correct diagnosis and therapy minimize the damage to patients' life. We should consider this serious pathology in patients with suggestive skin lesions. Skin biopsy is very important for diagnostic clarification and the establishment of effective therapy.

REFERENCES

- Alonzo-Romero, P. M. L., Navarrete-Franco, G., Aquino-Pérez, C., & Figueroa-Benítez, E. (2017). Pityriasis liquenoide y varioliforme aguda. *Revista del Centro Dermatológico Pascua*, 26(3), 104-108. <https://www.medigraphic.com/pdfs/derma/cd-2017/cd173e.pdf>
- Araújo, L. R., Bastos, F. S., Oliveira, H. L. F., Paixão, A. P., Santos, J. B., & Barreto, E. M. (2021). Pityriase liquenoide e varioliforme aguda: sucesso terapêutico com doxiciclina. *Revista Científica Hospital Santa Izabel*, 5(3), 148-151. <https://doi.org/10.35753/rchsi.v5i3.219>
- Castro, B. A. C., Meyer, R. L. B., Pedrosa, M. S., Pereira, J. M. M., Trindade, F. M., & Pianscatelli, A. C. C. (2015). Pityriasis liquenoide e varioliforme aguda após vacina contra Influenza. *Anais Brasileiros de Dermatologia*, 90(3 Suppl 1), 178-181. <http://dx.doi.org/10.1590/abd1806-4841.20153492>
- Dantas, I. C. M., & Egypto, L. V. (2021). Pityriase liquenoide e Varioliforme aguda—doença do Mucha-habermann: um relato de caso. *Brazilian Journal of Development*, 7(2), 19755-19762. <https://doi.org/10.34117/bjdv7n2-561>
- Khachemoune, A., & Blyumin, M. (2007). Pityriasis lichenoides: pathophysiology, classification, and treatment. *American Journal of Clinical Dermatology*, 8(1), 29-36. <https://doi.org/10.2165/00128071-200708010-00004.55>
- Merlotto, M. R., Bicudo, N. P., Marques, M. E. A., & Marques, S. A. (2020). Pityriase liquenoide e varioliforme aguda após vacinação antitetânica e antidiftérica do adulto. *Anais Brasileiros de Dermatologia*, 95(2), 259-260. <http://dx.doi.org/10.1016/j.abdp.2019.06.009>
- Sisnando, A. S., Agonio, B., Madeira, L., & Francesconi, F. (2015). Pityriasis lichenoides - Relato de dois casos que evidenciam o variado espectro de apresentação desta rara doença. *Revista da Sociedade Portuguesa de Dermatologia e Venereologia*, 73(3), 383-387. <https://revista.spdv.com.pt/index.php/spdv/article/download/463/361/>
- Van, T. N., Thi, T. N., Huu, D. L., Huu, N. D., Thi, M. L., Minh, T. N., Huyen, M. L., Gandolfi, M., Satolli, F., Feliciani, C., Tirant, M., Vojvodic, A., & Lotti, T. (2019). Clinical aspects and treatment of pityriasis lichenoides et varioliformis acuta: a retrospective Vietnamese study. *Open Access Macedonian Journal of Medical Sciences*, 7(2), 198-199. <https://doi.org/10.3889/oamjms.2019.005>
- Zegpi, T. M. S., Ruiz, M. F., & Porras, K. N. (2015). Pityriasis liquenoide: presentación de un caso clínico y revisión de la literatura. *Revista Chilena de Pediatría*, 86(2), 121-125. <http://dx.doi.org/10.1016/j.rchipe.2015.04.024>