



ISSN: 2230-9926

Available online at <http://www.journalijdr.com>

# IJDR

*International Journal of Development Research*  
Vol. 12, Issue, 01, pp. 53396-53398, January, 2022

<https://doi.org/10.37118/ijdr.23790.01.2022>



RESEARCH ARTICLE

OPEN ACCESS

## FOREIGN BODY IN THE NOSE, EAR AND OROPHARYNX OF CHILDREN AND ADOLESCENTS TREATED IN A PUBLIC REFERENCE HOSPITAL

\*Felipe da Silva Braz, Mateus Capuzzo Gonçalves, Hugo Valter Lisboa Ramos, Nathalya Rodrigues de Queiroz, Sarah Vidal da Silva, Jholbert Cardoso Santana, Taynara Luisa de Mello Heliodoro, Mikhael Romanholo El Ckeikh and Claudiney Candido Costa

Otorhinolaryngology Division, Head and Neck Surgery Unit, Clinical Hospital of Federal University of Goiás (HC-UFG - Hospital das Clínicas da Universidade Federal de Goiás), Goiânia City, Goiás State, Brazil.

### ARTICLE INFO

#### Article History:

Received 20<sup>th</sup> October, 2021  
Received in revised form  
27<sup>th</sup> November, 2021  
Accepted 09<sup>th</sup> December, 2021  
Published online 30<sup>th</sup> January, 2022

#### Key Words:

Foreign bodies; Nose; Ears;  
Throat; Otorhinolaryngology.

#### \*Corresponding author:

Felipe da Silva Braz

### ABSTRACT

**Introduction:** The aim of the current prospective study is to feature the service provided to 0-19-year-old patients diagnosed with foreign body in the nose, ear or oropharynx, in a public reference hospital, from February 2017 to November 2019. **Methods:** All 232 patients were subjected to full otorhinolaryngological examination before the foreign body was removed; patients' data such as age, sex, time of evolution with foreign body, foreign body site and type, and complications were recorded in a form developed by the service itself. **Results:** Foreign bodies prevailed in male preschoolers presenting time of evolution ranging from 1 to 30 days; the main site was the ear, which was followed by nose and oropharynx; the main foreign body types were seeds and plastic materials; isolated bleeding was the main complication. **Conclusions:** Based on the most affected age groups and on the prevalence of foreign bodies often found in home environments, it is possible stating that preschoolers and schoolchildren's family members should always be attentive in order to avoid foreign body-related issues in children. In addition, these patients must be properly managed by trained health professionals to help decreasing complication indices.

Copyright © 2022, Felipe da Silva Braz, et al. This is an open access article distributed under the Creative Commons Attribution License, which permits unrestricted use, distribution, and reproduction in any medium, provided the original work is properly cited.

**Citation:** Felipe da Silva Braz, Mateus Capuzzo Gonçalves, Hugo Valter Lisboa Ramos, Nathalya Rodrigues de Queiroz, Sarah Vidal da Silva, Jholbert Cardoso Santana, Taynara Luisa de Mello Heliodoro, Mikhael Romanholo El Ckeikh and Claudiney Candido Costa, "Foreign body in the nose, ear and oropharynx of children and adolescents treated in a public reference hospital", *International Journal of Development Research*, 12, (01), 53396-53398.

## INTRODUCTION

The incidence of foreign bodies in individuals' nose, ear or oropharynx is often reported in medical consultations in the Otorhinolaryngology, Pediatrics and Psychiatry fields, as well as in emergency rooms and basic healthcare services (Awad, 2018). This issue is mainly observed in younger children due to several factors such as starting to handle objects with their own hands and curiosity to explore body holes – these factors are considered voluntary cases. Educational, social and cultural factors also influence the incidence of foreign bodies in children. However, there are also accidental cases, such as the ones involving living creatures, with emphasis on insects (Shrestha, 2012). Most cases evolve with mild, or without, complications. However, some foreign bodies can evolve to more severe clinical pictures such as necrosis in nasal mucosa caused by chemical agents; tympanic membrane perforations and deafness caused by foreign bodies inserted in the ear; as well as cough, noisy breathing and bronchoaspiration - in cases of foreign bodies found in the oropharynx, which can lead to death (Pecorari, 2014). Overall, complications are associated with delay in seeking medical attention, with exaggerated manipulation by inexperienced professionals

(mainly in cases of foreign bodies found in the ear) who end up moving the foreign body closer to the tympanic membrane and / or causing edema of the external auditory conduit, as well as with lack of proper healthcare network integration (De, 2018). These complications are also associated with foreign body-related factors such as chemical composition and dimension (Pecorari, 2014). The age group-based distribution observed in the literature shows prevalence of the investigated issue in preschool children. Overall, the ear is the most prevalent foreign body site; it is followed by nose and oropharynx, respectively (Raj, 2019; Sidibé, 2021). The aim of the current study was to feature the healthcare provided to children and adolescents - diagnosed with foreign body in their nose, ear and oropharynx - who have sought medical care in the otorhinolaryngology service of a public reference hospital.

## MATERIALS AND METHODS

Prospective study carried out from February 2017 to November 2019 with patients diagnosed with foreign body in their nose, ear or oropharynx, who have sought medical care in the otorhinolaryngology service of the Clinical Hospital of Federal

University of Goiás. All individuals were subjected to full otorhinolaryngological examination before the foreign body was removed; patients' age, sex, time of evolution with foreign body, foreign body site and type, and complication data were recorded in a form developed by the service itself. Only patients in the age group 0-19 years were included in the study. Materials used to remove the foreign bodies comprised nasal and ear specula, flexible and rigid optical fibers, Kelly and bayonet tweezers, Hartmann and alligator forceps, hooks, ear irrigation syringes, microscope and ear vacuuming. The age group of the investigated children and adolescents was subdivided as follows: 0 to 2 years incomplete (infants), 2 to 4 years (preschoolers), 5 to 10 years (schoolchildren), 11 to 19 years (adolescents), based on the Brazilian Pediatrics Society (SBP, 2014). Results were subjected to statistical analysis in SPSS Statistics 20 software.

## RESULTS

In total, 232 patients diagnosed with foreign body were treated in the investigated hospital: 111 belonged to the female sex (47.1%) and 121, to the male one (52.9%). All foreign bodies were removed at the otorhinolaryngology service of the Clinical Hospital of Federal University of Goiás. Only 5 cases required surgical procedure (2.1%). Age group distribution has evidenced treatment provided to 14 infants (6.0%), 130 preschoolers (56.0%), 51 schoolchildren (22.0%) and 37 adolescents (15.9%), as shown in Figure 1. Patients' mean age was 5.58 years; their age ranged from 11 months to 17 years and 10 months.

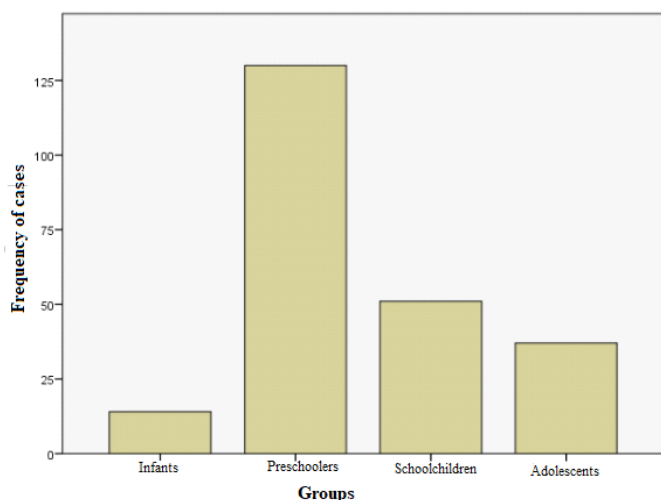


Figure 1. Case distribution based on age group

With respect to foreign body site, 95 cases were identified in the nose (40.9%); 129, in the ear (55.6%); and 8, in the pharynx (3.4%). The distribution of foreign body types per site has shown higher prevalence of seeds in patients' nose and ear, as well as of fish bone in their pharynx (Table 1). The mean age of patients diagnosed with foreign body in their nose, ear and pharynx was 3.08, 7.29 and 7.63 years, respectively. There was statistically significant higher prevalence of foreign bodies in the nose of younger patients than in the ear and pharynx of older patients ( $p < 0.01$ ). The time of evolution in 71 patients (30.6%) was shorter than 24 hours. However, 41 patients (17.7%) presented unknown time of evolution. The other cases (52.7%) recorded time of evolution ranging from 1 to 30 days. The most prevalent foreign body types were seeds (61 cases; 26.3%), mainly beans, orange and corn; small plastic artifacts (39 cases; 16.8%); metal artifacts (24 cases; 10.3%) and living creatures (20 cases; 8.6%). Living creatures comprised butterflies, ants, cockroaches, beetles and mosquitoes. Other foreign bodies accounted for 88 cases (37.9%) and comprised the most diverse objects, namely: pencil tip, modeling mass, cotton, pieces of cloth, teeth, leaves and flowers, among others. There were no myiasis cases in the analyzed sample.

Table 1. Foreign Body (FB) type per site

Site	FB type	Number of cases
Nose	Seeds	24
	Plastic materials	21
	Metal	11
	Others	39
	Total	95
Ear	Seeds	35
	Living creatures	20
	Plastic materials	18
	Metal	12
	Others	44
Pharynx	Total	129
	Fish bone	3
	Pequi fruit spines	2
	Seeds	2
	Piercing	1
	Total	8

The distribution of these foreign bodies has shown statistically significant differences between age groups. Seeds, plastic artifacts and metallic objects recorded higher prevalence among preschoolers, whereas living creatures recorded higher prevalence among adolescents ( $p < 0.01$ ). The mean age of patients diagnosed with the foreign body "seed" was 4.6 years; the mean age of those with small plastic artifacts was 4.9 years; that of patients with metal objects was 5.7 years and that of patients with the foreign body "living creature" was 10.1 years. (Figure 2).

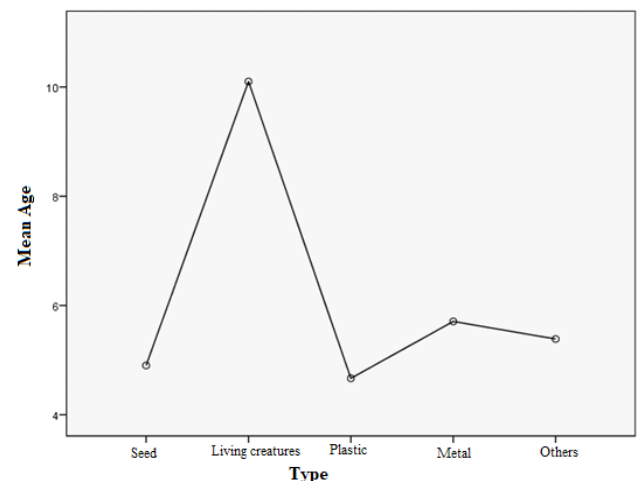


Figure 2. Mean age according to removed foreign body

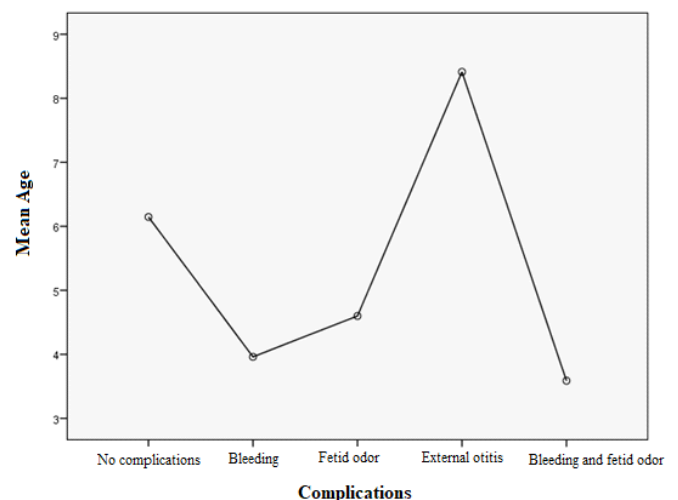


Figure 3. Mean age per complication

Most patients subjected to foreign body removal (137 patients; 59.1%) did not show complications. Isolated bleeding was observed in 51 cases (22.0%), isolated fetid odor accounted for 10 cases

(4.3%), external otitis was observed in 17 cases (7.3%) and bleeding-fetid odor association was observed in 17 cases (7.3%). Pain was not considered a complication. External otitis was the complication affecting patients in the highest mean age group (8.4 years), as shown in Figure 3. The age group-based complication distribution has shown higher prevalence of isolated bleeding and fetid odor in preschoolers, as well as of external otitis in adolescent patients – results presented statistically significant difference between age groups ( $p < 0.01$ ). There was also higher prevalence of complications in preschoolers than in schoolchildren ( $p = 0.014$ ).

## DISCUSSION

Both pediatricians and otorhinolaryngologists must be prepared to treat patients diagnosed with foreign body, given the high incidence of this issue reported in several studies (Awad, 2018; Raj, 2019; Hira, 2019). Such an incidence was confirmed by the number of cases recorded in less than 3-year monitoring of this case type. The integration of these two medical specialties became even more essential due to the limited number of otorhinolaryngological first-aid stations and to their concentration in large urban centers. Thus, parents/legal guardians almost always go to pediatricians or general practitioners before they go to otorhinolaryngologists. There was balance in the incidence of foreign bodies between sex groups; there was low prevalence of it in male patients (52.9%), and this finding was corroborated by the literature available (Awad, 2018, Sidibé, 2021; Hira, 2019). With respect to foreign body distribution based on age group, most cases were observed among preschoolers, according to the division adopted by the Brazilian Pediatrics Society. Once again, this finding ratifies the important role played by the joint performance of otorhinolaryngologists and pediatricians in these cases (SBP, 2014). When it comes to foreign body site, there was prevalence of foreign bodies in the nose of younger children (mean age = 3.08 years); such an incidence has decreased as children's cognitive development progressed. However, overall, patients' ear was the most prevalent foreign body site. Patients at mean age 7.29 years, who were diagnosed with foreign body in their nose, have shown the most homogeneous trend of age-based case distribution. The herein collected data about foreign body sites were in compliance with those reported in other studies. There was prevalence of foreign bodies in patients' ear; it was followed by nose and oropharynx (De, 2018; Raj, 2019; Sidibé, 2021).

Data about the nature of foreign bodies - based on regional, cultural and social differences - are variable in the literature (Sidibé, 2021). The herein collected data about the prevalence of foreign bodies corroborated those analyzed in other studies; there was prevalence of seeds (mainly beans, orange and corn), small plastic artifacts, metallic artifacts, living creatures and other strange bodies (pencil tip, modeling mass, cotton, pieces of cloth, teeth, leaves and flowers). Therefore, foreign bodies are often objects children have access to, at home. This factor, along with children's curiosity and parents/legal guardians' lack of attention, results in the inadequate handling of these objects by younger children. The highest incidence of voluntary cases in younger patients (mean age of patients diagnosed with foreign body "seed" was 4.6 years; small plastic artifacts, 4.9 years; metal objects, 5.7 years) enabled inferring that children's age and incidence of voluntary cases are inversely correlated – such a correlation does not take place in accidental cases (mean age of patients diagnosed with foreign body "living creatures" was 10.1 years) (Raj, 2019; Sidibé, 2021). It is worth emphasizing the incidence of 2 foreign body cases involving pequi fruit spines (25% of foreign body cases in patients' oropharynx) in the current study. Pequi fruit is native to the Brazilian *Cerrado* biome; it is widely used in the Brazilian Midwestern region and Northern Minas Gerais State's cuisine.

The aforementioned cases were diagnosed in adolescent patients. Similar cases were not evidenced in other studies. The current study observed high complication index among the analyzed patients; this outcome was attributed to the incidence of foreign bodies themselves, to attempts to remove them before seeking medical care and to their handling in healthcare services. This index often increases as lack of professional experience in removing foreign bodies increases. This outcome emphasizes the need of training health profession to perform foreign body removal procedures and of raising the awareness of professionals who are not used to perform these procedures (De, 2018). Patients must be informed about the likelihood of bleeding caused by the attempt to remove the foreign body from their ear, as well as of epistaxis, before the procedure is performed. It is so, because bleeding often happens during these procedures, although it is mostly self-limited. The highest incidence of bleeding events in younger children emphasizes the difficulty in removing foreign bodies from patients' ear and nose due to the remarkably small size of these cavities. External otitis cases observed in older patients have met the highest incidence of foreign body "living creatures". This outcome can be attributed to rash in ear canal and to consequent infection caused by insects, which was more often observed than infections caused by plastic and metallic artifacts found in younger children's ear (Regonne, 2017).

## CONCLUSION

Foreign bodies in patients' nose, ear and oropharynx are common findings in clinical practice, mainly in otorhinolaryngological and pediatric practices. Given the most affected (preschoolers and schoolchildren) age groups and the prevalence of foreign bodies often found in home environments, it is of paramount importance instructing family members to pay more attention to children in these age groups in order to avoid such issues. Another important factor lies on the proper management of these patients by trained health professionals in order to help reducing complication indices.

## REFERENCES

- Awad AH, Mostafa ET. ENT foreign bodies: an experience. *International archives of otorhinolaryngology* 2018; 22: 146-151.
- De M, Shahram A. Infections and foreign bodies in ENT. *Surgery (Oxford)* 2018; 36(10): 553-559.
- Hira İ, et al. Childhood nasal foreign bodies: analysis of 1724 cases. *Turkish archives of otorhinolaryngology* 2019; 57(4): 187.
- Pecorari G, Tavormina P, Riva G, Landolfo V, Raimondo L, Garzaro M. Ear, nose and throat foreign bodies: the experience of the Pediatric Hospital of Turin. *J Paediatr Child Health* 2014;50(12):978-984
- Raj A, Vikram W, Avani J. Epidemiological profile of ENT emergencies: our experience. *Indian Journal of Otolaryngology and Head & Neck Surgery* 2019; 71(1): 301-304.
- Regonne PEJ., et al. Nasal foreign bodies in children in a pediatric hospital in Senegal: A three-year assessment. *European annals of otorhinolaryngology, head and neck diseases* 2017; 134(5): 361-364.
- SBP - Sociedade Brasileira de Pediatria. *Calendário Puericultura*. 2014. Disponível em: [https://www.sbp.com.br/fileadmin/user\\_upload/pdfs/CalendarioPuericultura\\_Jan2014.pdf](https://www.sbp.com.br/fileadmin/user_upload/pdfs/CalendarioPuericultura_Jan2014.pdf). Acesso em: 31 de Jul. de 2021.
- Shrestha I, Shrestha BL, Amatya RCM. Analysis of ear, nose and throat foreign bodies in dhulikhel hospital. *Kathmandu Univ Med J (KUMJ)* 2012;10(38):4-8(KUMJ)
- Sidibé Y, et al. Foreign Bodies in ENT from Peripheral Health Center of Bamako (Mali). *International Journal of Otorhinolaryngology* 2021; 7(1): 1.

\*\*\*\*\*