



ISSN: 2230-9926


Available online at <http://www.journalijdr.com>

# IJDR

International Journal of Development Research

Vol. 10, Issue, 11, pp. 41958-41962, November, 2020

<https://doi.org/10.37118/ijdr.20354.11.2020>



RESEARCH ARTICLE

OPEN ACCESS

## WEST SYNDROME: MEDICAL CONSIDERATIONS AND STOMATOLOGIC ASPECTS

**Cristhiane Olivia Ferreira do Amaral<sup>\*1</sup>, Blenda Lobo Nogueira<sup>2</sup>, Mariana Olívia Ferreira do Amaral<sup>3</sup>, Marcelo Sávio Paiva do Amaral Filho<sup>3</sup>, Silvana Ribeiro Roda<sup>4</sup>, Eliane Cristina Gava Pizi<sup>5</sup> and Fabiana Gouveia Straioto<sup>5</sup>**

<sup>1</sup>DDS, Ms, PhD. Department of Special Care Dentistry and Pediatric Dentistry, Dental School, University of West São Paulo, Presidente Prudente, S P, Brazil

<sup>2</sup>Graduate student, Dental School, University of West São Paulo, Presidente Prudente, SP, Brazil.

<sup>3</sup>Graduate student, Medical School, University of West São Paulo, Presidente Prudente, SP, Brazil.

<sup>4</sup> DDS, Ms, Professor São Leopoldo Mandic College, Campinas (SP), Brazil

<sup>5</sup> DDS, Ms, PhD, Professor Dental School, University of Western São Paulo, Presidente Prudente, SP, Brazil

### ARTICLE INFO

#### Article History:

Received 28<sup>th</sup> August, 2020

Received in revised form

17<sup>th</sup> September, 2020

Accepted 09<sup>th</sup> October, 2020

Published online 24<sup>th</sup> November, 2020

#### Key Words:

Children spasms; Oral Health; Anticonvulsants; Seizures; Gingival hyperplasia

#### \*Corresponding author:

*Cristhiane Olivia Ferreira do Amaral*

### ABSTRACT

**Objective:** The West Syndrome (WS) is characterized by the triad of infantile spasms, hypsarrhythmia and cognitive impairment. The etiology is linked to organic brain disorders whose origins may be prenatal, postnatal or perinatal. The objective of this study is to help identify systemic changes, medical considerations, Stomatological aspects and additionally report two cases of patients with West syndrome. **Case Report:** The stomatological aspects found in both patients were the general wear of the teeth, due to tooth clenching and bruxism, gingival growth, sequence and chronology of altered dental eruptions, deep palate and atresia, presented lack of lip closure, upper and lower lips, cheeks and tongue with flaccid muscle tone and malocclusion. In one patient, multiple caries lesions were also observed, possibly associated with the behavior of the family, diet, oral hygiene and the continuous use of medications, with the presence of thick biofilm, stationary caries lesions showing cariostatic use, which prevented collaborative dental approach. **Conclusion:** The approach to dental care and treatment are discussed. West Syndrome patients have a great diversity of general and oral physical characteristics, difficulty in oral hygiene due to delayed neuropsychomotor development. It is important to provide early care, so that they do not need complex and invasive treatments due to systemic and cognitive impairment. The comprehensive approach and treatment must be carried out by a multidisciplinary team.

Copyright © 2020, *Cristhiane Olivia Ferreira do Amaral et al.* This is an open access article distributed under the Creative Commons Attribution License, which permits unrestricted use, distribution, and reproduction in any medium, provided the original work is properly cited.

Citation: *Cristhiane Olivia Ferreira do Amaral, Blenda Lobo Nogueira, Mariana Olívia Ferreira do Amaral et al, 2020. "West syndrome: medical considerations and stomatologic aspects", International Journal of Development Research, 10, (11), 41958-41962.*

## INTRODUCTION

The West Syndrome (WS) is a rare childhood epilepsy syndrome that includes the triad of epileptic spasms, EEG with hypsarrhythmia and arrest or regression of psychomotor development<sup>1-4</sup>. WS is a rare and severe epilepsysyndrome, responsible for 2.4% of all epilepsies, with male predominance of 2:1. The syndrome starts with seizures that arise during the first year of life, with a peak age of onset during the 3 and 8 months, the incidence of these crises varies from 1: 4000-6000 live births, rarely above 2 years of age<sup>5</sup>.

Regarding the etiology, this syndrome can be Symptomatic refers to cases with defined causes, which include: hydrocephaly, microcephaly, tuberous sclerosis, innate errors of metabolism, congenital infections, degenerative disease and Down Syndrome<sup>3</sup>. Perinatal causes are due to poor delivery care conditions, leading to neonatal anoxia and among postnatal causes the central nervous system infections, meningitis and encephalitis, head trauma and post-vaccine reactions can be highlighted<sup>3</sup>. The fundamental syndrome manifestation are the spasms, Seizures frequently recur, reaching up to 100 a day, which are usually accompanied by

motor abnormalities and hypotonia<sup>4-6</sup>. Cognitive impairment occurs in 80 to 90% of cases, however it can be affected to varying degrees and often associated with motor deficits, behavioral disorders and autistic traits<sup>8-11</sup>. Tuberous sclerosis, which is an autosomal disorder characterized by the presence of hypochromic spots and tubercles on the skin, by hematomas and neoplastic lesions that affect the central nervous system, is often associated with SW, worsening its prognosis<sup>12,13</sup>. The oral characteristics of SW patients are not well established, oral hygiene habits have not been established, due to cognitive deficits and non-collaborative behaviors, a diet rich in carbohydrates, the use of liquid medications containing a high level of sugar, drugs that also lead to hyposalivation may present poor oral health quality, with the presence of caries and periodontal disease and medicated gingival hyperplasia which is enhanced by poor hygiene<sup>14</sup>. Patients with SW may also present the following: altered sequence in the teeth eruption, delayed eruption, malocclusion. Bruxism or dental clenching are also often reported along with generalized tooth wear. Oral and dental trauma, fractures to dental avulsions, among other types of trauma, due to the motor deficit of SW individuals are also reported. Abnormal movement of the facial muscles causing prolonged food retention can trigger poor hygiene. The importance of this research is that the dentist must be trained in order to recognize the SW patients' oral problems once they commonly manifest systemic diseases that can influence the treatment plan, such as seizures and drug therapies, associated with difficulties during clinical care. The objective of this study is to help identify systemic changes, medical considerations, Stomatological aspects and additionally report two cases of patients with West syndrome.

### Case Report

Those responsible for the patients who participated in this case report were informed of the purpose of the study, as well as of the methods used to evaluate the patients, and the patients were only evaluated after the Informed Consent Form was signed which was based on ethical aspects according to the principles originating from the Declaration of Helsinki. All patient data were recorded on a standardized clinical record. This study was approved by the Ethics and Research Committee (CEP) under Opinion n° 951.510. This study only started after its approval.

#### Case Report 1

Patient G.R.F, male, 12 years old, presenting West Syndrome of Idiopathic origin. The following medications have been used: sodium divalproate lamotrigine, Phenytoin (anticonvulsants) and Clonazepam (a benzodiazepine sedative with anticonvulsant action). The mother's health during pregnancy was stable however bleeding occurred in the sixth and eighth month, requiring rest. In the second bleeding, she was hospitalized for 8 days, requiring the use of anti-abortion medication. The medicine also used by the patient: are ACTH injections to control seizures. Patient G.R.F has 24 spasms during a seizure. After seizure control, he presents generalized edema and systemic arterial hypertension (SAH). A delay in neuropsychomotor development (ADNP) and Autistic Spectrum Disorder (ASD), secondary to idiopathic SW, was diagnosed by a multidisciplinary team. As for the physical

aspects, he has a hypotonic tone and a wheelchair (Figure 1a - 1b).

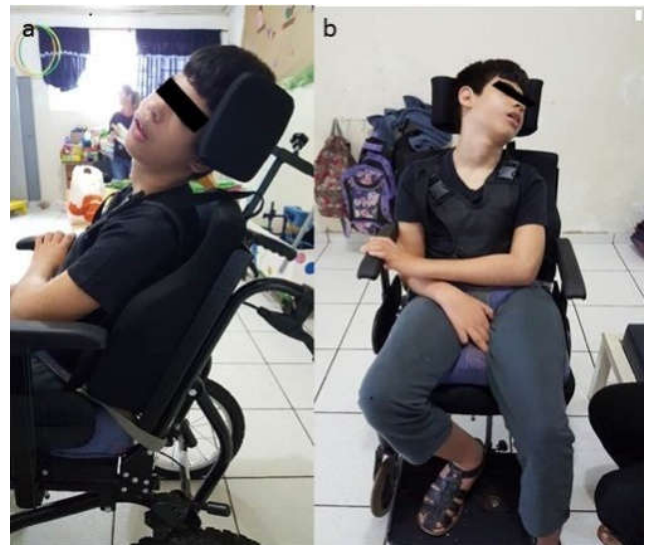

Figure 1a: Front view

Figure 1b: Side view

During the oral physical examination and anamnesis, it was found that he chokes easily, with saliva and food, has dysphagia and digital sucking habit. Mild gingival hyperplasia (Figure 2a) and fine biofilm were diagnosed, without acute or chronic caries lesions. An enamel fracture was observed in incisor 11, caused by a fall from the wheelchair, but no signs of pulp necrosis were found (Figure 2b). In the evaluation of orofacial myofunctional functions, the following were observed: parted lips, lack of lip sealing, upper and lower flaccid tonus and tongue with flaccid tonus, malocclusion, dental clenching and bruxism, altered tooth eruption sequence and chronology and breathing oronasal.

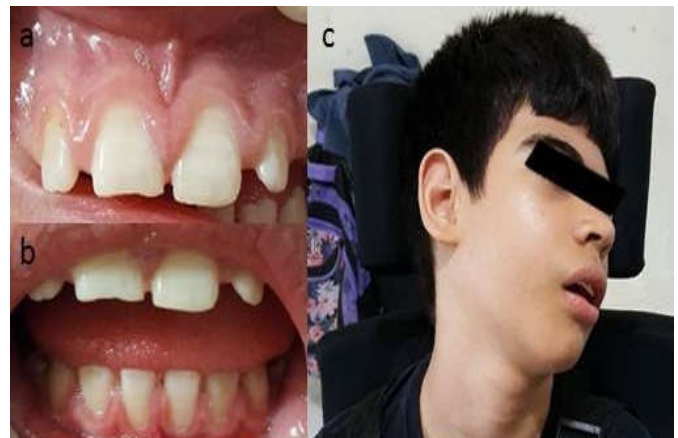

Figure 2a: Presence of gingival hyperplasia

Figure 2b: Fracture enamel incisal tooth 11

Figure 2c: Lack of lip sealing

The mother, very collaborative and present. The patient was approached using behavioral management techniques, in order to collaborate with dental treatment. Due to dental prevention and frequent visits to the dental office, this patient has never had dental caries. Preventive procedures such as: professional prophylaxis, topical applications of antimicrobials (0.12% chlorhexidine digluconate) and topical application of 2% neutral fluoride, as well as maternal collaboration in brushing at home, were essential to provide quality oral health of the patient.

## Case Report 2

Female patient, R.A.S.A., also with West syndrome, 12 years old, uses the following drugs: Clobazam (sedative benzodiazepine with anticonvulsant action) and also uses ACTH injections to control seizures. Until the third month of age, his development was normal, when he had his first attacks and was diagnosed with West Syndrome. Currently, seizures are under control. However, the patient does not eat alone and her food consists of more pasty foods, as she has a high chance of choking, r has no sphincter control and needs to wear a diaper. Regarding emotional reactions, she is agitated, reacts to stimuli in the environment, her attention span and concentration are very short, she interacts with music, has a significant delay in development and also in cognitive patterns. Regarding physical characteristics, it presents a hypotonic tone (Figure 3a) and uses a wheelchair for mobility. She has normal shoulders and hands for support (Figure 3b)

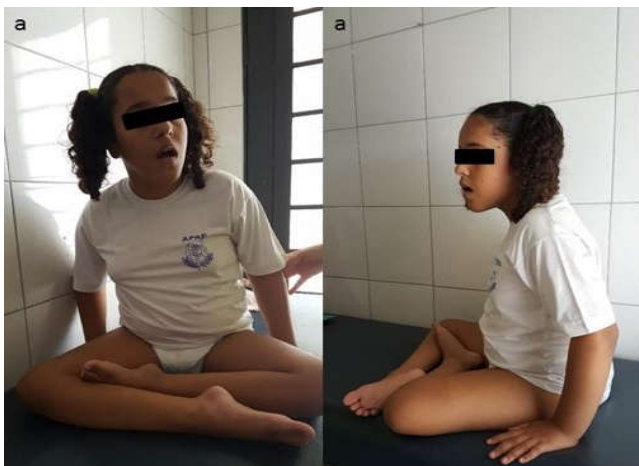

Figure 3a: Front view

Figure 3b: Side view

In the assessment of orofacial myofunctional functions, the following were observed: open lips, lack of lip sealing, hypotonicity of the upper and lower lips, malocclusion (Figure 3a). Regarding stomatognathic functions, she breathes through the mouth, dental clenching and bruxism, altered tooth eruption sequence and chronology. In the intraoral evaluation, there was the presence of gingival bleeding through brushing and probing, without the presence of a periodontal pocket, brownish pigmentation of the teeth due to the use of 0.12% chlorhexidine digluconate (Figure 4a), with the presence of excess biofilm, chronic caries in teeth 75 and 85, stationary caries was found due to the use of cariostats.

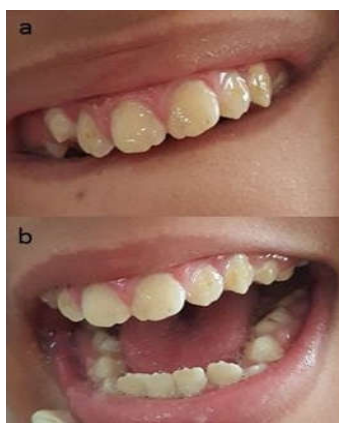

Figure 4a: The use of 0.12% chlorhexidine digluconate  
Figure 4b: Presence biofilm

As the patient has a behavioral barrier, dental treatment was impaired. (Figure 4b). The mother reports hygiene difficulties, as the daughter is not a collaborator, needing alternative means, such as protective stabilization. It was reported by the mother that there is no frequency of dental appointments due to the difficulty of walking and the patient's negative behavior. The oral hygiene education procedures for both caregivers were performed, as they are responsible for all the daily care of their children, as patients have a delay in neuropsychomotor development. Dietary guidelines were given on more cariogenic and less cariogenic foods, in addition to encouraging frequent visits to the dentist to prevent oral diseases.

## DISCUSSION

This study was carried out under the hypothesis that West Syndrome patients have unmet needs for dental approach, related to oral hygiene, behavioral barrier, systemic characteristics that interfere with the treatment plan, use of controlled drugs, salivary aspects that lead to poor quality of oral health, therefore the need to seek dental prevention since they are babies. Research reporting the oral health status of patients with special needs are scarce<sup>17,18</sup>. This is also the case of patients with the SW. Few studies on the oral health of patients with SW were found in literature<sup>19</sup>. Many patients with special needs find it difficult to maintain a good quality of oral health and also difficulty accessing dental care because of their disability or medical condition<sup>18,20</sup>. The West syndrome affects both sexes, according to Telles et al. (2012)<sup>8</sup> predominant in males. In this study, two cases were reported: a 12 year-old boy and a girl of 12 years old. The case reports highlighted the need for prevention and control measures of oral diseases since childhood and frequent visits to the surgeon dentist creating a habit for SW patients can reduce the presence of caries and other oral diseases, avoiding the need for invasive treatments. Clinical manifestations appear during the first year of life, especially between 3 and 8 months according to the electroencephalogram<sup>8</sup>. In both cases presented, electroencephalographic changes characteristic of SW have been reported since according to most authors, a normal EEG tracing must formally excludethe West syndrome diagnosis.

The physical manifestations presented by the SW are diverse with spasms usually accompanied by changes in the neurological examination, and of which the most common is the hypotonia<sup>21</sup>. The generalized hypotonia was an aspect found in the patients of this study as well as the use of a wheelchair for mobility. Convulsive spasms and seizures are the most important features in SW<sup>19</sup> and were presented by the two patients in the study, the female patient is already controlled regarding spasms and seizures, however the male patient is not controlled by medication. Chlorhexidine gluconate is an antimicrobial that has proven effectiveness against bacterial plaque and gingivitis<sup>22</sup>. Therefore this medication should be used and encouraged for its use by caregivers of patients with special needs, in order to prevent the most prevalent oral disease: tooth decay and gingivitis, preventing invasive dental treatment in these patients. The Silver Diaminofluoreto (CARIOSTATIC) stands out for its anticariogenic properties, reducing the solubility of apatite, while silver possesses bacteriostatic and bactericidal action. It also presents preventive action, remineralizing and desensitizing action. The use of cariostatic can be performed in

the acute phase of the disease specially in non-collaborating patients. There are disadvantages in relation to the anti-aesthetic character as it causes brownish stains in the areas affected by the carious process. Nonetheless their benefit becomes more relevant, some professionals avoid using this cariostatic agent due to any possible patients' or guardians' non-acceptance<sup>23</sup>. The fibrous gingival hyperplasia is commonly associated with the use of anticonvulsants, an increase in gingival tissue is observed after two to three months of the beginning of the medication. It may be exacerbated by inadequate control of the biofilm due to non-cooperation of the special patient. In general, the gingival mucosa present paler color as compared with part of the healthy gums which may be reddish in many patients due to accumulation of biofilm which is more evident on the buccal surfaces of the anterior teeth and more frequent in the maxilla than the mandible. Some cases need ulotomia in order to trigger both primary and permanent teeth eruption.

Regular professional cleaning with special attention for the dental calculus removal and retentive factors of dental biofilm are of utmost importance<sup>24</sup>. Some case reports have identified the following oral findings as being common; mouth breathing, deep palate, gingival hyperplasia, severe gingivitis, anterior open bite, changes in the chronology of tooth eruption, generalized tooth wear, cleft tongue, tongue thrust between arcs. Furthermore, the presence of multiple white carious lesions, poor oral hygiene and a diet rich in carbohydrates are also reported<sup>19</sup>. In this study, deep palate and tongue interposition were observed in the two patients with oronasal breathing. It was observed that in the female patient the presence of bleeding gums, gingivitis, thick biofilm with the presence of chronic stationary caries lesions due to cariostatic use and impaired dental treatment. Poor oral hygiene and a diet high in carbohydrates were also findings corroborating with the literature. The dental care for these patients is further complicated because there are severe intellectual deficits, and limited communication ability, involuntary movements of the head and neck and the constant spasms can hamper the handling of the patient. The sharp stiffness usually does not allow proper examination of the oral cavity causing decrease in cooperation with the professional even in simple procedures, as well<sup>6,14,16</sup>. Few studies on the oral health of SW patients enhance the need and importance of planning dental care to this specific population. Therefore this manuscript has proposed to point out the systemic and oral health characteristics of SW patients.

## Conclusion

West Syndrome patients have a great diversity of general and oral physical characteristics, difficulty in oral hygiene due to delayed neuropsychomotor development. It is essential to provide early dental care, so that they do not need complex and invasive dental treatments due to systemic and cognitive impairment. The comprehensive approach and treatment must be carried out by a multidisciplinary team.

## REFERENCES

- Jansen K, Vandeput S, SV Huffel, Lagae L. Cardiac Autonomic dysfunction in West syndrome. *Epilepsy Res* 2012; 102 (3): 167-72.
- Fonseca LF, Oliveira AL. Infantile spasms: experience in thirteen cases. *Arch Neurol*. 2000; 58 (2-B): 512-17.
- Matta APC, Chiacchio SV, Leyser M. Possible etiologies of West syndrome: evaluation of 95 patients. *Arch Neurol*. 2007; 65 (3A): 659-62.
- Son AL, Malucelli DB, LL Ferreira, D' Ottaviano FG, Silveira JM. Evaluation of the brainstem evoked potentials in West syndrome. *Rev Bras Otorrinolaringol*. 2004;70 (1): 90-3.
- Scantlebury MH, Galanopoulou AS, Chudomelova L, Raffo E, D Betancourth, Moshe SL. The model of symptomatic infantile spasms syndrome. *Neurobiol Dis*. 2010; 37 (3): 604-12.
- Aguiar SM, CP Torres, Borsatto MC. West syndrome. *J Baby Bras Odontopediatr Odontol*. 2003;6 (30): 123-6.
- Souza VA, Pereira AM, Palmini A, EP Neto, Torres CM, Martinez JV, et al. West Syndrome, autism and Temporal Cortical Dysplasia: Resolution of Epilepsy and Autism improvement with surgery. *J Clin Neurophysiol Epilepsy*. 2008; 14 (1): 33-7.
- Tellez AT, Cross AL, Garcia RG. clinical and genetic studio of Cuban patients con West syndrome. *Rev Cienc Medical*. 2012; 16 (2): 49-63.
- Moraes MP, Montenegro MA, Franzon RC, Ávila OJ, MM Warrior. Evaluation of the efficacy and tolerability of vigabatrin in West syndrome. *Arch Neurol*. 2005; 63 (2-B): 469-73.
- Souza AH, Jr. LA, Laurentino SG. Vigabatrin in the treatment of West syndrome: Clinical and EEG in 13 patients. *Arch Neurol*. 2007; 65 (1): 144-9.
- Gomes MC, Garzon And Sakamoto AC. 50 years experience of adrenocorticotrophic hormone (ACTH) in the treatment of West syndrome: literature review and UNIFESP protocol. *J Clin Neurophysiol Epilepsy*. 2008; 14 (1): 27-32.
- Antoniuk SA, Bruck I, Spessatto A, Halick SM, Bruyn LR, Meister And Paola D. West syndrome: clinical and electroencephalographic evolution of 70 patients and response to treatment with adrenocorticorófico hormone, prednisone, vigabatrin, nitrazepam and valproic acid. *Arch Neurol*. 2000; 58 (3a): 683-90.
- Rotta NT, Silva AR, Ohlweiler L, R. Riesgo Vigabatrin in the treatment of intractable epilepsy in patients with tuberous sclerosis and West syndrome. *Arch Neurol*. 2003; 61 (4): 988-90.
- Regis RR, CT Rock, Torres CP, Queiroz IF, Queiroz AM. Oral findings and dental treatment in a child with West Syndrome. *Spec Care Dentist*. 2009; 29 (6): 259-63.
- Read AO, Katz CT. Oral health status and access to dental treatment of patients with cerebral palsy treated at a referral center northeast - Brazil. *Rev CEFAC*. 2012; 14 (5): 861-71.
- Amaral COF, Chagas JT, Rodrigues LC. Prevalence of bruxism and evaluation of oral health in patients with cerebral palsy. *Colloquium Vitae*. 2011; 2 (1): 41-8. <http://agris.fao.org/agrissearch/search.do?recordID=BR2013800289>
- Oak RB, RF Mendes, Meadow RR, Neto JM. Oral health and oral motor function in children with cerebral palsy. *Spec Care Dentist*. 2011; 31 (2): 58-62.
- Oliveira JS, Meadow RR, KR Lima, OH Amaral, JM Neto, Mendes FR. Intellectual disability and impact on oral health: a study paired. *Spec Care Dentist*. 2013; 33 (6): 262-8.
- Dantas-NB, Neta, Oak CH, Alencar SM, Jr. RR, RF Mendes. Dental findings in children with West syndrome. *Spec Care Dentist*. 2014; 34 (6): 291-4.

20. Castro AM, Marchesoti MN, FS Oliveira, Novaes MP. Analysis of dental treatment provided under general anesthesia in Patients with special needs. *Rev Odontol UNESP*. 2010; 39 (3): 137-42.
21. Renato TA. The equine therapy in West syndrome: a case study [TCC]. Criciúma: Universidade do Extremo Sul Catarinense; 2012.
22. Pegoraro J, Silvestri L, L Face, Stefenon L, CB Mozzini. adverse effects of chlorhexidine gluconate at 0.12%. *J Oral Invest*. 2014; 3 (1): 33-7.
23. Belotti L, LS City, Gomes AM. The applicability of Silver Diaminofluoreto in children 4-10 years old at the pediatric dentistry clinic of the Federal University of Espirito Santo, Brazil. *Health Sci J* 2016; 18 (1):5-12.
24. Baumgarten T, Cancino CH. Epilepsy and dentistry: a literature review. *Rev Bras Odontol*. 2016; 73 (3): 231-6.
25. Loureiro CCS, Adde CA, Perez EGF, Penha SS. topical and systemic adverse drug effects in the oral mucosa. *Rev Bras Otorrinolaringol*. 2004; 70 (1): 106-11.

\*\*\*\*\*