



## HISTOLOGICAL CHANGES OF *AZADIRACHTA INDICA* (NEEM) ON THE LIVER OF FRESH WATER CATFISH *HETEROPNEUSTES FOSSILIS*

\*Vaishali S. Panchwate(Tinkhede) and Dr. V. T. Tantarpare

Department of Zoology, Mahatma Fule senior college, Warud, Amravati, Maharashtra

### ARTICLE INFO

#### Article History:

Received 28<sup>th</sup> March, 2018  
Received in revised form  
16<sup>th</sup> April, 2018  
Accepted 22<sup>nd</sup> May, 2018  
Published online 28<sup>th</sup> June, 2018

#### Key Words:

Histopathology, *Heteropneustes fossilis*,  
Homogenous, Sinusoids,  
Hepatic cells, Vacuoles, etc.

### ABSTRACT

**Introduction:** The histological effects of *Azadirachta indica* (Neem) as a biopesticide, on the liver of *Heteropneustes fossilis* were determined. The histopathological changes induced in the liver were cytoplasmic vacuolization of the hepatocytes, blood vessel congestion, inflammatory leucocytic infiltration and necrosis. All these alterations in liver histology can be considered to monitor the water contaminated with biopesticides.

Copyright © 2018, Vaishali S. Panchwate (Tinkhede) and Dr. V. T. Tantarpare. This is an open access article distributed under the Creative Commons Attribution License, which permits unrestricted use, distribution, and reproduction in any medium, provided the original work is properly cited.

**Citation:** Vaishali S. Panchwate(Tinkhede) and Dr. V. T. Tantarpare, 2018. "Histological changes of *azadirachta indica* (neem) on the liver of fresh water catfish *heteropneustes fossilis*", *International Journal of Development Research*, 8, (06), 20710-20712.

### INTRODUCTION

Neem has also been used successfully in aquaculture systems to control fish predators (Dunkel and Ricilards, 1998). Martinez (2002) stated that aqueous extract of neem leaves and other neem-based products have been extensively used in fish-farms as alternative for the control of fish parasites and fish fry predators such as dragon-fly larvae. Although neem extract is considered of low toxicity towards non-target aquatic life, water extracts of the bark of the neem plant caused respiratory problems in *Tilapia zilli* (Omoregie and Okpanachi, 1997), while long exposure to low concentrations of the crude extract of *A. indica* delayed the growth of this cichlid fish (Omoregie and Okpanachi, 1998). Also, the use of pesticides in aquaculture systems to control fish diseases, parasites and other pests not only leads to high levels of residues in the animals but also may interfere with the maintenance of their homeostasis and thus affect their performance (Barton and Iwama, 1991; Wendelaar Bonga, 1997). Histological study appears to be a very sensitive parameter and is crucial in determining cellular changes that may occur in target organs, such as the liver.

\*Corresponding author: Vaishali S. Panchwate (Tinkhede)  
Department of Zoology, Mahatma Fule senior college, Warud,  
Amravati, Maharashtra.

Exposure to biopesticide may cause histological changes in the liver. Fish liver histology could therefore serve as a model for studying the interactions between environmental factors and hepatic structures and functions (Hinton and Lauren, 1993; Gernhofer *et al.*, 2001).

### MATERIALS AND METHODS

#### Histo-pathological Studies

The Present investigation has been carried out to study the effect of sub-lethal concentration of *Azadirachta indica* on liver of the freshwater Indian cat fish *Heteropneustes fossilis* at 24,48.72 and 96 hours. For histological study Healthy and sexually mature specimen of *Heteropneustes fossilis* measuring about 20 -30 cm length and 50-100 gm in weight were selected and maintained in glass aquaria containing tap water and acclimatized in laboratory conditions at room temperature for one week. The water of the aquarium was changed daily and fishes are fed daily with commercial fish food. Fishes are starved for 24 hours prior to the experiment and are not fed during the period of experiment (Dalela *et al.*, 1979). In this experiment, the specimens were kept in two experimental groups. Control Group and Experimental Group. Each group was exposed to sublethal concentration of the

*Azadirachta indica* similar set up was also maintained as control. The animals were scarified for optimal concentration of biopesticide (*Azadirachta indica*) for different exposure of 24, 48, 72 and 96 Hrs. For histological studies, fishes were scarified during the exposure period of 24, 48, 72 and 96 Hrs respectively. The toxicant was renewed after fixed period. The technique of MICROTOMY is being used for the histological study purpose of liver of the fresh water catfish *Heteropneustes fossilis*.

## OBSERVATION AND RESULTS

Figure: Effects of *Azadirachta indica* on Liver of *Heteropneustes fossilis*

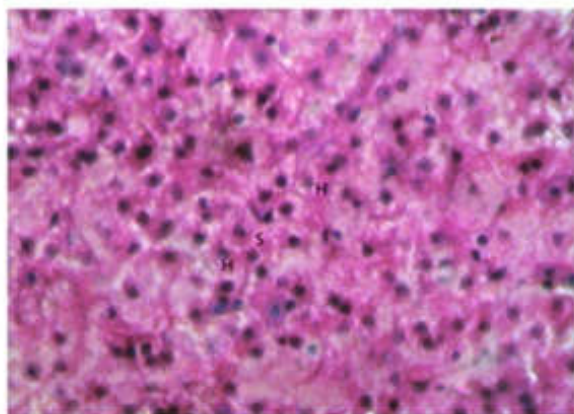


Fig. Normal Liver

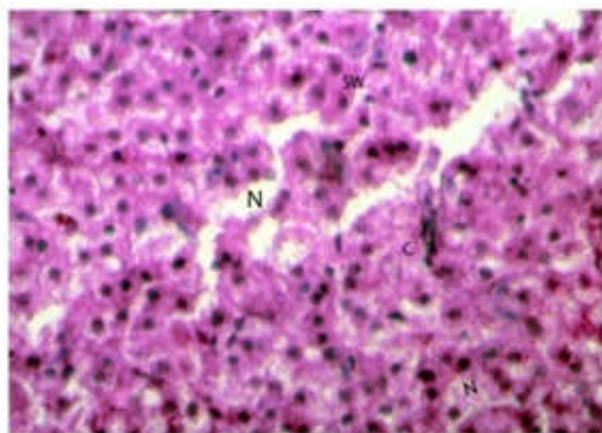


Fig. 24 hours liver

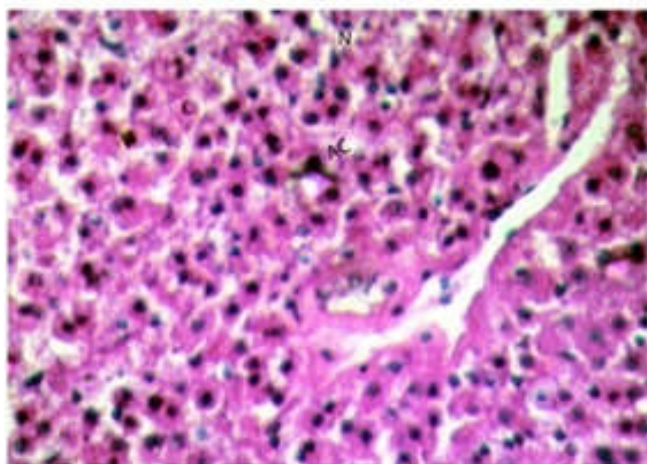


Fig. 48 hours liver

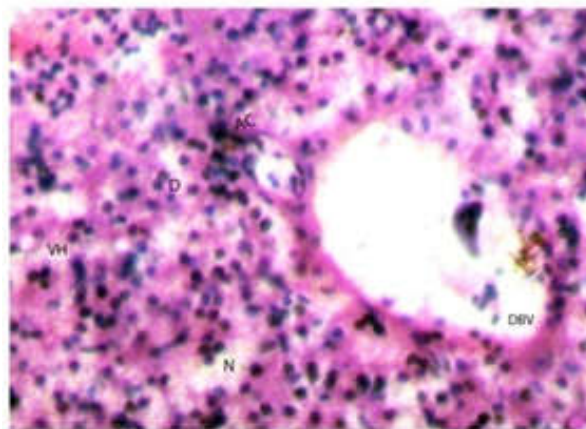


Fig. 72 hours liver

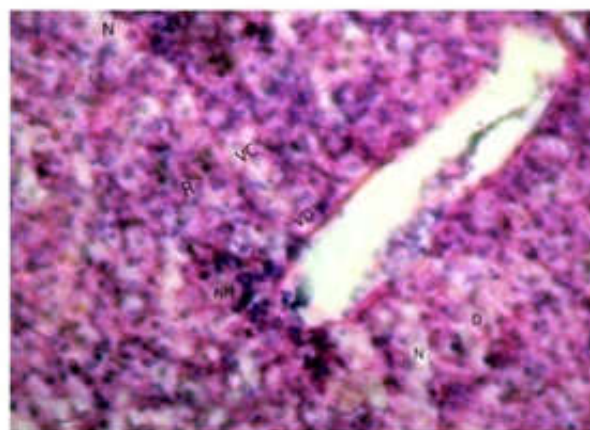


Fig. 96 hours liver

### Effects of *Azadirachta indica* on Liver of *Heteropneustes fossilis*

**Fig - Normal Liver:** In normal liver of *Heteropneustes fossilis* shows liver shows polygonal hepatocytes (H) with centrally placed rounded nucleus and homogenous cytoplasm as well sinusoids (S).

**Fig -24 hours Liver:** At 24 hours cytoplasmic damage was not so sever but the orientation of the cells was disrupted and vacuolization in the liver cells, cloudy swelling of hepatocytes (SW), congestion (C), necrosis (N) were seen.

**Fig – 48 hours Liver:** At 48 hours the lesions are further characterized by elongation of blood vessels. Most of the hepatocytes lost their cell boundaries. Focal necrosis of hepatocytes (N), accumulation of cytoplasm (AC), congestion (C) and degeneration of hepatic cells (DH) was seen prominently.

**Fig – 72 hours Liver:** At 72 hours exposure degeneration of blood vessels (DBV), necrosis (N), vacuolated hepatocytes (VH) with pycnotic nucleus, degeneration of hepatic cells membrane (D), accumulation of cytoplasm (AC) were observed.

**Fig-96 hours Liver:** At 96 hours the liver tissues became a necrotic spongy mass with degeneration of sinusoidal. Ruptured hepatocytes and cell membrane of central vein (R) were observed at 96 hrs exposure. Also vacuolar degeneration (VD), degeneration of cell membrane (D), Nuclear

hypertrophy (NH), focal necrosis (N), vacuolization of cytoplasm and hepatocytes (VC) has been observed.

## DISCUSSION

Exposure to sub lethal concentration of Biopesticide *Azadirachta indica* showed the tissue damages in liver structure of *Heteropneustes fossilis*. The liver is a vital organ of the digestive system present in fish. It has a wide range of functions, including detoxification, protein synthesis, and production of biochemicals necessary for digestion. The liver is necessary for survival and typically the largest visceral (internal) organ. It is an enzyme secreting gland, not a metabolic organ, and it is unclear how truly homologous it is to the vertebrate liver (Romer *et al.* 1977). In normal liver of *Heteropneustes fossilis* shows polygonal hepatocytes with centrally placed rounded nucleus and homogenous cytoplasm as well sinusoids. But after exposure necrosis of hepatocytes, accumulation of cytoplasm, congestion and degeneration of hepatic cells, degeneration of blood vessels, and vacuoles were seen prominently. The Halver *et al.* (1966), Konar (1977), Ibrahim *et al.* (2002) and Al-Kahtani (2011) observed the same results during their experiments for study the effects of biopesticide on fresh water fishes (Rafiq and Dahot 2010).

## Conclusion

Although *Azadirachta indica* (Neem) is used as a biopesticide and considered as low toxicity towards non-target aquatic life like fishes but it interfere and affect the liver histology of the fish. The Neem is one of the best Biopesticides which shows very less hazards to environment. But the present study on *Heteropneustes fossilis* and previous research made on the aquatic organisms especially fresh water fishes proved the hazardous effects of *Azadirachta indica* on reproductive biology. So, in future there is need of more research to assess the purported benefits of Neem.

## REFERANCES

Al-Kahtani, M.A. 2011. Effect of an Insecticide Abamectin on Some Histopathologica Characteristics of Tilapia Fish (*Oreochromis Niloticus*). *Ameri. J of Agri. and Biolo. Sci.*, 6 (1): 62-68.

- Barton, B.A., and G.K., Iwama, 1991. Physiological changes in fish from stress in aquaculture with emphasis on the response and effects of cichlid *Tilapia zillii* (Gervais). *Acta Hydrobiol.* 39, 47–51. contaminated streams. *J. Aquat. Ecosys. Stress Reco., corticosteroids.* *Annu. Rev. Fish Dis.* 1: 3–26.
- Dalela, R.C., Bhatnagar M.C., Tyagi A.K., & Verma S.R. 1979. Histological damage of gills in *Channa gachua* after acute and subacute exposure to endosulfan and Rogor. *Mikroskopie (Vienna)*, 35: 301-307.
- Dunkel, F.V. and D.C., Ricilards, 1998. Effect of an azadirachtin formulation on six non target aquatic macroinvertebrates. *Environ.*
- Halver, J.E., Ashley, L.M. and G.N. Wogan. 1966. "Acute aflatoxicosis in *Rainbow trout and Coho Salmon*" *Feb.Proc.* 25:61-62.
- Ibrahim, I.A., Khalid, S.A., Omer, S.A. and S.E. Adam. 2002. On the toxicity of *Azadirachta indica* leaves. *J. Ethnopharmacol.*, 35: 267 - 273.
- Konar, S.K. 1977. Hazards of water pollution by pesticides. *Symposium on Environ. pollution and Toxicology.* Haryana Agricultural University and Indian National Science Academy. 83-93.
- Martinez, S.O. 2002. NIM — *Azadirachta indica*: natureza, usos múltiplos produção. Instituto Agronômico do Paraná (IAPAR),
- Qmoregie, E. and M Okpanachi. 1998. Growth of *Tilapia zillii* exposed to sublethal concentrations of crude extracts of *Azadirachta indica*. *Acta Hydrobiol.*, 34: 281-286.
- Rafiq, M. and M Dahot. 2010. Callus and Azadirachtin related limonoids production through in vitro culture of neem. *Afri. J. of Biotech.* 9 (4): 449-45
- Romer, A.S. and T.S. Parsons, 1977. *The Vertebrate Body.* Philadelphia, PA: *Holt-Saunders International.* pp. 354–355.
- Wendelaar Bonga, S.E. 1997. The stress response in fish *Physiol. Rev.* 77: 591–625.

\*\*\*\*\*