

PRINZMETAL ANGINA: CASE RARE OF DOUBLE CORONARY SPASM

***Sergio Fasullo, Sergio Cannizzaro, Giuseppe Vitale, Debora Cangemi, Filippo Ganci, Graziella Vetrano, Gabriella Vitrano Stefania Davì, Giorgio Maringhini and Giovanni Polizzi**

Coronary Care Unit, Paolo Borsellino, G.F.Ingrassia Hospital Palermo, Italy

ARTICLE INFO

Article History:

Received 13th February, 2018
Received in revised form
21st March, 2018
Accepted 03rd April, 2018
Published online 31st May, 2018

Key Words:

Prinzmetal's angina, Coronary spasm,
Nitrate, Cilostazol.

ABSTRACT

Unlike typical angina, which is often triggered by exertion or emotional stress, Prinzmetal's angina almost always occurs when a person is at rest, usually between midnight and early morning. These attacks can be very painful. Prinzmetal's angina is rare, representing about two out of 100 cases of angina, and usually occurs in younger patients than those who have other kinds of angina. The coronary arteries can cause a spasm due to stress and smoking, as the case we will describe. 39-year-old young woman smoker, presented to our department for night-time episode and electrocardiographic changes suggestive of acute myocardial infarction. Medicines can help control the spasms. Drugs such as calcium antagonists and nitrates are the mainstays of treatment. In this case the young woman was intolerance to oral nitrate. Prognosis is generally good but the quality of life is less to standard.

Copyright © 2018, Sergio Fasullo et al. This is an open access article distributed under the Creative Commons Attribution License, which permits unrestricted use, distribution, and reproduction in any medium, provided the original work is properly cited.

Citation: Sergio Fasullo, Sergio Cannizzaro, Giuseppe Vitale et al., 2018. "Prinzmetal angina: case rare of double coronary spasm", *International Journal of Development Research*, 8, (05), 20547-20549.

INTRODUCTION

Coronary artery vasospasm is a shrinkage of the coronary arteries that can cause complete or near-complete occlusion of the vessel. In 1959, Dr. Myron Prinzmetal described a different entity of angina. This vasospastic disease, that not does follow traditional risk factors, can cause acute coronary syndrome. Vasospastic angina behaves differently in men and women. Vasospastic angina, variant angina, or Prinzmetal angina is known a clinical entity characterized by chest pain at rest with transient ischemic electrocardiographic changes in the ST segment, with prompt response to nitrates. These symptoms are attributed to coronary arteries spasm. Incidence or prevalence of Prinzmetal angina is still unknown. The reason for this is the possible misdiagnosis or confusion with other conditions that might present with the same symptoms, and further evaluation is not sought. Treatment is focused on decreasing episodes of angina and preventing complications like myocardial injury and arrhythmia. Lifestyle modifications should be encouraged, especially smoking cessation.

Case report

A 39-year-old female, came to our hospital complaining of thoracic oppression at exertion and sometimes occurring at rest, lasting for a few minutes. The patient was an active smoker, with a moderate alcohol consumption habit. The ECG showed ST-elevation in D2,3 and aVF (Figure 1). There was an increase in Troponin I up to 4300 ng/mL but the blood tests were otherwise unremarkable. The patient was admitted at the coronary unit and was scheduled for urgent coronary angiogram. The exam revealed two stenosis in the territories of the right coronary arteries (Figure 2). The administration of 2 mg of intracoronary isosorbide dinitrate reverted all the stenosis with good flow (TIMI 3) was still observed in the right coronary artery (Figure 3). Hence, the diagnosis of vasospastic angina was made. During the hospitalization, the patient had two nocturnal episodes of angina, for this reason cilostazol was added to therapy. The patient was successfully controlled with calcium antagonists (verapamil) and cilostazol and remained asymptomatic.

DISCUSSION

Since this description, several triggering factors have been associated with vasospastic angina. Smoking is also a major risk factor for developing coronary artery vasospasm.

*Corresponding author: Sergio Fasullo,
Coronary Care Unit, Paolo Borsellino, G.F.Ingrassia Hospital
Palermo, Italy.

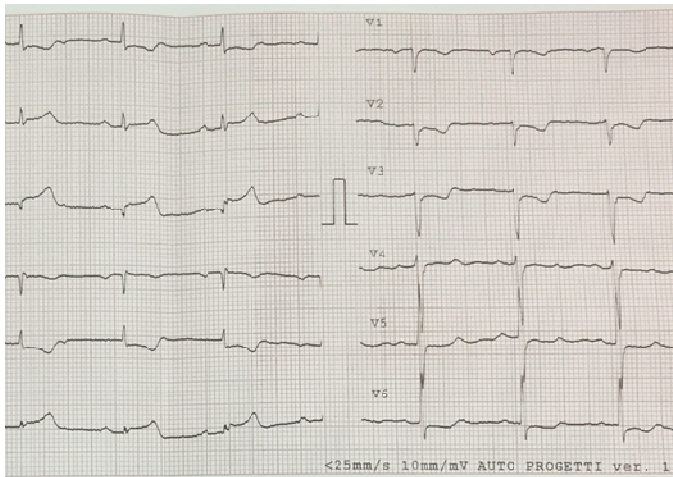


Figure 1. Electrocardiogram in the course of chest pain

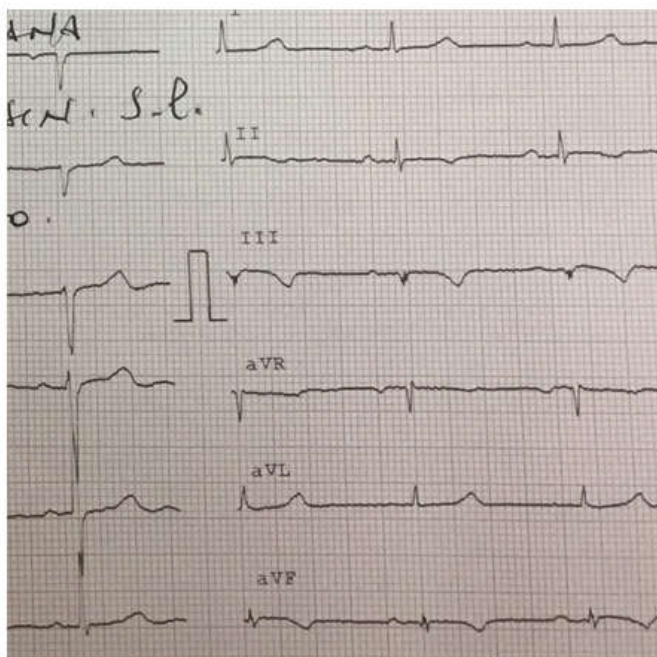


Figure 2. Electrocardiogram after taking one tablet (5 mg) of sublingual nitroglycerin

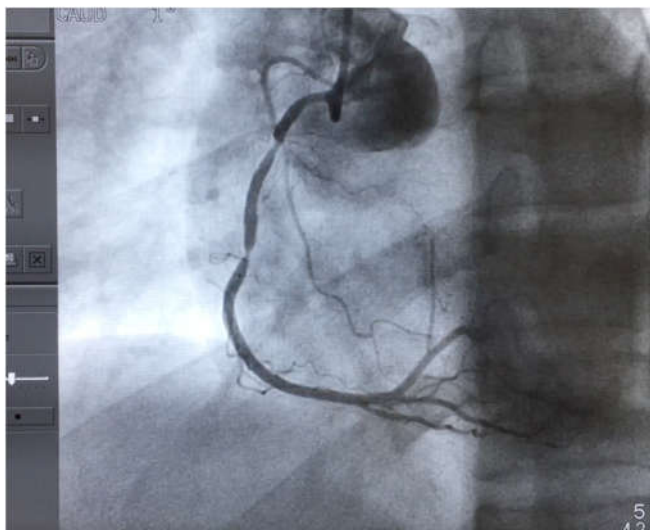


Figure 3. Coronary angiography shows spasm of the right coronary in two points (*double spasm*)

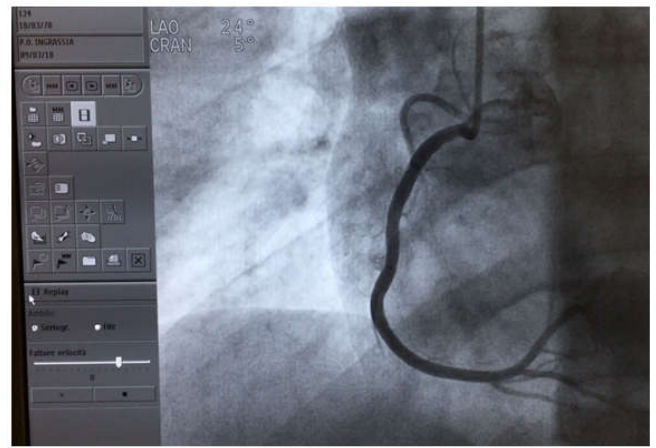


Figure 4. Coronary angiography after nitroglycerin infusion

Many of conventional atherosclerosis risk factors do not appear to be applicable. Angiography does not reveal any obstructive coronary artery disease. Calcium antagonists are the first-line therapy for vasospastic angina. Spontaneous episodes of rest angina were associated with transient ST elevation that promptly resolved with short-acting nitrates. Typically, nitroglycerin is particularly effective to relieve the spasm. Long-acting nitrates are also effective and their vasodilator effect can be additive but there are many side effects such as headache and addiction. Although an angina attack by vasospastic angina can usually be relieved or controlled with nitrates and calcium antagonists, there are some patients who cannot be controlled even by higher doses and combinations of these drugs. Cilostazol is a selective inhibitor of phosphodiesterase 3 that increases intracellular cyclic adenosine mono phosphate contents. A stimulation of cAMP signal transduction increases coronary nitric oxide production. The cilostazol improved angina symptoms in patients uncontrolled by conventional treatment.

Conclusion

If it is not possible to control of coronary spasm with calcium antagonists or nitrates, a drug that has a different mechanism of action is required. Cilostazol has various pleiotropic effects, such as NO dependent vasodilation, antiplatelet action, and improvements of endothelial dysfunction. The cilostazol improves angina symptoms in this case.

Competing interests: The authors declare that they have no competing interests.

Consent: The authors declare that informed written consent was obtained from the patient for the publication of this manuscript and the accompanying figures.

Acknowledgments: I would like to express my gratitude to the colleagues and nurses as traveling companions and to the patients who have shown me the boundaries of pain and hope.

REFERENCES

A randomised, multicentre, double blind, placebo controlled trial to evaluate the efficacy and safety of cilostazol in patients with vasospastic angina.

Angina and Prinzmetal, 2017. Rodriguez Ziccardi M, Gossman WG. Stat Pearls [Internet]. Treasure Island (FL): StatPearls Publishing; 2018 Jan-.2017 Jun 12.

Coronary Artery Vasospasm. Swarup S, Grossman SA. Stat Pearls [Internet]. Treasure Island (FL): StatPearls Publishing; 2018 Jan-.2017 Dec 11.

Efficacy of cilostazol on uncontrolled coronary vasospastic angina: a pilot study. Yoo SY, Song SG, Lee JH, Shin ES, Kim JS, Park YH, Kim J, Chun KJ, Kim JH. Cardiovasc Ther. 2013 Jun;31(3):179-85

Shin ES, Lee JH, Yoo SY, Park Y, Hong YJ, Kim MH, Lee JY, Nam CW, Tahk SJ, Kim JS, Jeong YH, Lee CW, Shin HK. and Kim, JH. 2014. *Heart.*, 100(19):1531-6.

Vasospastic angina behaves differently in men and women. Maas AHEM. *Int J Cardiol.* 2017 Dec 15;249:79-8

Verapamil and vasospastic angina, 2017. underuse in the elderly population. Humbert X, Roule V, Milliez P, Alexandre J. *J Geriatr Cardiol.*, 14(7):430-435.
