



ORIGINAL RESEARCH ARTICLE

OPEN ACCESS

PRECLINICAL STUDIES OF RANIBIZUMAB FOR SAFE USE IN OPHTHALMOLOGY CLINIC

***^{1,2}Marli Gerenutti, ¹Humberto Cenci Guimarães, ³Natália Mencacci Esteves-Pedro, ³Patrícia Santos Lopes, ²Marco Vinicus Chaud, ²Victor Manuel Cardoso Figueiredo Balcão and ^{1,2}Denise Grotto**

¹Laboratory for the Toxicological Research (Lapetox), University of Sorocaba, Sorocaba

²Department of Development and Evaluation of Bioactive Substances, University of Sorocaba

³Federal University of São Paulo, Diadema, São Paulo, Brazil

ARTICLE INFO

Article History:

Received 29th June, 2017
Received in revised form
25th July, 2017
Accepted 19th August, 2017
Published online 30th September, 2017

Keywords:

Cell death, Cellular suffering,
Macular degeneration,
Urine fibroblasts,
Ranibizumab.

ABSTRACT

The research effort entertained herein aimed at evaluating the possible effects of cell injury by ranibizumab in biological assays, in order to prove its safety for use in humans. For this, indirect ophthalmoscopy in albino rabbits was evaluated in vivo for a period of 21 days following intravitreal administration of ranibizumab (10mg/mL) in volumes of 30 and 50 μ L, or 50 μ L of saline solution, and retinal histological staining of the rabbits' eyes performed with hematoxylin/eosin. The assays involving ranibizumab were performed in vitro in cell cultures of murine fibroblasts, at concentrations of 2.5, 10, 250, 350 and 500 μ g/mL. Thorough histological analyses of the retinal tissue showed that intravitreal administration of ranibizumab caused neither cellular suffering or cell death in the in vivo assays, while in the in vitro assays it was only possible to determine the IC₁₀. Therefore, the iatrogenic complications observed clinically after intravitreal administration of ranibizumab may be due to flaws in the administration procedure. Hence, both in vitro and in vivo assays show that the ranibizumab proved to be safe for the treatment of Age-Related Macular Degeneration, as the determination of IC₁₀ has only been feasible within the concentrations used in the posterior segment of the human eye.

*Corresponding author: Marli Gerenutti,

Copyright ©2017, Marli Gerenutti et al. This is an open access article distributed under the Creative Commons Attribution License, which permits unrestricted use, distribution, and reproduction in any medium, provided the original work is properly cited.

Citation: Marli Gerenutti, Humberto Cenci Guimarães, Natália Mencacci Esteves-Pedro, Patrícia Santos Lopes, Marco Vinicus Chaud, Victor Manuel Cardoso Figueiredo Balcão and Denise Grotto. 2017. "Preclinical studies of ranibizumab for safe use in ophthalmology clinic", *International Journal of Development Research*, 7, (09), 15654-15661.

INTRODUCTION

Age-Related Macular Degeneration (ARMD) is a retinal pathology that leads to the loss of the central vision and evolution to legal blindness, directly damaging the work capacity (Ratner and Nathan, 2006; Guimarães and Gerenutti, 2013). In this retinal pathology that evolves towards neovascularization, there is the impairment of the Bruch membrane in the macular region, justifying the damage of the central vision, leading to hypoxemia and to the increase in the production of vascular endothelium growth factors (VEGF) (Rasmussen et al, 2013; Damico, 2007). The VEGF is responsible for new blood vessels formation in the subretinal space, causing exudation and hemorrhage in the macular

region. The inflammatory reaction induced by scarring causes irreversible lesion in the photoreceptors and functional loss of the retinal tissue. The antiangiogenic therapy can be carried out by means of the inhibition of the vascular endothelium growth factors (VEGF), showing to be one of the most recent techniques used as an attempt to treat occult ARMD, in the active form of the pathology (Iu and Kwok, 2007; Rodrigues et al., 2006). Ranibizumab is a recombinant human monoclonal immunoglobulin G1 (Ig G1), molecular weight of 48 kDa, *k* isotype fragment that inhibits vascular proliferation, that is, neutralizes all the VEGF isoforms. As a fragment of humanised recombinant monoclonal antibody, ranibizumab acts against the human vascular endothelial growth factor A (VEGF-A) [6]. Ranibizumab is a recombinant antibody

comprising a chimeric molecule, and can be divided into two parts: a non-binding human sequence conferring a low antigenicity to the antibody, and a high affinity ligand epitope derived from mice that serves for antigen binding (Van Wijngaarden and Qureshi, 2008; Ferrara *et al.*, 2006; Zhao *et al.*, 2016). It has been approved by the “United States Food and Drug Administration” (FDA) for the treatment of ARMD with intravitreal injection. As a fragment of humanized recombinant monoclonal antibody, Ranibizumab acts against the human vascular endothelial growth factor A (VEGF-A). This drug has a strong binding affinity with the isoforms of VEGF-A (VEGF 110, VEGF 121 and VEGF 165), avoiding, this way, the binding of VEGF-A to its VEGFR-1 and VEGFR-2 receptors. Some factors contribute to the progression of the ARMD neovascular form, considering that the binding of the VEGF-A to its receptors leads to endothelial cells proliferation and to neovascularization, as well as to the vascular emptying. Figure 1 shows a scheme relating the physiopathology of ARMD: (a) normal retina, (b) insoluble deposits in the retinal pigment epithelium, (c) insoluble deposits in the Bruch membrane, (d) photoreceptor death due to hypoxemia, (e) retinian neovascularization. Ranibizumab is used to prevent the progression of this pathology (Bakri *et al.*, 2007; Brown *et al.*, 2008; Kim *et al.*, 2016, Vardarinoset *al.*, 2017).

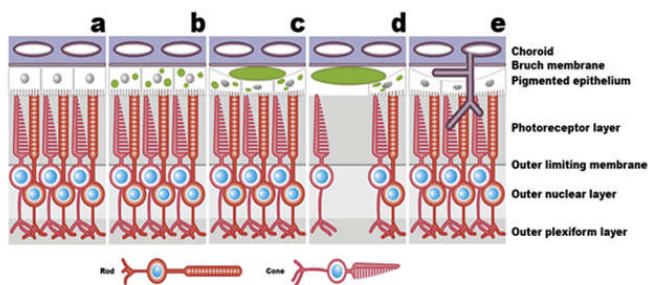


Figure 1. Schematic representation of the physiopathology of ARMD: (a) normal retina, (b) insoluble deposits in the retinal pigment epithelium, (c) insoluble deposits in the Bruch membrane, (d) photoreceptor death due to hypoxemia, (e) retinian neovascularization (Adapted from Ratner and Nathans, 2006)

ARMD treatment protocol is made by intravitreal administration of 0.05 mL of Ranibizumab, in the concentration of 10 mg/mL, that is 0.5 mg per dose. This administration is carried out once a month, during three consecutive months, and then, a new series of three injections can be repeated after an interval of six months, if necessary [8]. It should be noted that hydrophilic drugs such as ranibizumab, injected into the vitreous, are eliminated through the anterior hyaloid and drained by the trabecular bone, and that lipophilic drugs, although displaying a greater retinal tissue penetration and are eliminated via both the retinal choroid and sclera, are also eliminated through the anterior hyaloid and drained by the trabecular bone, considering that the period of action of the drug depends on its half-life and that usually is necessary to carry out several applications (Anderson *et al.*, 2010). In addition to the routes of drug administration described, with their advantages and disadvantages, one must consider the various forms of treatment of ARMD. In this context, currently the primary treatment for ARMD is the anti-angiogenic therapy, which can be made with the use of inhibition of proliferation factors (VEGF) by the intravitreal route of administration. The drugs of choice for the treatment of concealed ARMD are currently sodium pegaptanib (approved

in December 2004 by the FDA for the treatment of ARMD by intravitreal injection), bevacizumab (approved in December 2004 by the FDA for the treatment of colorectal cancer by intravenous infusion and used for the treatment of ARMD by intravitreal injection, even without proper release by regulators), and ranibizumab (approved by FDA in June 2006, for the treatment of ARMD by intravitreal injection) (Rodrigues *et al.*, 2006; Ip *et al.*, 2008). In addition to the aforementioned drugs, corticosteroids such as triamcinolone acetate, anecortave acetate, and squalamine, may also be a choice for the treatment of ARMD (Gaudreault *et al.*, 2005; Gaudreault *et al.*, 2007; Iu and Kwok, 2007; Ho and Kuo, 2007). The penetration of ranibizumab in the retina occurs via the choriocapillaris network, where the initial lesions of ARMD and choroidal neovascularization are located (Guimarães and Gerenutti, 2013). The systemic presence of ranibizumab when injected into the vitreous does not reach 0.01%, being its elimination done either via the choriocapillaris network or via the anterior segment through aqueous humor draining (Kaiser, 2006). Ranibizumab presents a half-life in the vitreous of 2 to 4 days, and can be present in trace amounts after 29 days following intravitreal injection (Bakri *et al.*, 2007; Laude *et al.*, 2010; Tolentino, 2011). The purpose of the research effort entertained herein was to observe the *in vitro* cytotoxicity of Ranibizumab in cell cultures of murine fibroblasts (ATCC CCL-92-P9), and in *in vivo* trials following ranibizumab intravitreal injections in albino rabbits, and thus evaluating its safety for use in humans.

MATERIAL AND METHODS

Biological Materials

13 male albino rabbits from New Zealand (genus *Oryctolagus*, species *cuniculus*, weighing between 1.800 and 2.900 g, and ca. 6 months old) were used in the *in vivo* trials. This study was duly approved by the Ethics Committee on Animal Research of the Federal University of São Paulo / São Paulo Hospital (UNIFESP, São Paulo, Brazil), on the 20th of August 2010, with the authorization number 1436/10. The animals were housed in the bioterium of the Pontifícia Universidade Católica de São Paulo (PUC-SP, campus Sorocaba, Centre for Medical and Health Sciences). Animal handling was performed in accordance with the regulation for use of animals in ophthalmology and studies on vision (Macky, 2003). Murine fibroblasts (ATCC CCL-92-P9 cells, obtained from cells NIH/3T3) (National Institute of Health, 2001) were purchased from the American Type Culture Collection (ATCC), and cultured in the Institute for Energy and Nuclear Research (IPEN) – National Commission of Nuclear Energy (CNEN, São Paulo, Brazil), according to ATCC procedures.

Chemicals

Lucentis® (rhuFabV2, registered trademark by Genentech Inc., whose active principle is ranibizumab with concentration 10 mg/mL, as a solution for injection, in ampoules containing 230 µL solution, lots S0025A, S0025B, S0038, S0041 and S0042) was purchased from Genentech Inc. (San Francisco CA, U.S.A.). Injectable Anasedan® (whose active principle is xilasin, in ampoules with 10 mL) was purchased from Vetbrands (Jacarei, Brazil). Injectable Dopalen® (whose active principle is ketamine hydrochloride, in ampoules with 10 mL) was purchased from Vetbrands (Jacarei, Brazil). Hypnol® (whose active principle is sodium pentobarbital at 30

mg/mL, in ampoules with 50 mL) was purchased from Syntec (Cotia, Brazil). Collyrium Mydriacyl® (whose active principle is tropicamide at 1% (w/v), in flasks with 5 mL) was purchased from Alcon (São Paulo, Brazil). Phenylephrine hydrochloride (10% (w/v) collyrium, in flasks with 5 mL) was purchased from Allergan (São Paulo, Brazil). Anesthetic® collyrium (whose active principle is tetracaine hydrochloride at 1% (w/v) and phenylephrine hydrochloride at 0.1% (w/v), in flasks with 10 mL) was purchased from Allergan (São Paulo, Brazil). Collyrium (generic brand, with 3 mg tobramycin and 1 mg dexamethasone, in flasks with 5 mL) was purchased from Laboratórios Biossintética (Guarulhos, Brazil). Collyrium Ciclolato® (whose active principle is cyclopentolate hydrochloride at 1% (w/v), in flasks with 5 mL) was purchased from Latinofarma (Cotia, Brazil). All other materials utilized were of a pharmaceutical grade. Tap water was purified in a Milli-Q Plus 185 system (Molsheim, France). Murine fibroblast cells (ATCC CCL-92-P9) were purchased from the American Type Culture Collection (Manassas, U.S.A.); DMEM (Dulbecco's Modified Eagle Medium) culture medium, fetal bovine serum, penicillin, streptomycin, L-glutamine and trypsin were from GIBCO (Wisconsin, Madison, U.S.A.); ethylene diamine tetraacetic acid was from Sigma-Aldrich (St. Louis MO, U.S.A.).

Experimental procedures

The biological assays carried out in this research effort aimed at evaluating the safety of ranibizumab for humans, and for this purpose two kinds of biological assays were performed: (i) *in vivo* biological assays, where cellular suffering promoted by ranibizumab was evaluated in normal retinal tissue of albino rabbits subject to intravitreal injection of ranibizumab 10 mg/mL, at volumes of 30 μ L and 50 μ L relative to the control group. This study was conducted through examination of the optic fundus before and after the intravitreal injection for a period of 21 days. Then, histological analysis of the retinal tissue was performed, via staining with the hematoxylin-eosin technique, aiming at analyzing signs of cellular suffering or cell death in the different groups studied; (ii) *in vitro* bioassays, in which the ranibizumab cytotoxicity was assessed in order to determine the IC₅₀ and IC₁₀ in murine fibroblast cells, at ranibizumab concentrations of 70 μ g/mL, 130 μ g/mL, 250 μ g/mL, and 500 μ g/mL, relative to the control. This study was conducted by measuring the amount of formazan produced, making it possible to determine the number of living cells in the culture of CCL-92-P9 cells by UV-VIS spectrophotometry.

In vivo biological assays: Ranibizumab was fractioned in syringes, containing 8 doses of 30 μ L and 8 doses of 50 μ L, using a technique that uses the 21 Gauge needle (BD PrecisionGlide® 21G, 0.80 mm x 25 mm, Becton Dickinson & Co., Franklin Lakes NJ, U.S.A.) and the 29 Gauge needle-syringe (BD Ultra-Fine® 29G, Becton Dickinson & Co., Franklin Lakes NJ, U.S.A.). The method used in this research effort differs from what is recommended by the drug manufacturer, where the aspiration is performed with the 18 Gauge needle (BD® Blunt Fill Needle-Filter, 1,2 mm x 40 mm, Becton Dickinson & Co., Franklin Lakes NJ, U.S.A.) and injection is performed with the 30 Gauge needle (BD Microlance®3, 0,3 mm x 13 mm, Becton Dickinson & Co., Franklin Lakes NJ, U.S.A.) connected to the 1 mL-tuberculin syringe. For aspiration with the technique proposed herein, one used the 21 Gauge needle connected to the 1 mL-syringe that

was itself already connected to the 29 Gauge needle. After aspiration, the 21 Gauge needle is removed and the intravitreal injection is carried out with the 29 Gauge needle. The injection technique proposed in this research effort aims at minimizing the drug loss during application of the intravitreal injection, which is of great significance in view of the high cost of ranibizumab [Ribeiro *et al.*, 2009]. Figure 2 presents the final steps performed in the *in vivo* biological trials, according to previous methodologies (Ribeiro *et al.*, 2009; Ferreira *et al.*, 2002; Hagigit *et al.*, 2012; Manzano *et al.*, 2009; Pezzutti *et al.*, 2001). The mydriasis of the eyes of the animals was achieved via instillation of tropicamide at 1% and phenylephrine hydrochloride at 10%. After mydriasis, the animals were anesthetized using xylazine (1 mg/kg) and ketamine (5 mg/kg) administered by subcutaneous injection and, prior to the intravitreal injection, local anesthesia was performed with instillation of anesthetic collyrium drops. All animals underwent indirect ophthalmoscopy (using an indirect ophthalmoscope from Topcon (model ID-5, Tokyo, Japan) with the aid of +20 diopters lens from Nykon (Tokyo, Japan) which, despite being technically more difficult, provides an inverted panoramic view of the posterior pole of the eye before the intravitreal injection was performed via pars plane at 1 mm posterior to the limbus in the temporal quadrant, with the needle directed towards the center of the eye. In the postoperative, collyrium containing tobramycin (3 mg) and dexamethasone (1 mg) was administered three times a day during one week followed by administration of collyrium containing cyclopentolate hydrochloride (1%) once per day during one week. The groups were randomized, with group I (n = 10 eyes) being injected with 50 μ L of balanced salt solution (BSS), group II (n = 8 eyes) being injected with 30 μ L of ranibizumab, and group III (n = 8 eyes) being injected with 50 μ L of ranibizumab.

All animals were subject to indirect ophthalmoscopy examination immediately after the intravitreal injection, and 1 hour after the procedure, in the 3rd, 7th, 10th, 14th, 17th and in the 21st day after the intravitreal injection. The animals were kept under controlled light cycle, given water and food ad libitum, and were sacrificed by intravenous administration of sodium pentobarbital at a dose of 12.5 mg/kg bolus in the postoperative 21st day of intravitreal injection. The eyes of these animals were enucleated and immersed in Karnovsky's solution (2% paraformaldehyde, 2.5% glutaraldehyde and 0.2 M phosphate buffer at a pH of ca. 7.2) at room temperature for 7 days, for fixation of proteins and inactivation of proteolytic enzymes, thus avoiding the autolysis process. The fixed tissue was washed in running water for half an hour and then subjected to a dehydration process using a series of alcohols: ethanol 80% during 1 hour, 2 times, and absolute ethanol over a period of 1 hour, 3 times. The eyeball of the rabbit underwent subsequently a bleaching process via diaphanization with xylene for 1 hour, and then paraffin-embedded for 5 minutes in an oven set at 56 °C, passing through a new bath for an extra 5 minutes. After this process, the material was placed in the bottom of the mold, which was filled with molten paraffin at 56-58 °C. The block was then allowed to cool down to room temperature and trimmed to allow a better fixation in the microtome. The piece of paraffin, cooled in the refrigerator, was then sliced in the rotating microtome (from American Optical, model 820-Spencer, Buffalo NY, U.S.A.) to a thickness of 5 μ m and placed over the heated albuminized glass slide with the aid of a brush. The slides were then placed in an oven to dry.

The histological slices were dewaxed and hydrated via sequential exposure to xylene for 2 minutes, placed in absolute ethanol for 1 minute, in 95% ethanol for 1 minute, in 70% ethanol for 1 minute, in tap water for 1 minute and in distilled water for 1 minute. For histological analysis, the slices were stained using hematoxylin-eosin (HE) by the regressive method, where the cell nucleus was stained by the Harris hematoxylin and the cytoplasm was stained by eosin. In the analysis of the retina under optical microscopy, at x200 magnification, one observed the layer of rods and cones, the outer nuclear layer, the outer plexiform, the inner nuclear layer, the inner plexiform, the ganglion cells and the nerve fiber layer. The samples were evaluated according to the presence or absence of retinal cell suffering, that is, according to the presence of cell degeneration or necrosis and to the appearance of the nucleus and cytoplasm.

In vitro biological assays

The *in vitro* biological assays were performed according to established methods (Baltrop and Owen, 1991; Promega Corporation, 2011) and reproduced by Giannelli *et al* (2008), Hagigit *et al* (2012) and Hidalgo and Dominguez (2001). The murine fibroblast cells (ATCC CCL-92-P9) were cultured in Dulbecco's Modified Eagle's Medium (DMEM) further supplemented with 10% (w/v) fetal bovine serum, L-glutamine (4 mmol/L), penicillin (100 IU), and streptomycin (100 µg/mL), in plastic flasks for cell culture. The flasks containing the cells were then incubated at 37 °C in an atmosphere with 97% humidity containing 5% CO₂, for a week. After cell confluency in a monolayer, the culture medium was removed and the cells were gently washed with phosphate buffer solution free of both calcium and magnesium (CMF-PBS). For removal of the cells from the culture, one used a solution of 0.25% (w/v) trypsin and 0.02% (w/v) ethylene diamine tetraacetic acid. After trypsinization, the cells were transferred to a conical tube and washed twice with CMF-PBS. This procedure was carried out prior to treatment, according to the cell proliferation protocol (Giannelli *et al.*, 2008).

In order to evaluate the effects of the drug on cell proliferation, the cells were then centrifuged for 5 minutes at 1600 rpm, resuspended in supplemented DMEM medium and adjusted so as to contain 30000 cells/mL. These murine fibroblast cells were then seeded in a 96-well cell culture plate and incubated in a CO₂ incubator (37 °C, with 97% humidity of air, containing 5% CO₂) for 24 hours so as to favor the adhesion of cells. After 24 hours of incubation, six wells were left as a control, and different concentrations of Ranibizumab were added to the cells in the other wells, three wells for each concentration. For every 10.000 cells (ATCC CCL-92-P9) seeded in each well, the following volumes of ranibizumab and medium (proportion ranibizumab (µL) / Medium D10 (µL)) were added: 5/95; 10/90; 50/50; 70/70; 100/100, thus producing the following concentrations in the wells: 2.5 µg/mL, 10 µg/mL, 250 µg/mL, 350 µg/mL and 500 µg/mL. After this procedure, the 96-well cell culture plate was once again incubated for an extra 24 hours. In order to quantify cell proliferation, one has applied the colorimetric method "Cell Titer 96®" (Non-radioactive aqueous test of cell proliferation), which is based on the bioreduction of 3-(4,5-dimethylthiazol-2-yl)-5-(3-carboxymethoxyphenyl)-2-(4-sulfophenyl)-2H-tetrazolium salt (MTS) by dehydrogenase enzymes found in active cells, to a product (formazan) which is soluble in the cell culture medium and strongly absorbs at a wavelength of

490 nm [Baltrop and Owen, 199; Hidalgo and Dominguez, 2001). The extraction buffer was used as a blank. In this way, the absorbance of the formazan produced can be measured directly in the 96-well cell culture plate, by reading in an ELISA spectrophotometer (model SpectraMax 190 ® from Molecular Devices, Sonnyvale, U.S.A.), with no additional process. The amount of formazan measured via absorbance of the solution at 490 nm is directly proportional to the number of viable cells in culture. After 48 hours of contact, the culture medium was aspirated from the wells and aliquots of 120 µL of MTS/PMS (phenazine methosulfate) solution in supplemented DMEM medium were added into all wells of the cell culture plate, which was immediately placed in a controlled atmosphere oven for 2 hours. After this initial period, absorbance measurements were performed at 490 nm in an ELISA plate spectrophotometer attached to a printer, for determination of the number of viable cells in each of the wells relative to the average number of viable cells in the wells left as controls. Determination of the potential of ranibizumab to kill 50 percent of the cells (IC₅₀) or 10 percent of the cells (IC₁₀) was indicative of the LD₅₀ and LD₁₀, respectively.

RESULTS

The results obtained during the *in vivo* biological trials with ranibizumab are displayed in Figure 2, which shows the retinal tissue stained by the Hematoxylin-Eosin technique and the optical microscopy of the retinal histological slice.

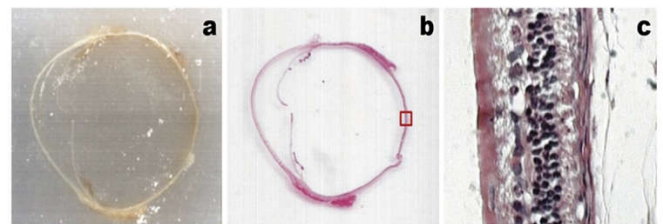


Figure 2. Results obtained during the *in vivo* biological trials with ranibizumab: (a) paraffin block, (b) stained retinal slice via the Hematoxylin-Eosin technique, (c) microphotograph of the optical microcopy of the retinal histological cut (magnification: x200)

Figure 3 shows the histological cut of the albino rabbit's retina, where the choroid layer, the photoreceptor layer, the internal and external nuclear cellular layer and the outer ganglion cell layer, where the presence of either necrosis or cell death was analyzed, according to another study [21].

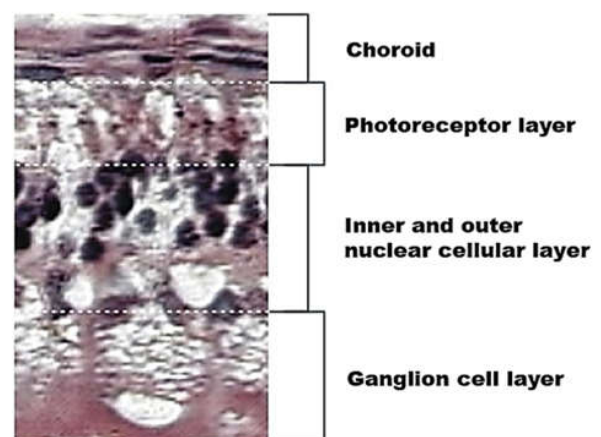


Figure 3. Histological cut of the albino rabbit's retina, stained via the Hematoxylin-Eosin technique, with schematic representation of the retinal layers (magnification: x200)

Figure 4 shows histological slices of retinal tissue of albino rabbits, stained with the consecrated hematoxylin-eosin technique, with a x200 magnification, 21 days after performing intravitreal injection of ranibizumab at 10 mg/mL in volumes of 30 μ L (Figure 4a), 50 μ L (Figure 4b), and 50 μ L of balanced salt solution (Figure 4c). In the analysis of the retina by optical microscopy, one observed the layer of rods and cones, the outer nuclear layer, the outer plexiform layer, the inner nuclear layer, the inner plexiform layer, the ganglion cell layer and the nerve fiber layer.

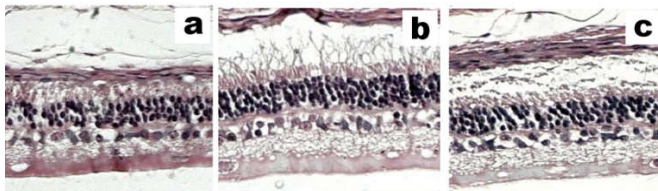


Figure 4. Microphotographs (magnification: x200) of histological slices of retinal tissue of albino rabbits, stained via the hematoxylin-eosin technique, following intravitreal injection of ranibizumab at 10 mg/mL in volumes of 30 μ L (a), 50 μ L (b), and 50 μ L of balanced salt solution (c).

The results of the *in vitro* trials performed with murine fibroblast cells when MTS was employed as a cellular viability indicator are displayed in Table 1.

Table 1. Results obtained (and associated standard deviations) for the average MTS dye absorption at 490 nm and cell viability relative to the control

Parameter	Control	Ranibizumab concentration				
		2.5 μ g/mL	10 μ g/mL	250 μ g/mL	350 μ g/mL	500 μ g/mL
MTS $\pm \sigma$	0.685 \pm 0.023	0.681 \pm 0.014	0.638 \pm 0.005	0.560 \pm 0.020	0.510 \pm 0.018	0.493 \pm 0.012
Cell viability (%) $\pm \sigma$	100 \pm 3.295	99 \pm 2	93 \pm 1	82 \pm 4	74 \pm 3	72 \pm 2

The results indicate that the minimum inhibitory concentration (MIC) to kill 10% of the murine fibroblast cells (MIC 10) has been reached at a ranibizumab concentration up of 10 μ g/mL, while the MIC to kill 50% of the cells (MIC 50) has never been reached, even for ranibizumab concentrations 50 times higher than that needed for MIC 10.

DISCUSSION

The ranibizumab volume of 30 μ L that was utilized in the *in vivo* biological trial was based on the direct proportionality between the vitreal volume of the New Zealand albino rabbit breed (ca. 1.5 mL) and the vitreal volume of humans (ca. 3 times higher). Hence, by injecting intravitreally 30 μ L ranibizumab in the rabbit's eyes, in fact we were injecting a volume 2 times higher than that administered therapeutically in human beings (Laude *et al.*, 2010; Ferreira *et al.*, 2002). The ranibizumab volume at a concentration of 10 mg/mL recommended for intravitreal injection in the treatment of ARMD in humans is 50 μ L, and therefore one decided to use this volume in the *in vivo* trials in albino rabbits thus corresponding to a volume ca. 3 times higher than that used in the treatment of ARMD in humans (Laude *et al.*, 2010; Ferreira *et al.*, 2002). The drug mydriasis administered pre-intravitreal injection, as described by Manzano *et al.* (2009), was effective. The animal sedation procedure (Hagigit *et al.*, 2012) was effective, by using the maximum dosage per kg of both ketamine and xylazine for attaining a satisfactory sedation.

The fundus examination, through retinal mapping in rabbits before and after intravitreal injection, enabled the monitoring of possible complications of this procedure. The use of tobramycin associated with dexamethasone and cyclopentolate hydrochloride (Pezzutti *et al.*, 2001) proved to be effective without any signs of postoperative endophthalmitis. The increase in the volume of the posterior pole of the eye, with a consequent increase of the vitreous pressure on the retinal tissue, causes a reduction of blood flow in the retinal vessels (Kim *et al.*, 2008). This reduction in blood flow justifies the whitish appearance of the retina that was observed in this research effort, which can be classified as mild, moderate or severe.

The presence of whitish retina in the *in vivo* assays was observed only in mild degree in all three animal groups studied and in moderate degree in animal group III, in the period between the indirect ophthalmoscopy immediately after the intravitreal injection and the evaluation performed 1 hour after the procedure. The intravitreal biological half-life of ranibizumab was studied and correlated with its molecular weight (48 kDa), and it was observed that this drug has a half-life of 2.88 days in the animal model using rabbits (Bakri *et al.*, 2007). Moreover it was described that after intravitreal injection of ranibizumab in rabbit eyes, the vitreous becomes clear in about 3 days after the procedure (Gaudreault *et al.*, 2005; Gaudreault *et al.*, 2007).

Considering that the vitreous of the eye and ranibizumab have different densities, when one injects ranibizumab in the posterior pole of the eye there is a change in the density of the vitreous called vitreal condensation. The presence of vitreal condensation was observed in groups I and III immediately following intravitreal injection, in all groups 1 hour after the procedure and only in group III three days after the procedure. The results obtained in this research effort are similar to those previously reported (Oliveira Neto, 2002). Waisbourd and colleagues concluded that ranibizumab quickly distributes into the retina, taking in the process from 6 hr to 24 hr, with its concentration in the retina being ca. one third of that existing in the vitreous humor (Waisbourd *et al.*, 2007).

The retinal tissue exhibited the same histological appearance in the three animal groups studied, demonstrating that there were no signs of cell death or cell suffering whatsoever even doubling or tripling the volume of ranibizumab used in humans. In the experimental results described herein, it is observed that both the increase in volume and an increase in the dose of ranibizumab do not promote histological changes in retinal tissue of albino rabbits. The results gathered by us are in close agreement with those reported by Oliveira Neto *et al.* who found very similar results after performing intravitreal injection of bupivacaine in the eyes of albino rabbits (Oliveira Neto, 2002). The rabbit's vitreous volume is ca. 1.4 mL while the volume of the human vitreous is ca. 3.9 mL. The vitreous clearance is inversely proportional to its volume, meaning that the higher the volume of the vitreous, the lower its clearance.

The clearance from the vitreous of the rabbit is twice as high as the clearance of the human vitreous (Laude *et al*, 2010). In the *in vivo* experimental trials performed in the present research effort, one observed changes in the density of the posterior pole of the eyes of the animals, immediately after the intravitreal injection procedure, after one hour and after three days of having performed the intravitreal injection. Therefore, it can be stated that the vitreous condensation observed in the experimental *in vivo* trials was due to physiological changes of the vitreous and cannot be considered an adverse effect of ranibizumab. The highest ranibizumab concentration tested (500 µg/mL), which is equivalent to the therapeutic dosage, promoted cell death under 30%. The volume of the human vitreous humor varies from 3.9 to 5.0 mL Laude *et al*, 2010. In this way, at each application of 500 µg of ranibizumab, its concentration in the vitreous humor may vary from 100 to 128 µg/mL. Based on that, the 500 µg/mL concentration dose (used in the ranibizumab administration protocol for humans, without considering its dilution in the vitreous humor) in direct contact with the murine fibroblasts, resulted in a cell viability percentage of ca. 72%. When performing the *in vitro* cytotoxicity assay at a concentration of 125 µg/mL of any drug under study, this is equivalent to a total dose of 500 µg in the vitreous volume (Spitzer *et al*, 2007). The concentration of 500 µg/mL (used in the protocol of ranibizumab administration in rabbits, equivalent to 2000 µg/mL, i.e., a dosage four times higher than that used in humans) in direct contact with the murine fibroblast cells, resulted in a percent cell viability of ca. 69.51%. These results clearly indicate that ranibizumab has a very low cytotoxicity, thus reinforcing its safety in the intravitreal administration for the treatment of ARMD, because even after exposing murine fibroblasts to a dose 4 times higher than the current ranibizumab therapeutic dosage only 30.49% of cells underwent cell death.

The choice of cell type, in our case murine fibroblasts, did not affect the outcome of the experiment since in a similar ranibizumab cytotoxicity study via *in vitro* experimental trials using either endothelial cells from the choroid of pigs, human retinal pigment epithelial cells, or rat retinal ganglion cells, cell death was very similar to the control group in all three cases (Spitzer *et al*, 2007). Hence, the results obtained in the present research effort clearly indicate that ranibizumab presents a low cytotoxicity in an *in vitro* model, thus reinforcing its safety when administered (in the recommended dosages) for the treatment of Age-Related Macular Degeneration. Age-related macular degeneration is considered a contemporary pathology, due to the increased life span of the world population, causing a significant reduction in the quality of life due to the loss of vision necessary to carry out basic day-to-day activities. The drug ranibizumab opened up a new perspective in the treatment of patients with Age-related macular degeneration in the active form, preventing its evolution which, in some cases, can be devastating in relation to both the loss of central vision and quality of life of these patients. The use of antiangiogenic therapy in Age-related macular degeneration seems to be (at present) the most effective treatment due to its high specificity, because it acts directly on the imbalance between pro- and antiangiogenic factors. The *in vitro* biological assay performed in the research effort entertained herein lasted three days, making it much faster than the *in vivo* biological assay which lasted about 30 days. The *in vitro* biological assays clearly demonstrated the safety of ranibizumab in contact with murine fibroblast cells, and the *in vivo* biological assays demonstrated the safety of

ranibizumab when applied by intravitreal injection in the eyes of albino rabbits. The results obtained in both the *in vivo* and *in vitro* biological assays described in the present research effort, together, further reinforce that ranibizumab has a low cytotoxicity towards normal retinal tissue of the eyes of albino rabbits, as well as in cell cultures of murine fibroblasts, demonstrating its safety when administered via intravitreal injection for the treatment of age-related macular degeneration. The clinical protocol by using ranibizumab is carried out by intravitreal injection, reaching up to 6 intravitreal injections in the period of 1 year. In the *in vivo* assays performed in this study, there were no adverse effects whatsoever related to mechanical trauma induced by this procedure, thus confirming the safety of ranibizumab when applied by intravitreal injection. However, treatment by intravitreal administration of ranibizumab for age-related macular degeneration has several disadvantages related to the cost/benefit. The approximate cost per ranibizumab application is around USD 1,800.00 up to USD 2,000.00. This treatment, in the course of a year, often comes to be composed of six applications, which in practice can lead to the fractionation of an ampoule by the doctor, to achieve intravitreal administration in more than one patient. The practice of fractionation can thus cause an increased risk of endophthalmitis (Arias *et al*, 2009; Lavinsky *et al*, 2013; Park *et al*, 2013 Damasceno *et al*, 2016).

Conclusions

This study confirms the safety of ranibizumab treatment protocol used to date, and opens up future plans to develop controlled release systems for this drug to be used in such protocols, in order to drastically reduce the required number of intravitreal injections and thus reduce the discomfort and improve both safety and cost/benefit of the treatment in patients with age-related macular degeneration the active form. The molecular therapy using antiangiogenic drugs will only be effective if we can provide medication directly in the target tissue in both the right concentration and during the time required for retinal angiogenesis to be controlled.

Conflict of Interest

All authors have made a substantial contribution to conception of this paper, since acquisition, analysis and interpretation of data until conscripting the article and revising it critically for important intellectual content. Furthermore, all of them approved the final copy of this work and there is not conflict of interest disclosures.

REFERENCES

- Anderson, O.A., Bainbridge, J.W.B., Shima, D.T. 2010. Delivery of anti-angiogenic molecular therapies for retinal disease. *Drug Discov. Today*. 15(7-8):272-282.
- Arias, L., Ruiz-Moreno, J.M., Gómez-Ulla, F., Fernández, M., Montero, J. 2009. A 1-year retrospective review of ranibizumab for naive nonsubfoveal choroidal neovascularization secondary to age-related macular degeneration. *Retina*. 29(10):1444-1449.
- Bakri, S.J., Snyder, M.R., Reid, J.M., Pulido, J.S., Ezzat, M.K., Singh, R.J. 2007. Pharmacokinetics of intravitreal ranibizumab (Lucentis). *Ophthalmology*. 114(12):2179-2182.

- Baltrop, J.A., Owen, T.C. 1991. 5-(3-carboxymethoxyphenyl)-2-(4,5-dimethylthiazolyl)-3-(4-sulphophenyl) tetrazolium, inner salt (MTS) and related analogs of 3-(4,5-dimethylthiazolyl)-2,5-diphenyltetrazolium bromide (MTT) reducing to purple water-soluble formazans as cell-viability indicators. *Bioorg. Med. Chem. Lett.* 1:611-614.
- Brown, M.M., Brown, G.C., Brown, H.C., Peet, J. 2008. A value-based medicine analysis of ranibizumab for the treatment of subfoveal neovascular macular degeneration. *Ophthalmology*. 115(6):1039-1045.
- Damasceno, N.P., Horowitz, S.A., Damasceno, E.F. 2016. Leuconostoc as a cause of endophthalmitis post-intravitreal injection of ranibizumab. *Ocul. Immunol. Inflamm.* 24(1):118-119.
- Damico, F.M. 2007. Angiogenesis and retinal diseases. *Arq. Bras. Oftalmol.* 70:547-553.
- Ferrara, N., Damico, L., Shams, N., Lowman, H., Kim, R. 2006. Development of ranibizumab, an anti-vascular endothelial growth factor antigen binding fragment, as therapy for neovascular age-related macular degeneration. *Retina*. 26(8):859-870.
- Ferreira, M.A., Rigueiro, M.P., Morales, P.H., Ferreira, M.A., Farah, M.E. 2002. Histopathologic study of the retina in rabbits after intravitreal injection of lidocaine. *Arq. Bras. Oftalmol.* 65(1):49-52.
- Gaudreault, J., Fei, D., Beyer, J.C., Ryan, A., Rangell, L., Shiu, V., Damico, L.A. 2007. Pharmacokinetics and retinal distribution of ranibizumab, a humanized antibody fragment directed against VEGF-A, following intravitreal administration in rabbits. *Retina*. 27(9):1260-1266.
- Gaudreault, J., Fei, D., Rusit, J., Suboc, P., Shiu, V. 2005. Preclinical pharmacokinetics of ranibizumab (rhuFabV2) after a single intravitreal administration. *Invest. Ophthalmol. Vis. Sci.* 46(2):726-733.
- Giannelli, M., Chellini, F., Margheri, M., Tonelli, P., Tani, A. 2008. Effect of chlorhexidine digluconate on differential cell types: A molecular and ultrastructural investigation. *Toxicol. in Vitro*. 22(2):308-317.
- Guimarães, H.C., Gerenutti, M. 2013. Therapeutic alternatives to Age-related Macular Degeneration treatments: a challenge for public health. *Journal of Basic and Applied Pharmaceutical Sciences*. 34:459-468.
- Hagigit, T., Abdulrazik, M., Orucov, F., Valamanesh, F., Hagedorn, M., Lambert, G., Behar-Cohen, F., Benita, S. 2012. Topical and intravitreal administration of cationic nanoemulsions to deliver antisense oligonucleotides directed towards VEGF KDR receptors to the eye. *J. Control. Release*. 145(3):297-305.
- Hidalgo, E., Dominguez, C. 2001. Mechanisms underlying chlorhexidine-induced cytotoxicity. *Toxicol. in Vitro* 15(4-5), 271-276.
- Ho, Q.T., Kuo, C.J. 2007. Vascular endothelial growth factor: biology and therapeutic applications. *Int. J. Biochem. Cell Biol.* 39(7-8):1349-1357.
- Ip, M.S., Scott, I.U., Brown, G.C., Brown, M.M., Ho, A.C., Huang, S.S., Recchia, F.M. 2008. Anti-vascular endothelial growth factor pharmacotherapy for age-related macular degeneration. *Ophthalmology*. 115 (10):1837-1846.
- Iu, L.P.L., Kwok, A.K.H. 2007. An update of treatment options for neovascular age-related macular degeneration. *Hong Kong Med. J.* 13(6):460-470.
- Kaiser, P.K. 2006. Antivascular endothelial growth factor agents and their development: therapeutic implications in ocular diseases. *Am. J. Ophthalmol.* 142(4):660-668.
- Kim, J.E., Mantravadi, A.V., Hur, E.Y., Covert, D.J. 2008. Short-term intraocular pressure changes immediately after intravitreal injections of anti-vascular endothelial growth factor agents. *Am. J. Ophthalmol.* 146(6):930-934.
- Kim, L.N., Mehta, H., Barthelmes, D., Nguyen, V., Gillies, M.C. 2016. Metaanalysis of real-world outcomes of intravitreal ranibizumab for the treatment of neovascular age-related macular degeneration. *Retina*. 36(8):1418-1431.
- Laude, A., Tan, L.E., Wilson, C.G., Lascaratos, G., Elashry, M., Aslam, T., Patton, N., Dhillon, B. 2010. Intravitreal therapy for neovascular age-related macular degeneration and inter-individual variation in vitreous pharmacokinetics. *Prog. Retin. Eye Res.* 29(6):466-475.
- Lavinsky, D., Cardillo, J.A., Mandel, Y., Huie, P., Melo, L.A., Farah, M.E., Belfort, R., Palanker, D. 2013. Restoration of retinal morphology and residual scarring after photocoagulation. *Acta Ophthalmol.* 91(4):315-323.
- Macky, T.A., Werner, L., Apple, D.J., Izak, A.M., Pandey, S.K., Trivedi, R.H. 2003. Viscoanesthesia. Part II: toxicity to intraocular structures after phacoemulsification in a rabbit model. *J. Cataract. Refract. Surg.* 29(3):556-562.
- Manzano, R.P., Peyman, G.A., Khan, P., Kivilcim, M., Chevez-Barrios, P., Takahashi, W. 2009. Testing intravitreal toxicity of rapamycin in rabbit eyes. *Arq. Bras. Oftalmol.* 72(1):18-22.
- National Institute of Health. Guidance document on using in vitro data to estimate in vivo starting doses for acute toxicity. NIH Publication 2001 no. 01-4500.
- Oliveira Neto, H.L., Farah, M.E., Smith, R.L., Maruins, M.C. 2002. Retinal toxicity effects of intraocular injection of bupivacaine in rabbits. *Arq. Bras. Oftalmol.* 65(4):451-455.
- Park, Y., Kim, K.S., Park, Y.H. 2013. Acute endophthalmitis after intravitreal injection and preventive effect of preoperative topical antibiotics. *J. Ocul. Pharmacol. Ther.* 29(10):900-905.
- Pezzutti, S., Holzchuh, N., Alves, M.R., Holzchuh, M.P., Holzchuh, R. 2001. Polytetrafluoroethylene and human sclera in surgical treatment of scleral perforation in rabbits. *Arq. Bras. Oftalmol.* 64(6):563-567.
- Promega Corporation. 2011. Technical Bulletin n° 169: CellTiter 96® Aqueous Non-Radioactive Cell Proliferation Assay Technical Bulletin, Part# TB169, Printed in USA, Revised 12/12, p.15
- Rasmussen, A., Bloch, S.B., Fuchs, J., Hansen, L.H., Larsen, M., Lacour, M., Lund-Andersen, H., Sander, B. 2013. A 4-year longitudinal study of 555 patients treated with ranibizumab for neovascular age-related macular degeneration. *Ophthalmology*. 120(12):2630-2636.
- Ratner, A., Nathans, J. 2006. Macular degeneration: recent advances and therapeutic opportunities. *Nat. Rev. Neurosci.* 7(11): 860-872.
- Ribeiro, J.A., Messias, A., Scott, I.U., Jorge, R. 2009. Alternative technique for reducing compound waste during intravitreal injections. *Arq. Bras. Oftalmol.* 72(5):641-644.
- Rodrigues, E.B., Rossi, E.E., Junior, A.G., Meyer, C.H., Ho, A.C. 2006. Treatment of neovascular age-related macular degeneration with antiangiogenic drugs. *Arq. Bras. Oftalmol.* 69:756-765.
- Spitzer, M.S., Yoeruek, E., Sierra, A., Wallenfels-Thilo, B., Schraermeyer, U., Spitzer, B., Bartz-Schmidt, K.U., Szurman, P. 2007. Comparative antiproliferative and cytotoxic profile of bevacizumab (Avastin), pegaptanib (Macugen) and ranibizumab (Lucentis) on different ocular

- cells. *Graefes Arch. Clin. Exp. Ophthalmol.* 245(12):1837-1842.
- Tolentino, M. 2011. Systemic and ocular safety of intravitreal anti-VEGF therapies for ocular neovascular disease. *Surv. Ophthalmol.* 56(2):95-113.
- Van Wijngaarden, P., Qureshi, S.H. 2008. Inhibitors of vascular endothelial growth factor (VEGF) in the management of neovascular age-related macular degeneration: a review of current practice. *Clin. Exp. Optom.* 91(5):427-437.
- Vardarinos, A., Gupta, N., Janjua, R, Iron, A., Empeslidis, T., Tsaousis, K.T. 2017. 24-month clinical outcomes of a treat-and-extend regimen with ranibizumab for wet age-related macular degeneration in a real life setting. *BMC Ophthalmol.* 27;17(1):58.
- Waisbourd, M., Loewenstein, A., Goldstein, M., Leibovitch, I. 2007. Targeting vascular endothelial growth factor: a promising strategy for treating age-related macular degeneration. *Drugs Aging.* 24(8):643-662.
- Zhao, C., Zhang, Z., Chen, L., Wang, F., Xu, D. 2016. Effectiveness of intravitreal injection of ranibizumab for neovascular age-related macular degeneration with serous pigment epithelial detachment. *Med. Sci. Monit.* 14;22:833-839.
